

Case Report

An unusual triad: Bilateral dilated odontoma, hypodontia and peg laterals

Alphy Alphonsa Sebastian¹, Auswaf Ahsan¹, Ahkin John George², John Aby²

¹Departments of Oral Medicine and Radiology, ²Oral and Maxillofacial Surgery, St. Gregorios Dental College, Kothamangalam, Kerala, India

ABSTRACT

The dilated odontoma is an infrequent developmental alteration that appears in any area of the dental arches and can affect deciduous, permanent and supernumerary tooth. Dens invaginatus is a developmental anomaly resulting from invagination of a portion of crown forming within the enamel organ during odontogenesis. The most extreme form of dens invaginatus is known as dilated odontoma.

The aim of this case report is to present a rare case of bilateral dilated odontoma affecting a microdontic permanent lateral incisor in a 30 year old female patient with hypodontia and peglateral teeth with its clinical, radiological and histological features, which has yet been not reported. Bilateral presence of dilated odontoma is not a common occurrence, although a single tooth involvement in each case has been reported in the literature.

Key Words: Dens invaginatus, dilated odontoma, hypodontia, lateral incisors

Received: September 2012
Accepted: April 2013

Address for correspondence:
Dr. Alphy Alphonsa Sebastian,
Department of Oral
Medicine and Radiology,
St. Gregorios Dental College,
Kothamangalam,
Kerala, India.
E-mail: alphyalphonsa1@
yahoo.com

INTRODUCTION

Dens invaginatus also known as dens in dente, or telescopic tooth is a developmental malformation that can occur on primary, permanent or supernumerary tooth.^[1] It is characterized by the inversion or infolding of the enamel and dentin towards the pulp chamber usually appearing as an opening on the surface of crown.

The permanent maxillary lateral incisors are the teeth most frequently involved and in the majority of cases (dens invaginatus) appearing to represent simply an accentuation in the development of the lingual pit.^[2] The most extreme form of this anomaly is referred to as the dilated odontoma.^[3]

CASE REPORT

A 30-year-old female reported to the clinic with chief complaint of swelling and periodic pain in the maxillary right and left anterior region for several years. Medical, dental and family histories were non-contributory.

Extra oral examination of the head and neck region structures was within normal limits and corresponded to normal growth and development for that age.

Intra oral examination revealed maxillary permanent peg laterals on both the sides. The determination of the lateral incisor as a permanent was carried out after careful consideration of history, clinical examination and radiographic appearance. The swelling was localized to the labial aspect of peg lateral region [Figures 1 and 2]. Expansion of the buccal cortical plate without involving the lingual cortical plate was noticed. Affected teeth were not mobile. Overlying mucosa was slightly erythematous, hard and mildly tender on palpation.

Intra oral examination also revealed the congenitally missing 13, 23 and 47 presented with clinically detectable pulpal exposure.

Access this article online



Website: <http://drj.mui.ac.ir>

A panoramic radiograph as well as intra oral periapical radiographs of 12 and 22 were ordered.

Intra oral periapical radiograph in relation to 12 and 22 region revealed microdontic oval shaped lateral incisors. The coronal portion showed a small crown with normal radiopacity and the apical portion showed a dilated root with a central radiolucency surrounded by well-defined radiopacity [Figures 3 and 4].

Panoramic radiograph showed an oval shape radiolucent interior delineated by a well-defined radiopaque band at the periphery in relation to 12 and 22 measuring 2.4 × 2 cm and 3.5 × 2.5 cm in diameter respectively. The nasal floor was elevated in relation to 22 [Figure 5a and b].

The treatment plan included extraction of the peg

laterals along with their root and subsequent prosthetic rehabilitation and the specimen was sent for hard tissue sectioning.

Histopathological examination revealed dentin with dentinal tubules circumscribing immature enamel matrix and pulpal tissue. Disorganized matrix of immature dentin with enamel spaces noted within central area suggestive of dilated odontoma [Figure 6].

Histological assessment revealed a final diagnosis of dilated odontoma. Post-operative healing was uneventful.

DISCUSSION

Dens invaginatus is a deep surface invagination of the crown or root that is lined by enamel. “The first

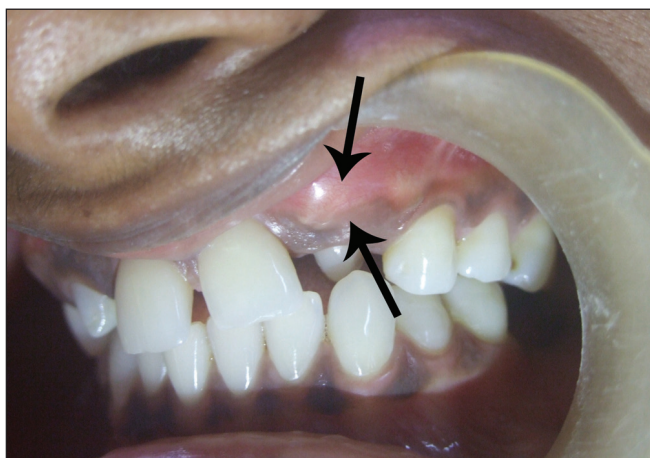


Figure 1: Intraoral swelling on the labial aspect of 22 with diffuse margin, mucosa overlying is tense and erythematous. Crowns of 3 and 21 displaced mesially and labially and 24 displaced distally

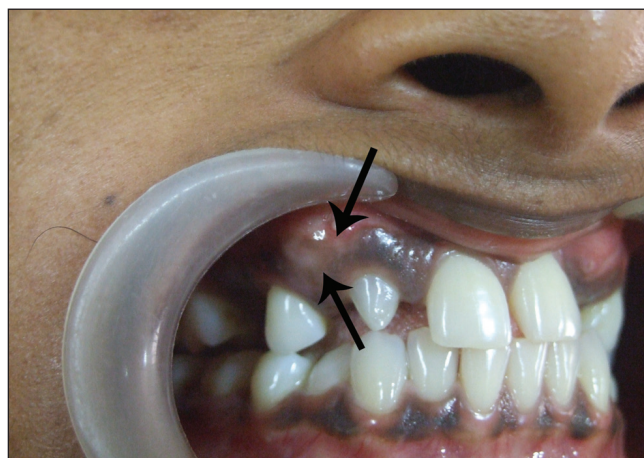


Figure 2: Intraoral swelling on the labial aspect of 12 with diffuse margin. Crowns of 11 displaced mesially and 14 displaced distally

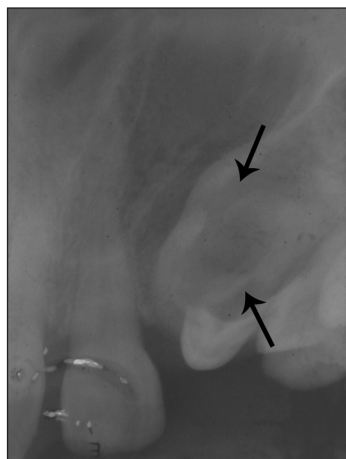


Figure 3: Periapical radiograph showing conical crown with bulbous root in relation to 22

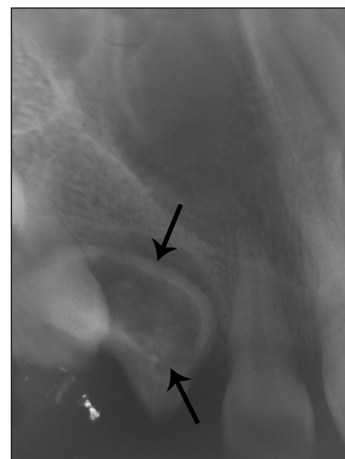

Figure 4: Periapical radiograph showing conical crown with dilated root in relation to 12

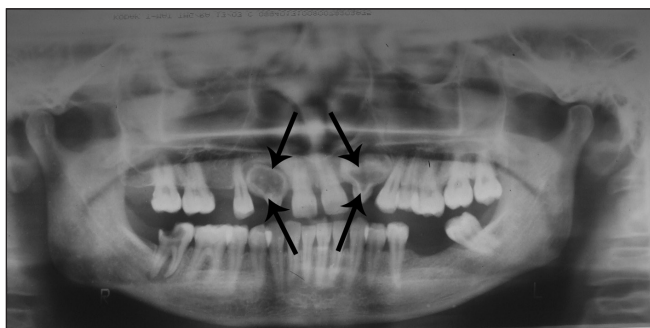


Figure 5a: A panoramic image shows conical crown with dilated roots in relation to 12 and 22, pathologic migration of 11,21,14 and 24, elevation of left nasal floor

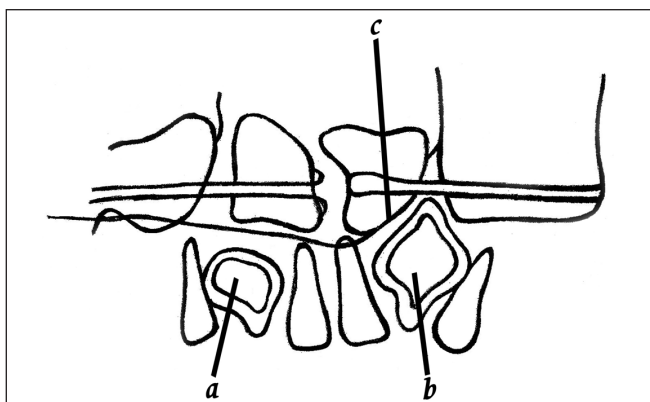


Figure 5b: Sketch diagram of panoramic image shows (a and b) Conical crown with dilated root, (c) Elevation of left nasal floor

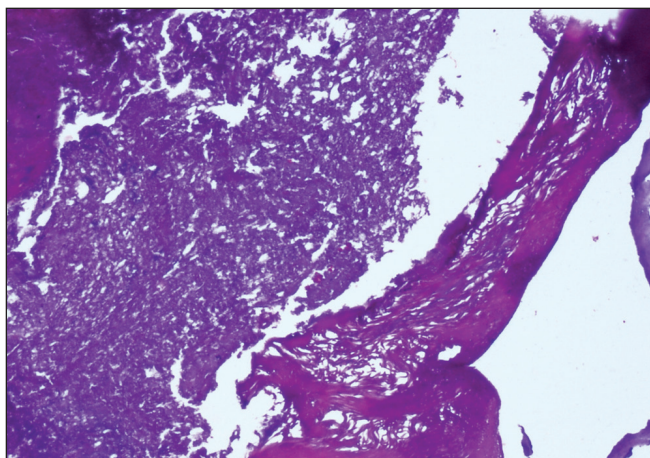


Figure 6: Decalcified section showing disorganized mass of immature dentin with enamel spaces within noticed in the central area; dentin with dentinal tubules circumscribing immature enamel matrix and pulpal tissue

case of dens invaginatus in a human tooth was first described by a dentist named Socrates in 1856.” “Swanson and McCarthy (1947) were the first to present bilateral dens invaginatus malformation.”^[4]

Most of the cases diagnosed are seen associated with permanent teeth. The teeth affected often include lateral incisors, central incisors, premolars, canines, and molars. Invaginations are rare in the crowns of mandibular teeth and in primary teeth.^[5]

The etiology of dens invaginatus malformation is controversial and remains unclear. Several theories have been put forward to explain the etiology of dens invaginatus.

- Growth pressure of dental arch results in buckling of enamel organ (Euler 1939, Atkinson 1943).
- Kronfeld (1934) suggested that the invagination results from a focal failure of growth of internal enamel epithelium while the surrounding normal epithelium continues to proliferate and engulf the static area.
- The “twin-theory” (Bruszt 1950) suggested a fusion of two tooth germs.
- Infection was considered as an etiology by Fischer (1936) and Sprawson (1937).

Most authors, meanwhile consider dens invaginatus as a deep folding of the foramen caecum during tooth development, which in some cases even may result in a second apical foramen.^[6]

Clinically, unusual crown morphology (‘dilated’, ‘peg-shaped’, ‘barrel-shaped’) or a deep foramen caecum may be important hints. However, affected tooth also may show no clinical signs of malformation.

Two forms have been recognized, coronal and radicular.

Coronal dens invaginatus has been classified into three major types by Oehler.^[4,5]

Type 1: The invagination ends as a blind sac and is confined to the crown.

Type 2: The invagination extends apically beyond the external cemento-enamel junction ending as a blind sac, but not reaching the periapical tissues.

Type 3: The invagination extends beyond the Cemento-enamel and a second apical foramen communicates with the periodontal ligament or periapical tissues.

When dens in dente involve root-radicular dens invaginatus, it appears to be the result of an invagination of Hertwig’s epithelial root sheath. This results in an accentuation of the normal longitudinal root groove.

Radiographically, the infolding of enamel lining is more radiopaque than the surrounding tooth structure and can be easily identified.^[5] The radiographic invagination may vary in size and shape, form a loop such as pear shaped or slightly radiolucent structure to a severe form resembling a “tooth within a tooth”. In the most severe form — dilated odontoma, the tooth is severely deformed, having a circular or oval shape with radiolucent interior.

Histologically, the coronal invagination is lined by enamel, whereas radicular invagination is lined by cementum. Before eruption the lumen of invagination is filled with a soft tissue similar to the dental follicle. On eruption, this soft tissue loses its vascular supply and becomes necrotic.

Sometimes the invagination may be dilated and disturb the formation of tooth, resulting in anomalous tooth development termed dilated odontoma.

In conclusion, a comprehensive multidisciplinary approach should be the treatment of choice with these types of cases of apparently unique and infrequent pathology. Extraction of teeth along with pathological tissues should be performed immediately to avoid delaying histological diagnosis, which could render subsequent treatment plan effectively.

ACKNOWLEDGMENTS

We acknowledge Dr. Ria L Mathew and Dr. Reshmi for their invaluable help to prepare this manuscript.

REFERENCES

1. Sedano HO, Ocampo-Acosta F, Naranjo-Corona RI, Torres-Arellano ME. Multiple dens invaginatus, mulberry molar and conical teeth. Case report and genetic considerations. *Med Oral Patol Oral Cir Bucal* 2009;14:E69-72.
2. Rajendran R. Disturbances of Oral & Para oral structures. *Shafers Textbook of Oral Pathology*. 5th ed. Noida: Elsevier; 2006. p. 57-8.
3. White SC, Pharoah MJ. Dental anomalies. *Oral Radiology: Principles & interpretation*. 5th ed. St Louis Missouri: Elsevier; 2008. p. 340-1.
4. Hülsmann M. Dens invaginatus: Aetiology, classification, prevalence, diagnosis, and treatment considerations. *Int Endod J* 1997;30:79-90.
5. Mupparapu M, Singer SR. A review of dens invaginatus (dens in dente) in permanent and primary teeth: Report of a case in a microdontic maxillary lateral incisor. *Quintessence Int* 2006;37:125-9.
6. Zengin AZ, Sumer AP, Celenk P. Double dens invaginatus: Report of three cases. *Eur J Dent* 2009;3:67-70.

How to cite this article: Sebastian AA, Ahsan A, George AJ, Aby J. An unusual triad: Bilateral dilated odontoma, hypodontia and peg laterals. *Dent Res J* 2013;10:674-7.

Source of Support: Nil. **Conflict of Interest:** None declared.