

Original Article

Correlation between symphyseal morphology and mandibular growth

Mahkameh Moshfeghi¹, Mahtab Nouri², Sanam Mirbeigi³, Alireza Akbar Zadeh Baghban⁴

¹Department of Oral and Maxillofacial, ²Department of Orthodontics, Dental School, Shahid-Beheshti University of Medical Sciences, Tehran, ³Department of Oral and Maxillofacial, Dental School, Yazd University of Medical Sciences, Yazd, ⁴Department of Basic Sciences, Rehabilitation School, Shahid-Beheshti University of Medical Sciences, Tehran, Iran

ABSTRACT

Background: This study sought to assess symphyseal morphology in adolescents with different mandibular growth patterns (MGPs) in order to see if a relation exists.

Materials and Methods: In this study the symphyseal parameters (height, depth, and ratio) of normal subjects were compared with four groups with malocclusion (cl III vertical, cl II vertical, cl III horizontal, and cl II horizontal). These groups (15 samples each) were matched (for sex and cervical maturation stage [CVMS]) based on their cephalograms and patient charts. Growth patterns were differentiated by seven vertical parameters and the Wylie analysis. After confirmation of normality of the groups and similarity of their variances the two-way analysis of variance (ANOVA) was used for analysis of data assessed by adjusted chi-square ($P < 0.001$). The comparison of cases with the normal group was performed by the Dunnett method. Intraclass Correlation Coefficient (ICC) was used for evaluation of intraobserver reliability.

Results: We found the symphyseal ratio to have a significant correlation with the MGP ($P < 0.001$). The symphyseal ratio (Height/Depth) was small in a mandible with vertical growth pattern CI II or CI III. Conversely, a horizontal growth pattern of a CI II or CI III mandible was associated with a larger ratio of the symphysis in comparison with the normal group. The symphyseal ratio was also found to be greater in females.

Conclusion: The symphyseal ratio was found to be strongly associated with the MGP.

Key Words: Horizontal, mandibular growth, symphysis, vertical

Received: December 2012
Accepted: July 2013

Address for correspondence:
Dr. Sanam Mirbeigi,
Department of Oral and
Maxillofacial, Dental School,
Yazd University of Medical
Sciences, Dental School,
Daheye Fajr Boulevard,
Yazd, Iran.
E-mail: drsmirbeigi@
gmail.com

INTRODUCTION

Prediction of mandibular growth pattern (MGP) plays an important role in orthodontic treatment planning; it is critical when managing the development of dentofacial structures.^[1-7] Different methods have been introduced for predicting MGP and assessing, symphyseal morphology is one of them.^[1-12] Ricketts and others stated that morphology of the symphysis may be used to predict the direction of mandibular

growth. He associated a thick symphysis with an anterior growth direction.^[9] Bjork^[6] described multiple structural configurations in extreme types of mandibular rotators. He found that forward inclination of the condylar head was associated with forward mandibular rotation, along with a greater curvature of the mandibular canal compared with mandibular contour. A tendency toward backward mandibular rotation was associated with a pronounced apposition below the symphysis with more overall concavity of the inferior mandibular border. Proclination of the symphysis is an indicator of a backward rotating mandible. Jarabak's cephalometric analysis predicted the direction of mandibular growth by a facial polygon, including the saddle angle (N-S-Ar), articular angle (S-Ar-Go), and gonial angle (Ar-Go-Me); a sum of these three angles greater than 396 is predictive of a posterior MGP while a sum less than 396 was associated with

Access this article online



Website: <http://drj.mui.ac.ir>

anterior MGP. Also a ratio of posterior (S-Go) to anterior face height (N-Me) of 56-62% indicated a posterior MGP, whereas a ratio of 65-80% indicated an anterior growth tendency.^[13] Although many cephalometric measurements have been introduced, it is still very difficult to accurately predict the direction of mandibular growth.^[1-12,14,15] Lee *et al.*^[16] studied the reliability of the Skieller's prediction method. Although, Skieller's four variables accounted for 86% of the variability of changes in the direction of mandibular growth (mandibular inclination, intermolar angle, shape of the inferior border of the mandible, and inclination of the symphysis); however, it accounted for only 8% in Lee's study. Thus, he concluded that predicting the direction of mandibular growth is very perplexing and problematic. Aki *et al.*^[10] assessed symphyseal height, depth ratio (H/D) and angle. In his study, the morphology of the symphysis was found to be associated with the direction of mandibular growth. A mandible with an anterior growth direction was associated with a small height, large depth, small ratio, and large angle of the symphysis. Conversely, a posterior growth direction was associated with a large height, small depth, large ratio, and small angle of the symphysis. The purpose of this study was to evaluate symphyseal morphology (Height, Depth, and Height/Depth) in patients aged between 9 and 14 years with different sagittal and vertical MGPs.

MATERIALS AND METHODS

Lateral cephalometric radiographs and charts of adolescents aged between 9 and 14 years were used in this study. The first part of the study was conducted on 60 normal cephalograms taken from normal individuals according to normal occlusion defined by Moyer's^[17] and appropriate facial proportions were approved by two orthodontists. The samples had no history of orthodontic treatment or history of systemic or developmental diseases.

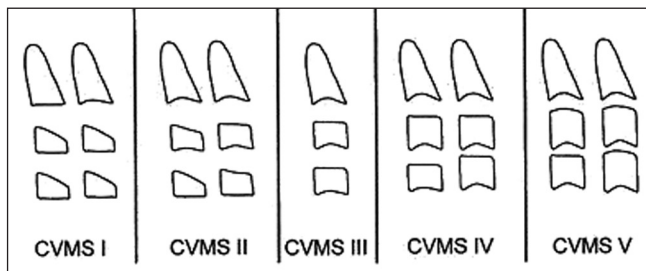


Figure 1: Baccetti's method for evaluation of the cervical maturation stage

To find normal value for vertical growth pattern of mandible vertical indices, that is, the sum of Bjork angles, Gonial angle and SN-Man angle were used. Wylie's analysis was also used for assessing sagittal growth pattern of mandible, which included mandibular length and lower mandibular length.^[18] The second part of the study was to define case groups, which included CI II vertical, CI III vertical, CI II horizontal, and CI III horizontal patients with normal maxillae.

Samples were selected from the patients referred to the Orthodontic or Pediatric Departments.

Patients within the mean range (± 2 SD) were defined as normal. The four case groups were those who were out of this range classified as horizontal or vertical growing patterns according to vertical indices^[10] and as CI II or CI III skeletal growing patterns according to Wylie indices.^[18]

There were 15 samples in each group that were matched to normal groups according to sex and cervical maturation stage (CVMS). Baccetti's method was used for CVMS determination^[19,20][Figure 1].

The symphyseal measurement included height, depth, and ratio (H/D) measured according to the Aki *et al.* study.^[10]

Linear measurements used the tangent drawn at point B and parallel and perpendicular lines drawn to this tangent. The method of measuring height and depth of the symphysis^[10] is shown in Figure 2.

All radiographs were taken with the same panoramic radiographic device (PLANMECA Proline x, Helsinki, Finland). All of them were scanned and digitized

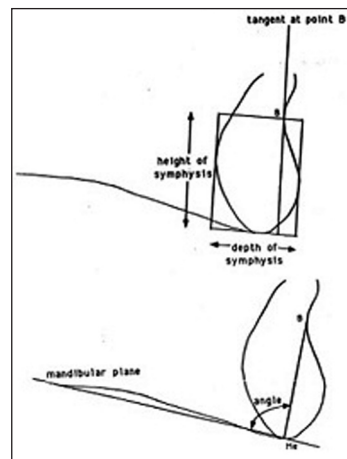


Figure 2: Cephalometric measurements used to quantify symphysis morphology

(dpi 300), and the measurements were made using Dolphin imaging software, version 10 (Patterson Dental Supply, USA)

For symphyseal parameters, real size tracings were printed by Dolphin Imaging software and measured using a grid.

Statistical analysis

Normal data distribution was evaluated by one sample k-s test and the Levene test was performed to indicate variance equality between groups. After confirmation of normality of the groups and equation of their variances, the two-way analysis of variance (ANOVA) model was assessed by adjusted chi-square for analysis of data ($P < 0.001$), and the comparison of cases with the normal group was performed using the Dunnett method. For evaluation of intraobserver reliability, Intraclass Correlation Coefficient (ICC) was assessed and the reliability was approved (ICC coefficient was between 0.0726 and 0.0871).

RESULTS

Evaluation of CVMS

Evaluation of 60 normal radiographs with the Baccetti method showed that 21 were in stage III, 29 were in stage II, and the remaining were in stage I. The case groups also were selected from the patients in stage III and matched to 15 samples with normal radiographs, which were in the same stage. Each group consisted of seven female and eight male patients.

Evaluation of sagittal and vertical analysis

Mean and standard deviation of the sagittal and vertical parameters are shown in Table 1.

Comparison between subgroups

Table 2 lists the height and depth of the symphysis based on sex and growth pattern in study groups. Comparison of each case group with normal group showed only statistically significant differences between the normal group and CI II horizontal and CI III vertical groups in height ($P < 0.001$). There was no significant difference relevant to sex.

Comparison of each case group with the normal group showed only statistically significant difference between it and the CI III horizontal and CI II vertical groups in depth ($P < 0.001$) and no significant difference relevant to sex.

Table 3 shows the symphysis ratio relevant to sex and growth pattern. The female patients had significantly greater H/D compared with male patients. All four case groups had statistically significant differences compared with the normal group.

The intraobserver reliability was assessed by ICC of reliability.

Table 1: Mean and standard deviation of mandibular parameters of sagittal and vertical analysis

Parameters	Mean	SD
Vertical		
SN-Mandibular plane angle	33.91	1.83
Sum of Bjork	395.08	2.46
Sagittal		
Gonial angle	126.79	1.75
Inferior border of mandible	65.12	1.49
Mandibular length	101.83	1.83

Table 2: Mean and standard deviation of symphyseal height and depth in the normal group and four subgroups based on gender

Groups	Mean depth	SD	Mean height	SD
Male				
Normal	14.81	1.03	20.37	1.48
CI II vertical	11.81	0.92	21.37	1.43
CI II horizontal	13.93	1.14	16.25	1.46
CI III vertical	13.68	0.7	23.31	1.9
CI III horizontal	17.06	0.56	19.5	0.8
Female				
Normal	13.78	0.75	20.21	1.18
CI II vertical	11.42	0.62	20.28	0.99
CI II horizontal	14.5	1.32	17.78	1.46
CI III vertical	13.64	0.47	24.28	0.56
CI III horizontal	17.35	0.85	20.92	1.17

Table 3: Mean and standard deviation of symphyseal ratio in the normal group and four subgroups based on gender

Groups	Mean H/D	SD
Male		
Normal	1.38	.032
CI II vertical	1.72	.013
CI II horizontal	1.16	.018
CI III vertical	1.7	.021
CI III horizontal	1.14	.014
Female		
Normal	1.46	.013
CI II vertical	1.77	.029
CI II horizontal	1.22	.021
CI III vertical	1.77	.026
CI III horizontal	1.2	.021

DISCUSSION

Different approaches have been used for prediction of MGPs.^[1-12,21,22] Quantification of skeletal data has been shown to be an effective and reliable method of demonstrating variation in human growth as well as for monitoring and interpreting the growth of various skeletal elements in the living.^[23] Morphological changes in the mandibular body had been studied in previous researches, and it was found that the gonial angle became significantly smaller after the third molar eruption. Also, the posterior mandibular body length had a linear correlation with Gonial angle.^[24]

One of the recent methods introduced by Aki *et al.*^[10] is symphysis morphology. Due to ease in selection of landmarks for evaluating symphysis morphology in cephalograms, we used his measurements to evaluate their variation in four different MGPs. The characteristics of the normal subjects were mentioned in other studies.^[25,26]

Despite wide variations in the size and shape of the human face, head, and body, there is remarkable consistency for quantifiable gender-specific facial traits.^[27] In one study, significant relationships were found between the measures of mandibular incisor crowding and basal bone dimensions in female subjects. Except for the vestibular part of cancellous bone thickness, all mandibular incisor bone measurements were greater in the male subjects than in the female subjects.^[28]

We matched our study groups according to the Baccetti's skeletal age, in order to lower the developmental age effect on the mandibular growth. The samples were also matched based on gender. In this way, the confounding effect of gender and skeletal age was minimized on mandibular growth.

It was also found that there was a sexual dimorphism on the morphology of the symphysis, with the mean symphyseal ratio being higher in the female samples than in the male samples. This difference has been indicated in all studies on mandibular growth, because bone deposition in the pogonion region is an x-linked trait.^[10]

Symphyseal morphology differed significantly between normal subjects and the study subgroups. It was noticed that with horizontal growth patterns of the mandible whether in CI II or CI III, the symphyseal ratio was higher than in the normal group. In cases with vertical growth patterns either CI II or CI III,

the ratio was lower. The depth increased from vertical growth to horizontal growth in the mandible.

Not all of the symphyseal measurements were significantly different between subgroups. The height of the symphysis was greatest in CI III vertical and the least in CIII horizontal groups, with no significant difference in other subgroups. Regarding the depth of the symphysis, the greatest depth was measured in CI III horizontal and the least was indicated in the CI II vertical group.

The size and shape of the mandibular symphysis is an important consideration in evaluation of orthodontic patients.^[6,10,29,30] With a prominent symphysis, more protrusion of the incisors is esthetically acceptable and therefore a greater chance that a nonextraction approach to treatment may be considered. Conversely, in patients with greater symphyseal height and small chin, an extraction approach is preferred for compensation of arch length discrepancies.^[16,31] This concept was confirmed by the results of our study because we measured the deepest depth in horizontal growth patterns; therefore, we can use nonextraction approach in these individuals. Furthermore in vertical growth patterns it is better to extract teeth because of the decreased symphyseal depth.

Aki *et al.*^[10] did a study to determine whether symphysis morphology could be used as a predictor of the direction of mandibular growth and to assess growth changes of the symphysis. They determined the direction of mandibular growth based on vertical parameters and divided it into anterior and posterior growth patterns. Consequently, they subdivided the size of the symphysis into large, small, and medium. Symphysis morphology was found to be associated with the direction of mandibular growth, especially in male subjects with symphysis ratio having the strongest relationship in adults. A mandible with an anterior growth direction was associated with a small height, large depth, small ratio, and large angle of the symphysis. Conversely, a posterior growth direction was associated with a large height, small depth, large ratio, and small angle of the symphysis. Symphyseal dimensions continued to change until adulthood with male subjects having a greater and later change compared with female subjects. Their findings were in accordance to our study. In addition, the ratio was low in horizontal growth (anterior growth direction) and the depth was greater. It seems that based on both studies, the symphysis morphology is different in various vertical growth patterns of the mandible.

CONCLUSION

In summary, we can conclude that female adolescents had greater symphyseal ratio in comparison to male adolescents. Also, symphyseal depth differed significantly in vertical and horizontal growth patterns in comparison to normal groups and symphysis ratio (Height/Depth) was strongly related to the vertical pattern of mandibular growth in both genders.

REFERENCES

- Huggare J. The first cervical vertebra as an indicator of mandibular growth. *Eur J Orthod* 1993;11:10-6.
- Solow B, Siersback-Nielsen S. Cervical and craniocervical posture as predictors of craniofacial growth. *Am J Orthod Dentofacial Orthop* 1992;101:449-58.
- Rossouw PE, Lombard CJ, Harris AM. The frontal sinus and mandibular growth prediction. *Am J Orthod Dentofacial Orthop* 1991;100:542-6.
- Lundstrom A, Woodside DG. A comparison of various facial and occlusal characteristics in mature individuals with vertical and horizontal growth direction expressed at the chin. *Eur J Orthod* 1981;3:227-35.
- Chen F, Terada K, Saito I. Longitudinal intermaxillary relationships in CI III malocclusions with low and high mandibular plane angles. *Angle Orthod* 2007;77:397-403.
- Bjork A. Prediction of mandibular rotation. *Am J Orthod* 1969;55:585-99.
- Zhang M, Zhao Q, Chen YX. Dimensional differences in craniofacial morphologies of prepubescence CI II patients with deep and shallow mandibular antegonial notching. *Hua Xi Kouing Yi Xue Za Zhi* 2006;24:142-5.
- Kolodziej RP, Southard TE, Southard KA, Casco JS, Jakobsen JR. Evaluation of antegonial notch depth for growth prediction. *Am J Orthod Dentofacial Orthop* 2002;121:357-63.
- Ricketts RM. Cephalometric synthesis. *Am J Orthod* 1965;35:36-50.
- Aki T, Nanda RS, Currier GF, Nanda SK. Assessment of symphysis morphology as a predictor of the direction of mandibular growth. *Am J Orthod Dentofacial Orthop* 1994;106:60-9.
- Tanaka R, Suzuki H, Maeda H, Kobayashi K. Relationship between and inclination of mandibular plane and a morphology of symphysis. *Nippon Kyosei Shika Gakkai Zasshi* 1989;48:20-7.
- Bushong PH, Julian K, Sachdeva R, Demirjian A. Childhood and pubertal growth changes of the human symphysis. *Angle Orthod* 1992;62:203-10.
- Jaraback JR, Fizzell JA. Technique and treatment with light-wire edge wise appliance. Vol. 1. CV. Mosby: StLouis; 1972. p. 128-58.
- Ochoa BK, Nanda RS. Comparison of maxillary an mandibular growth. *Am J Orthod Dentofacial Orthop* 2004;125:148-59.
- Eroz UB, Ceylan I, Aydemir S. An investigation of mandibular morphology in subjects with different vertical facial growth patterns. *Aust Orthod J* 2000;16:16-22.
- Lee RS, Daniell FJ, Swartz M, Baumrind S, Korn EL. Assessment of a method for the prediction of mandibular rotation. *Am J Orthod Dentofacial Orthop* 1987;91:395-40.
- Moyers RE. *Handbook of Orthodontics* c. 1st ed. Chap 6. Chicago: London Yearbook Medical Publisher; 1988. p. 114-21.
- Wendell L, Wylie D. The assessment of anteroposterior dysplasia. *Angle Orthod* 1947;17:97-109.
- Baccetti T, Franchi L, Macnrmara JA. The cervical vertebral maturation (CVM) method for the assessment of optimal treatment timing in dentofacial orthopedics. *Sem Orthod* 2005;11:119-29.
- Franchi L, Baccetti T. Transverse maxillary deficiency in CI II and CI III malocclusions: A cephalometric and morphologic study on postero-anterior films. *Orthod Craniofac Res* 2005;8:21-8.
- Liu YP, Behrents RG, Buschang PH. Mandibular growth, remodeling and maturation during infancy and early childhood. *Angle Orthod* 2010;80:97-105.
- Leslie LR, Southard TE, Southard KA, Casco JS, Jakobsen JR, Tolley EA, *et al.* Prediction of mandibular growth rotation: Assessment of Skieller, Bjork and Linde-hansen method. *Am J Orthod Dentofacial Orthop* 2005;114:659-67.
- Hutchinson EF, L'Abbé EN, Oettlé AC. An assessment of early mandibular growth. *Forensic Sci Int* 2012;217:233e1-6.
- Ogawa T, Osato S. Growth changes of the mandibular body with eruption of mandibular third molars: Analysis of anatomical morphometry and quantitative bone mineral content by using radiography. *Ann Anat* 2013;195:143-50.
- Nouri M, Saffar Pour M, Azimi S. Longitudinal cephalometric study of mandible growth in Qazvin children with normal occlusion. *J Qazvin Univ Med Sci* 2006;10:9-16.
- Nouri M, Mokhtari M, Jabouri M, Einollahi AR, Hassani N. Longitudinal cephalometric growth of 9-11 years normal occlusion Iranian children. *J Qazvin Univ Med Sci* 2003;27:65-77.
- Glowacki J, Christoph K. Gender Differences in the Growing, Abnormal, and Aging Jaw. *Dent Clin North Am* 2013;57:263-80.
- Uysal T, Yagci A, Ozer T, Veli I, Ozturk A. Mandibular anterior bony support and incisor crowding: Is there a relationship? *Am J Orthod Dentofacial Orthop* 2012;142:645-53.
- Forster CM, Sunga E, Chung CH. Relationship between dental arch width and vertical facial morphology in untreated adults. *Eur J Orthod* 2008;10:323-9.
- Wagner DM, Chung CH. Transverse growth of the maxilla and mandible in untreated girls with low, moderate and high MP-SN angles: A longitudinal study. *Am J Orthod Dentofacial Orthop* 2005;28:76-23.
- Gaukroger MJ, Noar JH, Sanders R, Semb G. A cephalometric inter-center comparison of growth in children with cleft lip and palate. *J Orthod* 2002;29:113-7.

How to cite this article: We will update details while making issue online***

Source of Support: Author would like to thank orthodontics department of shaheed behashti dental school for their kind cooperation. **Conflict of Interest:** None declared.