

Case Report

Pleomorphic adenoma of submandibular gland: A case report with review of literature

Preeti Patil¹, Krishna Burde², Venkatesh G. Naikmasur², Amit Thorawat²

¹Departments of Oral Medicine and Radiology, Shri Hasanamba Dental College, Hassan, ²Shri Dharmasthala Manjunatheshwara College of Dental Sciences, Dharwad, Karnataka, India

ABSTRACT

Neoplasms that arise in the salivary glands are relatively rare, yet they represent a wide variety of both benign and malignant histologic subtypes. Approximately 70% of the salivary gland tumors affect parotid gland with the submandibular gland being affected in 5-10% of the cases, sublingual gland in 1% and minor glands in 5-15% of the cases. Submandibular gland tumors are relatively rare and very few studies have been reported in the literature that is exclusively conducted on tumors affecting submandibular gland. In this paper, we describe a case of pleomorphic adenoma affecting submandibular gland with brief review of current literature on submandibular gland tumors.

Key Words: Pleomorphic adenoma, salivary gland tumors, submandibular gland

Received: December 2012
Accepted: June 2013

Address for correspondence:
Dr. Preeti Patil, Department
of Oral medicine and
radiology Shri Hasanamba
Dental College, Hassan-
573201, Karnataka, India
E-mail: prtipatil.4@gmail.com

INTRODUCTION

Salivary gland tumors are uncommon and comprise only 1-4% of head-face-neck tumors. Majority of the salivary gland tumors affect parotid gland with more than 70% of the cases.^[1] Several studies have been conducted on the tumors of the parotid and minor salivary glands, but very few reports in the literature have focused on submandibular gland tumors as they are rare and are usually grouped with other salivary glands. Submandibular gland is affected in 5-10% of the cases with pleomorphic adenoma (PA) being the most common tumor.^[1] This paper describes a case of PA involving submandibular gland and reviews benign tumors especially PA affecting submandibular gland.

CASE REPORT

A 42-year-old male patient reported to us with an 8 months history of swelling in the left submandibular region. The swelling was insidious in onset, slow growing and painless. Past medical history and personal history were not contributory.

Extraoral examination revealed diffuse swelling in the left submandibular region measuring approximately 7 cm × 5 cm in size and oval in shape [Figure 1]. On palpation the swelling was firm, non-tender and mobile with well-defined borders. Intraoral examination revealed no reduced salivation from left Wharton's duct. A provisional diagnosis of tumor of left submandibular gland was given based on history and examination findings. Patient was advised computerized tomography (CT) scan to know the extent of the lesion.

Coronal and axial CT sections revealed well-defined heterogeneous mass involving the left submandibular gland with areas of calcification [Figures 2 and 3]. The mass was measuring 7.2 cm × 5.5 cm and caused pressure effects on the adjacent structures. 3D reconstructed image revealed presence of mass in the left submandibular region [Figure 4].

Access this article online



Website: <http://drj.mui.ac.ir>

Aspiration revealed features of PA. Patient underwent complete excision of left submandibular gland [Figure 5] and the excised mass was sent for histopathology. Histopathologic sections revealed darkly stained tumor

cells lying in chondromyxoid mesenchyme [Figure 6]. Final diagnosis of PA of submandibular gland was given. Patient was followed-up for a period of 1 year during which there was no recurrence of the tumor.

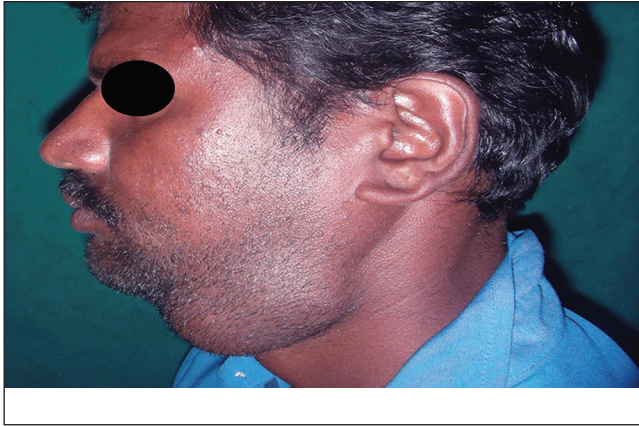


Figure 1: Facial profile showing swelling in the left submandibular region

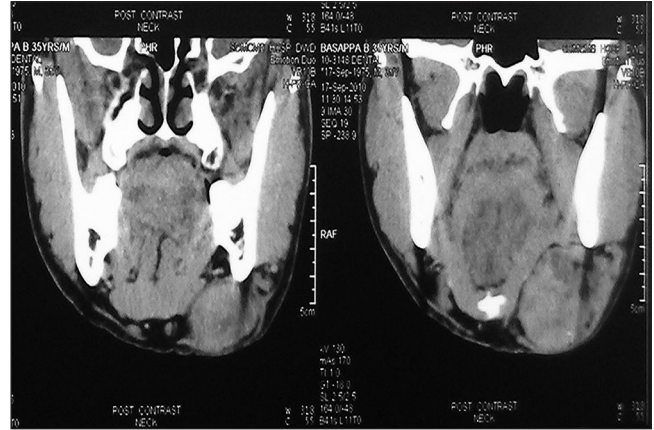


Figure 2: Coronal computed tomography sections showing well defined heterogeneous mass involving left submandibular gland

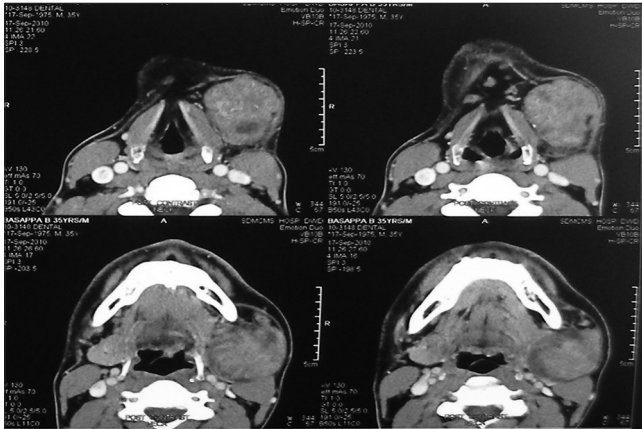


Figure 3: Axial computed tomography sections showing well defined heterogeneous mass involving left submandibular gland

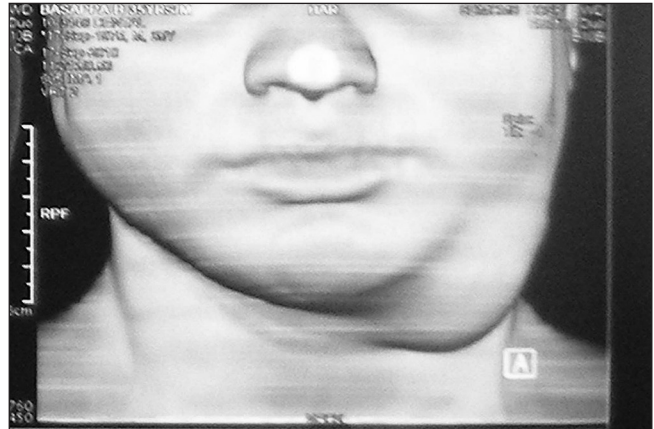


Figure 4: 3D reconstructed image showing mass in the left submandibular region

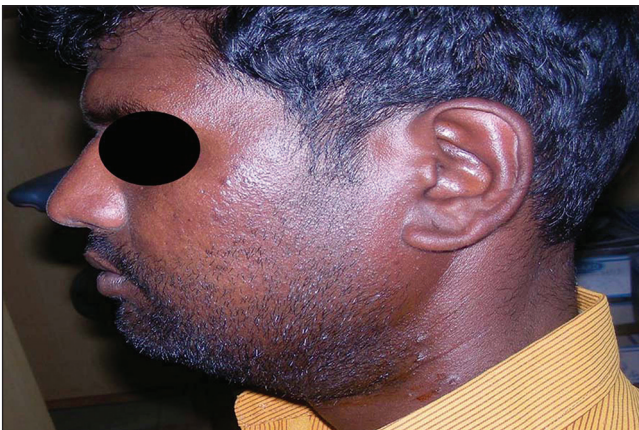

Figure 5: Post-operative picture after excision of the tumor along with the gland

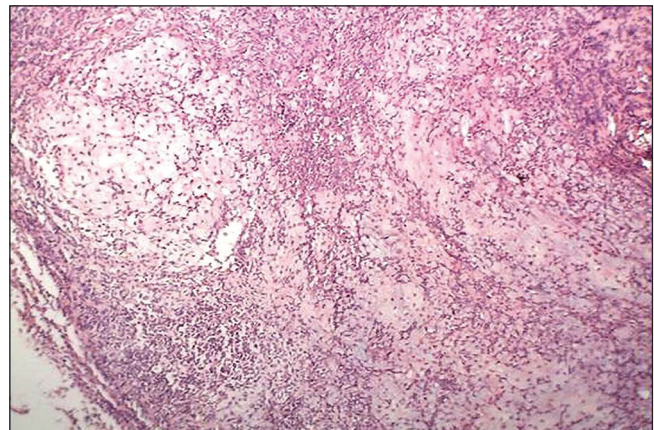


Figure 6: Photomicrograph (H and E, x10) showing darkly stained tumor cells in a predominantly mesenchymal background

DISCUSSION

Salivary gland tumors comprise only 1-4% of head and neck tumors and most commonly affect parotid gland. Very few reports in the literature have focused on submandibular gland neoplasms as they are rare and are usually grouped with other salivary glands. The most frequent neoplasms in the submandibular glands are: PA (36%), adenoid cystic carcinoma (25%), mucoepidermoid carcinoma (12%) and malignant mixed tumor (10%). Clinical reports indicate that benign neoplasms are characterized by a painless enlargement of the submandibular triangle.^[2]

Becerril-Ramírez *et al.* in their 10 year study found a total of 22 cases of submandibular gland neoplasms, in which 19 cases (86%) were benign and 3 cases (14%) were malignant. The most common benign neoplasm was PA which accounted for 18 out of 19 cases. The mean age of occurrence of PA was 39.8 years with female to male ratio of 3.5:1.^[3]

Munir and Bradley reviewed series of the pleomorphic adenoma affecting submandibular gland over a period of 16 years from 1988 to 2004. A total of 32 cases of submandibular gland PA were treated between the period among which 22 out of 32 (69%) cases were female and the mean age of occurrence of PA was 54 years. All patients presented with clinically visible and palpable mass of submandibular fossa among which 84% of cases were asymptomatic and 16% presented with pain.^[4]

Rapidis *et al.* analyzed clinicopathologic features of 23 patients with submandibular gland tumors, in which nine were benign and 14 were malignant tumors. They found that PA was the most frequent benign tumor and manifest a mild course of disease.^[5]

Adeyemo *et al.* reviewed submandibular salivary gland tumors over a 17 years period from 1990 to 2006. A total of 36 patients with submandibular gland tumors were reviewed among which 17 cases were benign and 19 cases were malignant. PA (36.1%) was the most frequent tumor, followed by adenoid cystic carcinoma (11.1%), anaplastic carcinoma (11.1%) and malignant lymphoma (11.1%). Progressive painless swelling (80.6%) was the most common mode of presentation and cases which presented with painful mass (11.1%) and ulceration (8.3%) were malignant.^[6]

In a Brazilian population, de Oliveira *et al.* found that the salivary gland tumors affect females more

often, with a male: female ratio of 1:1.5. This ratio is reported as 1:1.6 in benign tumors and 1:1.5 in malignant tumors. The mean age for benign tumors was 43 years and for malignant tumors was 55 years.^[7]

Alves *et al.* reviewed clinicopathological and immunohistochemical features of 60 cases of PA in Brazil and found that PA occurred commonly between 3rd and 5th decades of life and 37/60 (62%) of them were women. Tumor sizes varied from 1 to 10 cm. Only one patient experienced local recurrence, 3 years after treatment.^[8]

Fine needle aspiration findings provide evidence for a pre-operative diagnosis that is 70-80% accurate and also helps to differentiate between tumor and inflammatory conditions or enlarged lymph nodes. The final pathologic diagnosis is always established based on findings from surgical excision. The treatment of choice for submandibular gland PA is total submandibular gland excision along with tumor.^[9] Recurrence rate of submandibular gland tumors are less than parotid gland since entire gland is excised. Injury to the marginal mandibular nerve is the most common complication leading to temporary or permanent paralysis due to the stretching or compression of the nerve. Temporary paralysis may resolve spontaneously within a period of 3 months.^[10]

CONCLUSION

Although there are few studies that have been conducted exclusively on submandibular gland, the clinical findings in the present case are in agreement with findings of the existing studies with PA being most common benign tumor affecting submandibular gland, occurring commonly between the 3rd and 5th decade of life and presenting as slow growing asymptomatic swelling. However, in the present case, PA affected a male patient although it is most common in females. Further studies exclusively involving submandibular gland have to be carried out to know the nature of tumors affecting it.

REFERENCES

1. Spiro RH. Salivary neoplasms: Overview of a 35-year experience with 2,807 patients. *Head Neck Surg* 1986;8:177-84.
2. Hanna E, Lee S, Fan C, Suen J. Benign neoplasms of the salivary glands. In: Cummings C, Flint P, Harker L, Haughey B, Richardson M, Robbins T, *et al.*, editors. Cummings

- Otolaryngology Head & Neck Surgery. Philadelphia: Mosby; 2005. p. 1348-77.
3. Becerril-Ramírez PB, Bravo-Escobar GA, Prado-Calleros HM, Castillo-Ventura BB, Pombo-Nava A. Histology of submandibular gland tumours, 10 years' experience. *Acta Otorrinolaringol Esp* 2011;62:432-5.
 4. Munir N, Bradley PJ. Pleomorphic adenoma of the submandibular gland: An evolving change in practice following review of a personal case series. *Eur Arch Otorhinolaryngol* 2007;264:1447-52.
 5. Rapis AD, Stavrianos S, Lagogiannis G, Faratzis G. Tumors of the submandibular gland: Clinicopathologic analysis of 23 patients. *J Oral Maxillofac Surg* 2004;62:1203-8.
 6. Adeyemo WL, Ajayi OF, Anunobi CC, Ogunlewe MO, Ladeinde AL, Omitola OG, *et al.* Tumours of the submandibular salivary gland: A clinicopathologic review of cases over a 17-year period. *West Indian Med J* 2009;58:388-91.
 7. de Oliveira FA, Duarte EC, Taveira CT, Máximo AA, de Aquino EC, Alencar Rde C, *et al.* Salivary gland tumor: A review of 599 cases in a Brazilian population. *Head Neck Pathol* 2009;3:271-5.
 8. Alves FA, Perez DE, Almeida OP, Lopes MA, Kowalski LP. Pleomorphic adenoma of the submandibular gland: Clinicopathological and immunohistochemical features of 60 cases in Brazil. *Arch Otolaryngol Head Neck Surg* 2002;128:1400-3.
 9. Eveson JW, Cawson RA. Salivary gland tumours. A review of 2410 cases with particular reference to histological types, site, age and sex distribution. *J Pathol* 1985;146:51-8.
 10. Hong KH, Yang YS. Surgical results of the intraoral removal of the submandibular gland. *Otolaryngol Head Neck Surg* 2008;139:530-4.

How to cite this article: We will update details while making issue online***

Source of Support: Nil. **Conflict of Interest:** None declared.