

Case Report

Restoring the smile: Inexpensive biologic restorations

Neeti P. Mittal¹

¹Department of Pedodontics and Preventive Dentistry, Santosh Dental College and Hospital, Ghaziabad, Uttar Pradesh, India

Received: January 2013

Accepted: June 2013

Address for correspondence:

Dr. Neeti P Mittal,
Department of Pedodontics
and Preventive Dentistry,
Santosh Dental College and
Hospital, No. 1, Santosh
Nagar, Ghaziabad - 201 009,
Uttar Pradesh, India.
E-mail: dr.neetipgi
@gmail.com

ABSTRACT

Extensive breakdown of primary teeth to the cervical level and their loss in very young children is not uncommon. Owing to increasing concerns over self-appearance, due considerations to esthetic aspects in addition to restoring function are necessary aspects of rehabilitation of mutilated teeth to help children grow into a psychologically balanced personality. The present article describes rehabilitation of grossly decayed teeth with biologic restorations such as dentine posts, dentine post and core and biologic shell crown. This treatment modality provided a cost-effective esthetic solution.

Key Words: Biologic restorations, dentine posts, esthetics, primary dentition

INTRODUCTION

Despite the prodigious developments in the field of preventive dentistry and world-wide decline in dental caries prevalence, a good section of young population presents to the pediatric dentist with grossly decayed dentition. This challenges the pediatric dentist with a task of not only restoring the function and esthetics, but also the self-esteem of the young children to prevent the present as well as future unpleasant psychological consequences. Gone are the days when desire to look good used to be the privilege of the adults only, even the preschool children these days are demanding finer looking restorations. From here arose the need to look for various techniques, which give due consideration to esthetic component while not compromising the functional aspects such as composite restorations with celluloid strip crowns,^[1] indirect resin composite crowns,^[2] stainless steel crowns with composite facing/veneering.^[3] All these techniques impose a considerable cost burden on patients. A search for cheaper alternatives while

not compromising on esthetic aspect has led to the introduction of biologic restorations (parts of natural extracted teeth). The present article deals with three such cases managed by use of biologic restorations.

CASE REPORTS

Case 1: Dentine posts

A 4½-year-old boy, conscious of his appearance, presented to our clinic with the chief complaint of poor facial appearance due to discolored and decayed front teeth. On examination, the child was found to have multiple carious lesions with root pieces of the 51, 52, 61, 62, and 54. In addition, multiple carious lesions were seen in 53, 55, 64, 65, 74, 75, 84, and 85. After further radiographic examination, treatment was planned. It consisted of complete preventive care, composite restorations for 53, 65; pulpectomy in 51, 52, 61, 62 and molars (55, 64, 74, 75, 84, and 85) followed-by stainless steel crowns. A band and loop space maintainer was cemented after extraction of root pieces of 54.

Clinically, the roots of maxillary incisors were found to be firm, with an extension of the remaining crown approximately ≤ 1 mm above the gingival margin [Figure 1]. An intraoral periapical radiograph of these teeth showed intact roots and the normal development of underlying permanent successors. Considering the esthetic demands of child and parent, the rehabilitation of maxillary incisors was carried out as described below:

Access this article online



Website: <http://drj.mui.ac.ir>

Step 1: Pulpectomy of 51, 52, 61 and 62 was performed. Carious tooth structure was removed from 51, 52, 61, and 62 using round diamond bur. While removing carious tooth structure, access into the pulp chamber was gained simultaneously as caries had reached pulp. Working length was established radiographically. Canal preparation was carried out using H-files and maximum file size used was 30 and while canal preparation, pulp was removed simultaneously. Profuse irrigation was performed using normal saline. After canal preparation, canals were dried and obturation was done with calcium hydroxide (ApexCal®, Ivoclar Vivadent AG, Liechtenstein). Coronal seal was established with glass ionomer cement (GIC) (GC Fuji II, Glass Ionomer Restorative, GC, USA).

Step 2: Preparation of dentine post: Premolar teeth extracted for orthodontic treatment were selected from department's tooth bank. The root part was used for making posts. Dentine of approximately 5-6 mm length was cut and shaped to conform to premeasured buccolingual and mesiodistal dimensions of cervical part of root canals of 51, 52, 61, 62 [Figure 2]. Vertical grooves were placed in the post to ensure adequate retention.

The shaped dentine posts were autoclaved at 121°C at 15 lbs pressure for 15 min.^[4]

Step 3: Removal of approximately 3 mm of coronal GIC to prepare post-space.

Step 4: Trial fit of all dentin posts and reshaping if necessary.

Step 5: Etching of prepared dentine posts and root canal walls with 35% phosphoric acid (Scotchbond™ Etchant, 3M™/ESPE™ Dental Products, USA) for 15 s. After thorough washing to ensure removal of etching solution, gentle air drying was carried out to have a frosted enamel surface.

Scotchbond™ multipurpose plus (3M™/ESPE™ Dental Products, USA) was applied over the surface of root canal and on dentine posts and curing was done using EzeeCure® LED (Light Emitting Diode) light (Unicorn Denmart™, India) with 1200 mw/cm² power held at a distance of 1-2 mm from tooth following manufacturer's instructions. Any gap between dentine posts and root canal walls was filled by Filtek™ supreme plus flowable restorative resin (3M™/ESPE™ Dental Products, USA) [Figure 3].

Step 6: After trimming the gingival margins of preselected celluloid strip crowns (3M™/ESPE™

Dental Products, USA) trial fit was performed [Figure 4] and adjustments were done if needed. A hole was made on palatal aspect of strip crowns to allow escape of excess composite.

Step 7: Filtek™ Z350 XT supreme universal restorative (3M™/ESPE™ Dental Products, USA) composite material was condensed in celluloid strip crowns with due care being given not to entrap any air bubble. It was seated on incisor to be restored and extra composite material was removed from gingival margins and palatal hole before curing. Curing was

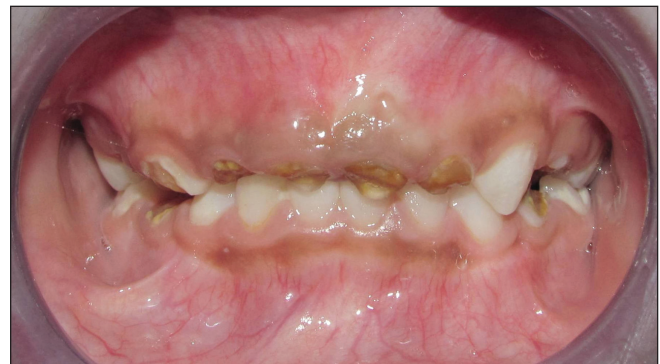

Figure 1: Pre-operative view showing decayed maxillary incisors

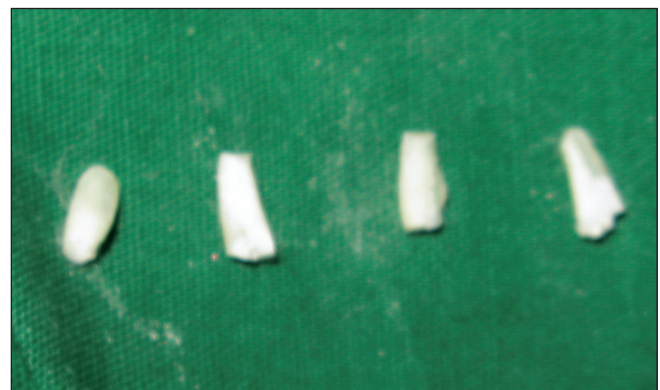

Figure 2: Prepared dentine posts. Note almost cylindrical shape of posts

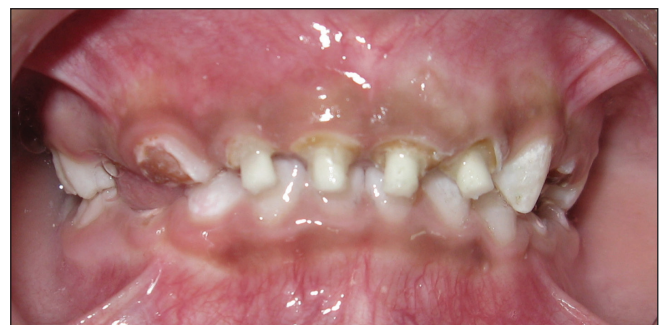

Figure 3: Dentine posts cemented in place

done using EzeeCure® LED light with 1200 Mw/cm² power following manufacturer's instructions.

Step 8: Celluloid strip crowns were removed and final finishing and polishing of margins was carried out using composite finishing and polishing tips (CompoSite™ Finishing Kit, CompoSite™ Polishing Kit, Shofu, USA).

Clinical examination at 1, 6, and 12 months showed these restorations to be functioning well with satisfied child and parent [Figures 5 and 6].

Case 2: Dentine post and core

A 4-year-old girl child reported to our clinic with the chief complaint of discolored and decayed teeth. Clinical and radiographic examination revealed roots of 51, 52, 61, 62, 71, 72, 73, 81, 82, 83 and carious 54, 55, 64, 65, 74, 75, 84, and 85. Along with management of carious teeth, complete preventive care was given to patient.

All retained roots and 84 were extracted. Pulpectomy was performed (as described for the previous case) in 74 and 75 followed by stainless steel crown in 74 and composite restoration in 75. Prosthetic rehabilitation consisted of removable partial denture. Reconstruction of grossly decayed 73 and 83 was performed in the following steps:

Step 1: Pulpectomy of 73 and 83 was performed as described for the previous case and coronal seal was established with GIC (GC Fuji II, Glass Ionomer Restorative, GC, USA) [Figure 7].

Step 2: Preparation of dentine post and core: These were prepared and sterilized in a similar way as described for the previous case. The only difference was in shape. For this case, the dentine part was trimmed so that it had approximately 2-3 mm length of post and similar length of core with wider buccolingual and mesiodistal dimensions when compared with post part [Figure 7].

Step 3: Removal of approximately 3 mm of coronal GIC to prepare post space.

Step 4: Trial fit of prepared post and core unit. The mesiodistal and buccolingual dimensions of core were adjusted so that they allowed thickness of approximately $\geq 1-2$ mm of composite material during final restoration.

Step 5: Cementation of post and core unit was done in a similar way as described for the previous case [Figures 8 and 9].

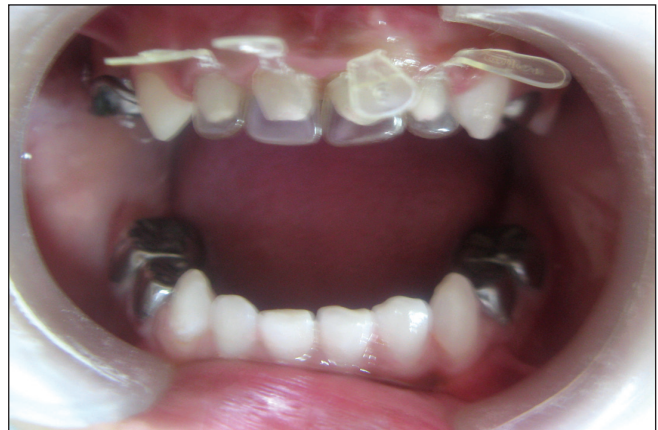

Figure 4: Trial fit of strip crowns

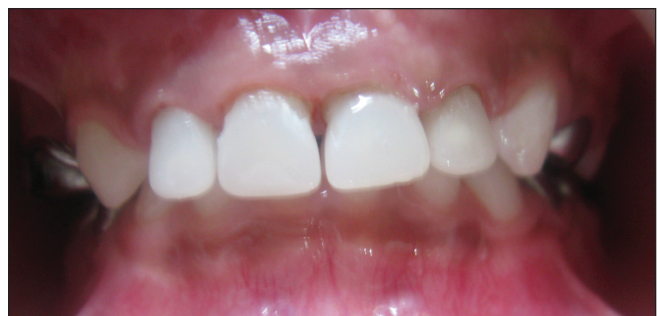

Figure 5: Post-operative view of restored maxillary incisors

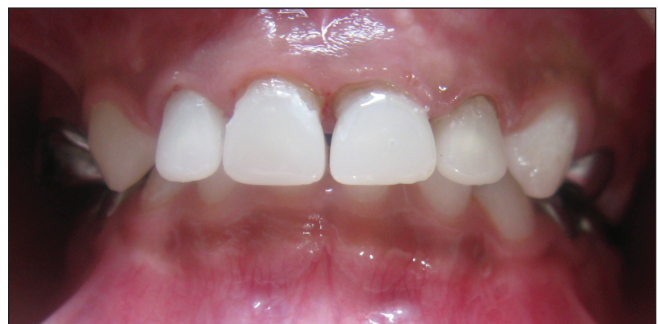

Figure 6: Post-operative view at 12 months follow-up

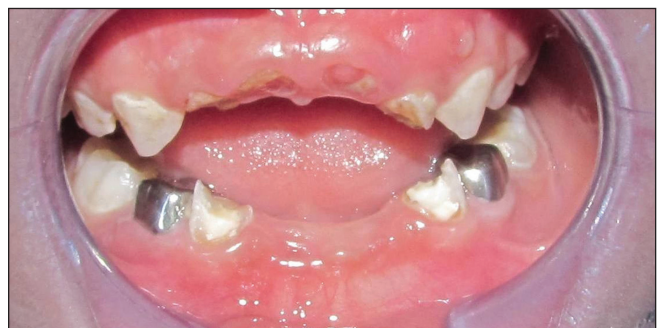

Figure 7: Intra-oral photograph showing 73 and 83 after endodontic intervention. Note the minimal amount of remaining tooth structure

Step 6: Etching was done with 35% phosphoric acid (Scotchbond™ Etchant, 3M™/ESPE™ Dental Products, USA) for 15 s. Scotch bond multipurpose plus (3M™/ESPE™ Dental Products, USA) was applied following manufacturer's instruction.

Step 7: Final buildup was done with Filtek™ Z350 XT supreme universal restorative (3M™/ESPE™ Dental Products, USA) composite material using incremental technique. Polishing and finishing was performed with composite finishing and polishing tips (CompoSite™ Finishing Kit, CompoSite™ Polishing Kit, Shofu, USA). Occlusion was checked in centric and eccentric positions.

Clinical examination [Figure 10] at 1, 6 and 12 months showed these restorations to be functioning well with satisfied patient and parent.

Case 3: Biologic shell crown

A 7-year-old boy reported to our clinic with the chief complaint of decayed teeth. Clinical and radiographic examination revealed multiple carious lesions in all teeth with retained roots of 61, 62. Complete preventive care was provided, retained roots were extracted and all carious teeth were restored. Primary mandibular first molar (84) was grossly carious [Figure 11] and a decision to place biologic shell crown was made.

The operative procedure is described below:

Step 1: Biologic shell crown preparation: Primary mandibular right first molar (possibly extracted for serial extraction) was selected based on mesiodistal dimensions of the tooth to be restored. The selected tooth was sectioned approximately 1 mm occlusal to cemento-enamel junction. Any remaining pulp tissue was removed using sharp spoon excavator. All undercuts were removed and dentinal surfaces were prepared to diverge cervically. The cervical margin was prepared flat with rounded internal line angles so that it can be seated on prepared margin of primary mandibular first molar. Sterilization was performed as described previously.

Step 2: Complete caries excavation was performed under local anesthesia with area isolated using rubber dam. After caries removal, a layer of GIC (GC Fuji II, Glass Ionomer Restorative, GC, USA) was placed. Circumferential shoulder margin with rounded internal line angles was placed using round end tapered diamond parallel to long axis of tooth [Figure 12]. Withdrawal form was established by

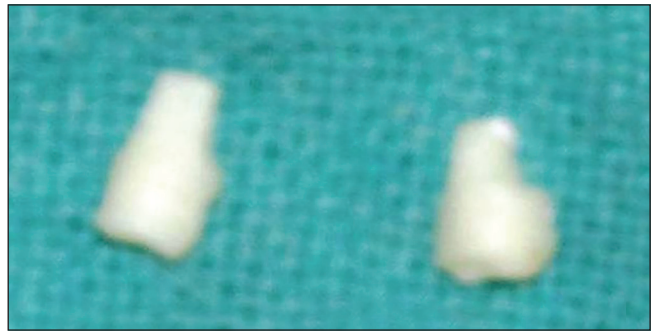


Figure 8: Prepared dentine post and core units. Note that cervical part is narrower when compared to coronal part

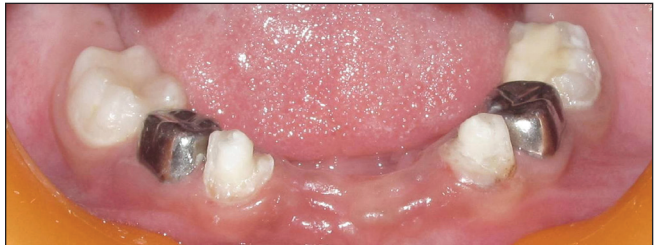

Figure 9: Dentine post and core units cemented in place. Appreciate the amount of tooth structure replaced with these post and core units, which needed application of minimal thickness of composite during final buildup

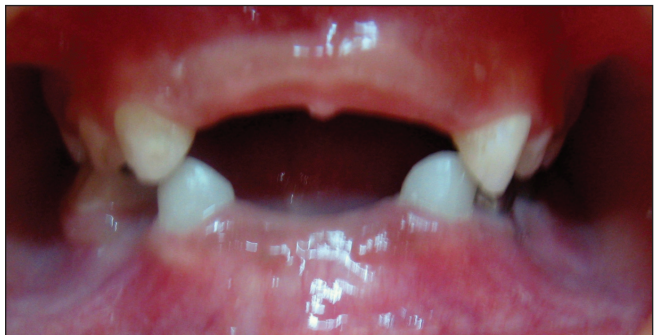

Figure 10: Post-operative view

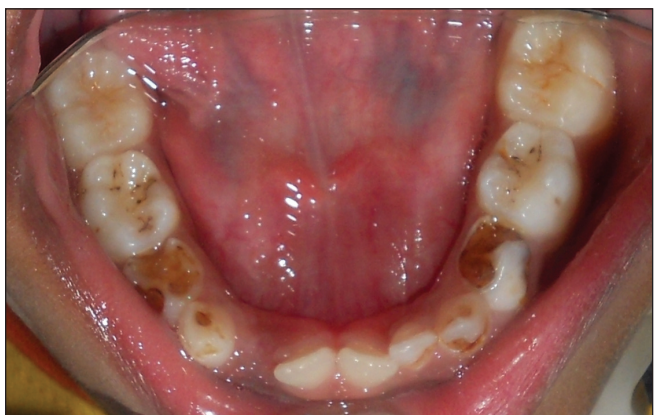

Figure 11: Pre-operative view of mandibular arch showing decayed 84

rounding of all line and point angles and removing all undercuts.

Step 3: Rubber dam was removed and occlusal clearance was checked using modeling wax sheet.

Step 4: Trial fit of biologic shell crown was done and adjustments were done if needed [Figure 13].

Step 5: Etching of dentinal surfaces of prepared biologic shell crown and prepared tooth surfaces was done with 35% phosphoric acid (3M™/ESPE™ Dental Products, USA) for 15 s. Final cementation was performed using dual cure resin cement (RelyX™ U100 Self-Adhesive Resin Cement, 3M™/ESPE™ Dental Products, USA) following manufacturer's instructions.

Step 6: Final check for occlusion in centric as well as eccentric positions to check for any functional interferences. Thin carbon paper was used and pre-maturities, if any were removed.

Step 7: Finishing and polishing of margins was done with composite finishing and polishing tips (CompoSite™ Finishing Kit, CompoSite™ Polishing Kit, Shofu, USA).

Clinical examination [Figure 14] at 1, 6, and 9 months showed the cemented biologic crown to be functioning well in the oral cavity.

DISCUSSION

Although a phenomenal decline in prevalence of dental caries has been reported in past years, there exists a section of the population among which dental caries poses a significant burden of treatment needs.^[5,6] Furthermore, prevalence of dental caries is still higher in developing countries where World Health Organization goals have yet not been achieved.^[7] Thus, pediatric dentists should expect to face a good number of young patients with grossly broken down anterior and posterior teeth.

The management of totally broken down primary teeth is carried out in two phases; core build up followed by restoration of the crown anatomy. A multitude of methods has been used for intra-canal reinforcement for anterior teeth such as composite posts,^[1] short wire posts (omega loop),^[8] Ni-Cr coil spring posts,^[2] readymade glass fiber posts,^[9] ribbond^[10] and dentinal posts.^[11] The crown anatomy can be restored by direct composite build up by incremental method,^[8]

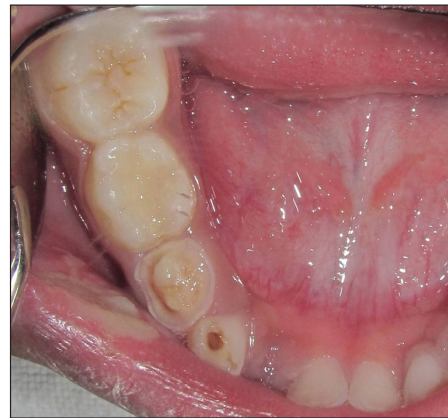

Figure 12: Final tooth preparation and pulp protection with glass ionomer cement

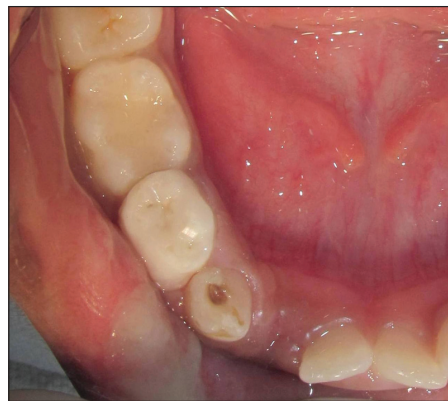

Figure 13: Trial fit of biologic shell crown. Note the occlusal disharmony at distal marginal ridge at this stage. Significant trimming was done, mainly at cervical margin, to ensure proper seating. Also, note the improper mesial contour, which needed minor adjustments

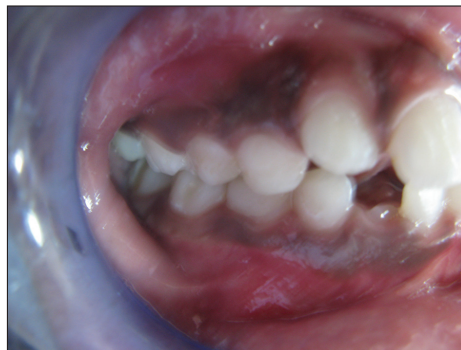

Figure 14: Final post-operative view showing teeth in occlusion

composite build up using celluloid strip crowns,^[1,9] composite build up by indirect technique,^[2,10] open faced stainless steel crowns,^[3] resin veneered stainless steel crowns,^[12] enamel veneers and biological shell crowns.^[9,13]

In the first two case reports presented in this article, dentine post and dentine post with core were used. The tensile bond strength of the intra-canal posts such as short composite posts, glass fiber posts, omega wire posts, ribbond, posts with macroretentions and primary root dentine has not been found to differ significantly.^[14] Hence, the prime factors to be borne in mind while selecting the appropriate intra-canal posts are biocompatibility, ease of applicability and availability with the requirement for lesser chairside time. Dentine post/post with core has all these characteristics and an additional advantage of being inexpensive. On the other hand, all other modalities impose some kind of financial burden. In the third case report, we used a biologic shell crown for restoration of grossly decayed vital primary mandibular first molar. This method provided excellent esthetic with natural tooth anatomy and a promise to wear at a physiological rate with satisfied child and parent. But, one limitation faced by the operator was the requirement for a great deal of adjustment with increased chairside time. This can be of concern in a child with behavioral issues with little attention span and seeing such children in pediatric clinics is not uncommon. On the other hand, in first two case reports, the superficial anatomy was build up with composite using strip crowns in the first case and manually by incremental method in the second case. This method also provided excellent esthetics and in addition to patient and parent satisfaction, also resulted in operator satisfaction because of shorter chairside time.

One must appreciate the difference between “Case 1” and “Case 2” In “Case 1,” mesiodistal and buccolingual dimensions were almost uniform throughout the entire length of the post. While in “Case 2,” coronal part was wider than cervical part of the post. The cervical part was trimmed to conform to mesiodistal and buccolingual dimensions of root canal of the tooth to be restored. In “Case 2,” a minimal bulk of composite (approximately 1-2 mm thick veneer) was used as we relied on dentine core to replace bulk of tooth structure to be replaced. In case of larger dimensions of the tooth to be restored such as canine when compared with incisors, it is recommended to use post and core unit instead of isolated post because of the ability of former modality to restore a greater amount of tooth structure.

Previously, the dentine posts have been prepared using primary root dentine^[11] while we used premolar root dentine. Latter, being the most common teeth extracted for orthodontic reasons, are widely available, while former have limited availability. Another advantage of using the premolar root pieces is ease of finding them in sound form while it is difficult to get primary root dentine free of resorption as the resorption in primary teeth starts soon after eruption. The availability of intact crowns to be used as biologic shell crowns is limited owing to the absence of established tooth banks in most countries. But, the dentist should not face problems regarding availability for dentine post/post and core units.

Another limitation of using biologic restorations is pre-operative preparation such as sterilization and preparation of natural tooth to make dentine post/post and core/shell crown. But, these steps can be performed by dental auxiliaries, and the dentist does not need to spare time for this.

Some parents may find this technique objectionable and unacceptable. However, after counseling and assurance by the pediatric dentist about harmless nature of this restorative modality, this problem can be resolved easily.

Since the primary teeth have to resorb to allow eruption of their permanent counterparts, innovative short length posts are used. Biologic posts provide inexpensive, biocompatible and esthetic solution for intracanal reinforcement of primary teeth broken down to cervical level. Biologic shell crown, although being economic and esthetic option for restoration of primary anterior and posterior teeth, face limitation of limited availability and longer chairside time.

CONCLUSION

There exist no standardized procedures to restore broken down primary anterior teeth to the cervical level. The present technique served well to restore function; it provided satisfactory esthetics as well. However, while restoring with biologic shell crown, we faced problems due to the requirement for greater chairside adjustments. Thus, the technique presented for intracanal reinforcement using dentin post/post and core here can help pediatric dentists enjoy the satisfaction of providing the unparalleled services to their young clients of the preschool age.

REFERENCES

1. Mendes FM, De Benedetto MS, del Conte Zardetto CG, Wanderley MT, Correa MS. Resin composite restoration in primary anterior teeth using short-post technique and strip crowns: A case report. *Quintessence Int* 2004;35:689-92.
2. Wanderley MT, Ferreira SL, Rodrigues CR, Rodrigues Filho LE. Primary anterior tooth restoration using posts with macroretentive elements. *Quintessence Int* 1999;30:432-6.
3. Bell SJ, Morgan AG, Marshman Z, Rodd HD. Child and parental acceptance of preformed metal crowns. *Eur Arch Paediatr Dent* 2010;11:218-24.
4. Grewal N, Seth R. Comparative *in vivo* evaluation of restoring severely mutilated primary anterior teeth with biological post and crown preparation and reinforced composite restoration. *J Indian Soc Pedod Prev Dent* 2008;26:141-8.
5. Lauris JR, da Silva Bastos R, de Magalhaes Bastos JR. Decline in dental caries among 12-year-old children in Brazil, 1980-2005. *Int Dent J* 2012;62:308-14.
6. Marthaler TM. Changes in dental caries 1953-2003. *Caries Res* 2004;38:173-81.
7. Goyal A, Gauba K, Chawla HS, Kaur M, Kapur A. Epidemiology of dental caries in Chandigarh school children and trends over the last 25 years. *J Indian Soc Pedod Prev Dent* 2007;25:115-8.
8. Mortada A, King NM. A simplified technique for the restoration of severely mutilated primary anterior teeth. *J Clin Pediatr Dent* 2004;28:187-92.
9. Verma L, Passi S. Glass fibre-reinforced composite post and core used in decayed primary anterior teeth: A case report. *Case Rep Dent* 2011;2011:864254.
10. Memarpour M, Shafiei F. Restoration of primary anterior teeth using intracanal polyethylene fibers and composite: An *in vivo* study. *J Adhes Dent* 2013;15:85-91.
11. Ramires-Romito AC, Wanderley MT, Oliveira MD, Imparato JC, Corrêa MS. Biologic restoration of primary anterior teeth. *Quintessence Int* 2000;31:405-11.
12. Champagne C, Waggoner W, Ditmyer M, Casamassimo PS, MacLean J. Parental satisfaction with veneered stainless steel crowns for primary anterior teeth. *Pediatr Dent* 2007;29:465-9.
13. Kapur A, Chawla HS, Goyal A, Gauba K. An esthetic point of view in very young children. *J Clin Pediatr Dent* 2005;30:99-103.
14. Pithan S, Vieira Rde S, Chain MC. Tensile bond strength of intracanal posts in primary anterior teeth: An *in vitro* study. *J Clin Pediatr Dent* 2002;27:35-9.

How to cite this article: We will update details while making issue online***

Source of Support: Nil, **Conflict of Interest:** None declared.