

Original Article

The effect of voxel size on the measurement of mandibular thickness in cone-beam computed tomography

Ehsan Hekmatian¹, Nasim Jafari-Pozve², Ladan Khorrami¹

¹Torbinejad Dental Research Center and Department of Oral and Maxillofacial Radiology, ²Dental Implants Research Center and Department of Oral and Maxillofacial Radiology, School of Dentistry, Isfahan University of Medical Sciences, Isfahan, Iran

ABSTRACT

Background: Cone-beam computed tomography (CBCT) is a new imaging technology that has been widely used in implantology, oral and maxillofacial surgery and orthodontics. This method provides 3-D images that are composed of voxel, which is the smallest image unit, and determines image resolution. Smaller voxel is associated with the higher resolution and also greater radiation exposure. This study was aimed to find out the effect of voxel size on the measurement of mandibular thickness.

Materials and Methods: Using voxel sizes of 0.30 mm and 0.15 mm, two CBCT protocols (protocol 1: Field of view (FOV) of 15 cm, 85 kVp, 42 mAs, 0.15 mm voxel, 14 s scan time; protocol 2: FOV of 15 cm, 85 kVp, 10 mAs, 0.30 mm voxel, 14 s scan time) were carried out on 16 dry human mandibles with permanent dentition. Mandibular thickness was measured at seven different sites (midline region, bilateral canine regions, bilateral mental foramen regions and bilateral molar regions). Analysis of variance was used for analysis of data using the Statistical Package for the Social Sciences version 20 (SPSS Inc., Chicago, IL, USA). $P < 0.05$ considered to be statistically significant.

Results: No statistically significant differences were found between different protocols regarding the mandibular thickness ($P > 0.05$).

Conclusion: Considering the insignificant differences of the mandibular thickness measurements using different voxel sizes, it would be more reasonable to use 0.30 mm voxel size instead of 0.15 mm voxel size to avoid unnecessary radiation exposure.

Key Words: Cone-beam computed tomography, mandible, voxel

Received: February 2013

Accepted: August 2013

Address for correspondence:

Dr. Ladan Khorrami,
Torbinejad Dental Research
Center and Department
of Oral and Maxillofacial
Radiology, School of
Dentistry, Isfahan University
of Medical Sciences,
Isfahan, Iran. E-mail: ladan_
kh1387@yahoo.com

INTRODUCTION

Correct and precise diagnostic approaches are essential for a successful treatment.^[1] Radiology plays an important role in the diagnostic assessment of dental patients.^[2] For this reason, several imaging methods have been introduced and employed to improve the accuracy of diagnosis and treatment plans. Cone-beam computed tomography (CBCT)

is a novel imaging technology that has been used in the craniofacial region since 1998.^[3] First studies that confirmed the accuracy of CBCT in the oral and maxillofacial region was published in 2004.^[4,5] Comparing with conventional CT, CBCT has some advantages such as high performance, low cost and reduced radiation dose. CBCT imaging provide a great chance for examining morphologic aspects of the craniofacial complex, including alveolar bone and can be used to quantitatively assess bone height and thickness with high accuracy.^[6] CBCT offers images of the buccal and lingual bone plates, which are not apparent in conventional two-dimensional images due to superimposition.^[7] Considering these benefits, CBCT has been widely used in implantology, oral and maxillofacial surgery and orthodontics.^[8]

Access this article online



Website: <http://drj.mui.ac.ir>

A single 360° rotational scan provides CBCT image data in a digital format. For image reconstruction, the obtained information is rendered into a 3-dimensional (3-D) image using an algorithm for volumetric tomography.^[9] These 3-D images made by CBCT are composed of voxel, which is the smallest image unit and determines image resolution.^[9] The size of each voxel is determined by its height, width and thickness^[8] and the spatial resolution of CBCT depends upon the voxel dimension. The smaller voxel dimension results in the greater image resolution; however, higher radiation doses are needed for smaller voxel.^[1,10,11] In addition to the voxel size of the CBCT scanner, several other factors including the properties of the bone itself, the skill of the examiner (the person making the measurements), the software used to view and measure the CBCT images and the presence or absence of soft-tissue at and around the studied site may also potentially affect the accuracy of linear measurements of alveolar bone from CBCT images.^[12]

Although a number of studies have demonstrated the precision of linear measurements performed on CBCT images,^[13-15] it seems there is no study on the effects of the voxel size on measurement of mandibular thickness yet.

In light of the above, the aim of this study was to evaluate the influence of different image acquisition protocols on the measurement of thickness of the mandible to find out whether voxel size could lead to different mandibular thickness measurement or not.

MATERIALS AND METHODS

This was a descriptive-analytical study performed in Department of Oral and Maxillofacial Radiology and Torabinejad Dental Research Center, School of Dentistry, Isfahan University of Medical sciences between July 2012 and September 2012. Method of sampling was convenience sampling. After approval of the Anatomy Department of the Isfahan University of Medical Sciences, 16 dried human mandibles with complete canine-to-canine permanent dentitions in the mandibular front were selected.

Mandibles included in this study had approximately medium size, U-shape arch, without any fracture or defect on alveolar processes. Child's mandibles were excluded from the study.

Seven sites including midline region, bilateral canine regions, bilateral mental foramen regions and bilateral

molar regions were marked on each mandible using 2 mm × 1 mm strips of thin aluminum foil. Foils were placed on the buccal edge of alveolar processes in all selected sites. The base of each mandible was fixed on a tripod parallel to the ground.

Two CBCT scans with different settings were performed using a Galileos CBCT scanner (Sirona Dental Systems GmbH, Bensheim, Hessen, Germany).

Following image acquisition protocols were used for each mandible:

1. Protocol 1: Field of view (FOV) of 15 cm, 85 kVp, 42 mAs, 0.15 mm voxel, 14 s scan time
2. Protocol 2: FOV of 15 cm, 85 kVp, 10 mAs, 0.30 mm voxel, 14 s scan time.

A total of 32 CBCT scans were performed.

Measurement of the mandibular thickness was carried out on a multi-planar reconstruction screen using the Sidexis XG software (Sidexis next Generation 2.4, Sirona Dental Systems, Bensheim, Germany).

In order to measure the buccal-lingual thickness of the mandible at each of the aforementioned sites, the cursor was moved exactly 10 mm toward the occlusal direction from the inferior border on the cross section. Then, a line perpendicular to this line was drawn from the external limit of buccal/labial cortical plate to the external limit of the lingual cortical bone [Figure 1]. This distance was measured for all sites. All measurements were performed by an expert oral and maxillofacial radiologist.

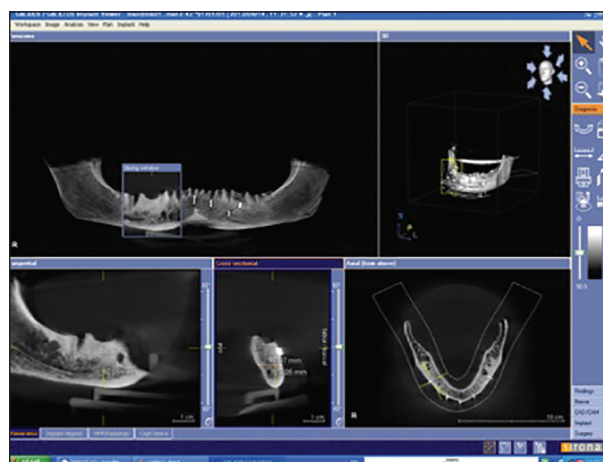


Figure 1: A screenshot of the image that shows measurement of bone thickness in the molar region of one mandible using the Sidexis XG software (Sidexis next Generation 2.4, Sirona Dental Systems, Bensheim, Germany)

Statistical analysis

Data were imported and analyzed by Statistical Package for the Social Sciences version 20 (SPSS Inc., Chicago, IL, USA). All descriptive statistics are presented as means and standard deviations for mandibular thickness in each measurement. According to the type of variables, analysis of variance was used to analyze data. The level of significance was set at $P < 0.05$ and all tests were two-tailed.

Ethics

The design of the study was approved in Ethics Committee of Vice Chancellor for Research, Isfahan University of Medical Sciences (Project No. 391467).

RESULTS

After comparison of the mandibular thickness measurements using different protocols, no statistically significant differences were found between different protocols regarding the mandibular thickness ($P > 0.05$) [Table 1].

DISCUSSION

CBCT dedicated to maxillofacial imaging introduces an innovation in maxillofacial imaging.^[1] Since the advent of CBCT scanners in the previous decades, there has been an explosion of interest in the application of these devices in various fields such as oral and maxillofacial surgery, orthodontics and dentistry.^[16]

Considering the increasing applicability of this imaging modality in dentistry, it is vital to determine an image acquisition protocol that provides 3-D views with the appropriate resolution for evaluation of different bony structures.^[1]

Table 1: Comparison of the mandibular thickness at different sites using different protocols

Location	Protocol 1		Protocol 2		P value
	Mean	SD	Mean	SD	
Right molar ($n=16$)	11.01	2.00	10.99	2.03	0.99
Right mental Foramen ($n=16$)	9.74	1.67	9.78	1.53	0.99
Right canine ($n=16$)	9.24	1.21	9.17	1.24	0.99
Midline ($n=16$)	12.26	1.91	12.25	1.71	0.98
Left canine ($n=16$)	9.03	1.79	9.25	1.34	0.96
Left mental foramen ($n=16$)	9.95	1.45	9.95	1.48	0.99
Left molar ($n=16$)	11.04	2.09	11.07	2.08	1.00

n: Number of cases; SD: Standard deviation; Protocols - Protocol 1: FOV of 15 cm, 85 kVp, 42 mAs, 0.15 mm voxel, 14 s scan time; Protocol 2: FOV of 15 cm, 85 kVp, 10 mAs, 0.30 mm voxel, 14 s scan time; FOV: Field of view

It is well-known that spatial resolution of the image is inversely correlated with the voxel dimension and voxel size is also inversely correlated with the radiation dose.^[10] Therefore, before selecting the image acquisition protocol, it is necessary to determine the cost-benefit ratio of the selected protocol according to the as low as reasonably achievable dose of radiation (ALARA) principles. ALARA principle suggests choosing the scanning protocol with the lowest possible radiation dose that provides an image with the adequate resolution for assessment of the structures.^[1]

Given the above, the important question is whether the higher image resolution leads to different measurement results or not. This study was performed to answer this question when CBCT was employed to measure the mandibular thickness at different sites.

To the best of our knowledge, it seems this is the first investigation that has measured and compared the mandibular thickness at different sites using different image acquisition protocols. Present study demonstrated that although smaller voxel (high resolution) protocols have been reported to be associated with higher level of radiation exposure,^[1] using image acquisition protocols with smaller voxel size did not lead to different mandibular thickness measurements in all seven examined areas.

The combination of these findings implies that using protocols with smaller voxel dimension only increases radiation-related risks with no additional benefits.

A number of studies have investigated the influence of voxel size on imaging outcomes in different clinical settings. Kamburoğlu *et al.* assessed the effect of CBCT voxel size (0.1 mm, 0.2 mm, and 0.3 mm) on the diagnosis of occlusal caries. Using *in-vitro* models, they concluded that at all voxel sizes, CBCT images can be considered a tool for use in the diagnosis of occlusal caries with no significant difference in relative treatment effect values.^[17]

Wood also conducted an animal study to determine factors affecting alveolar bone height measurements from CBCT Images. Although wood initially hypothesized that voxel size may have an impact on the measurements from CBCT images, he concluded that the voxel-dimension factor had an insignificant impact on the measurements.^[12]

Damstra *et al.* performed a study on 10 dried mandibles to investigate the influence of voxel

resolution on the linear accuracy of CBCT surface models. The mandibles were scanned with 0.40 and 0.25 voxel size resolutions. They reported that an increased voxel resolution did not result in greater accuracy of the surface model measurements.^[18]

In another study, Liedke *et al.* viewed 59 teeth for external root resorption (ERR) following three protocols in which the variation was the voxel size (0.4, 0.3 and 0.2 mm). It was concluded that CBCT is a reliable method for the investigation of simulated ERR, and a 0.3 mm voxel appeared to be the best protocol, associating good diagnostic performance with lower X-ray exposure.^[19]

In contrast to the findings of present study, Sun *et al.* have shown that voxel size may affect the accuracy of linear measurements and the diagnostic quality of CBCT images. After evaluation of 11 maxillary specimens from 6-month-old pigs, they found that measurement inaccuracies of alveolar bone height were substantially improved after using protocols with smaller voxel size (from 0.40 mm to 0.25 mm).^[20] The use of different study designs could explain the differences observed in this study.

One of the major limitations of the present study was the use of dried mandibles without natural soft-tissue. We did not use soft-tissue equivalent such as water bath. Using water bath may cause problems for positioning, and may damage dry mandibles.^[21-23] In addition, the mandibles we used did not move and had fiducial markers for measurement. These conditions also make them different from living cases. The other limitation to this study was that the obtained protocol results were not compared with a gold standard.

CONCLUSION

In summary, considering the insignificant differences of the mandibular thickness measurements using different voxel sizes, it would be more reasonable to use 0.30 mm voxel size instead of 0.15 mm voxel size to avoid unnecessary radiation exposure.

REFERENCES

- Moshfeghi M, Tavakoli MA, Hosseini ET, Hosseini AT, Hosseini IT. Analysis of linear measurement accuracy obtained by cone beam computed tomography (CBCT-NewTom VG). *Dent Res J (Isfahan)* 2012;9:S57-62.
- Scarfe WC, Farman AG, Sukovic P. Clinical applications of cone-beam computed tomography in dental practice. *J Can Dent Assoc* 2006;72:75-80.
- Mozzo P, Procacci C, Tacconi A, Martini PT, Andreis IA. A new volumetric CT machine for dental imaging based on the cone-beam technique: Preliminary results. *Eur Radiol* 1998;8:1558-64.
- Kobayashi K, Shimoda S, Nakagawa Y, Yamamoto A. Accuracy in measurement of distance using limited cone-beam computerized tomography. *Int J Oral Maxillofac Implants* 2004;19:228-31.
- Lascalea CA, Panella J, Marques MM. Analysis of the accuracy of linear measurements obtained by cone beam computed tomography (CBCT-NewTom). *Dentomaxillofac Radiol* 2004;33:291-4.
- Timock AM, Cook V, McDonald T, Leo MC, Crowe J, Benninger BL, *et al.* Accuracy and reliability of buccal bone height and thickness measurements from cone-beam computed tomography imaging. *Am J Orthod Dentofacial Orthop* 2011;140:734-44.
- Fuhrmann RA, Bucker A, Diedrich PR. Furcation involvement: Comparison of dental radiographs and HR-CT-slices in human specimens. *J Periodontal Res* 1997;32:409-18.
- Patcas R, Müller L, Ullrich O, Peltomäki T. Accuracy of cone-beam computed tomography at different resolutions assessed on the bony covering of the mandibular anterior teeth. *Am J Orthod Dentofacial Orthop* 2012;141:41-50.
- Cho PS, Johnson RH, Griffin TW. Cone-beam CT for radiotherapy applications. *Phys Med Biol* 1995;40:1863-83.
- Farman AG, Scarfe WC. Development of imaging selection criteria and procedures should precede cephalometric assessment with cone-beam computed tomography. *Am J Orthod Dentofacial Orthop* 2006;130:257-65.
- Molen AD. Considerations in the use of cone-beam computed tomography for buccal bone measurements. *Am J Orthod Dentofacial Orthop* 2010;137:S130-5.
- Wood R, Sun Z, Chaudhry J, Tee BC, Kim DG, Leblebicioglu B, *et al.* Factors affecting the accuracy of buccal alveolar bone height measurements from cone-beam computed tomography images. *Am J Orthod Dentofacial Orthop* 2013;143:353-63.
- Loubele M, Van Assche N, Carpentier K, Maes F, Jacobs R, van Steenberghe D, *et al.* Comparative localized linear accuracy of small-field cone-beam CT and multislice CT for alveolar bone measurements. *Oral Surg Oral Med Oral Pathol Oral Radiol Endod* 2008;105:512-8.
- Ludlow JB, Laster WS, See M, Bailey LJ, Hershey HG. Accuracy of measurements of mandibular anatomy in cone beam computed tomography images. *Oral Surg Oral Med Oral Pathol Oral Radiol Endod* 2007;103:534-42.
- Misch KA, Yi ES, Sarment DP. Accuracy of cone beam computed tomography for periodontal defect measurements. *J Periodontol* 2006;77:1261-6.
- De Vos W, Casselman J, Swennen GR. Cone-beam computerized tomography (CBCT) imaging of the oral and maxillofacial region: A systematic review of the literature. *Int J Oral Maxillofac Surg* 2009;38:609-25.
- Kamburoğlu K, Murat S, Yüksel SP, Cebeci AR, Paksoy CS. Occlusal caries detection by using a cone-beam CT with different voxel resolutions and a digital intraoral sensor. *Oral Surg Oral Med Oral Pathol Oral Radiol Endod* 2010;109:e63-9.

18. Damstra J, Fourie Z, Huddleston Slater JJ, Ren Y. Accuracy of linear measurements from cone-beam computed tomography-derived surface models of different voxel sizes. *Am J Orthod Dentofacial Orthop* 2010;137:16.e1-6.
19. Liedke GS, da Silveira HE, da Silveira HL, Dutra V, de Figueiredo JA. Influence of voxel size in the diagnostic ability of cone beam tomography to evaluate simulated external root resorption. *J Endod* 2009;35:233-5.
20. Sun Z, Smith T, Kortam S, Kim DG, Tee BC, Fields H. Effect of bone thickness on alveolar bone-height measurements from cone-beam computed tomography images. *Am J Orthod Dentofacial Orthop* 2011;139:e117-27.
21. Lagravère MO, Carey J, Toogood RW, Major PW. Three-dimensional accuracy of measurements made with software on cone-beam computed tomography images. *Am J Orthod Dentofacial Orthop* 2008;134:112-6.
22. Hassan B, van der Stelt P, Sanderink G. Accuracy of three-dimensional measurements obtained from cone beam computed tomography surface-rendered images for cephalometric analysis: Influence of patient scanning position. *Eur J Orthod* 2009;31:129-34.
23. Stratemann SA, Huang JC, Maki K, Miller AJ, Hatcher DC. Comparison of cone beam computed tomography imaging with physical measures. *Dentomaxillofac Radiol* 2008;37:80-93.

How to cite this article: Hekmatian E, Jafari-Pozve N, Khorrami L. The effect of voxel size on the measurement of mandibular thickness in cone-beam computed tomography. *Dent Res J* 2014;11:544-8.

Source of Support: This study was supported by Isfahan University of Medical Sciences Research Grant #391467. **Conflict of Interest:** None declared.