

Original Article

Systemic effects of fluoxetine on the amount of tooth movement, root resorption, and alveolar bone remodeling during orthodontic force application in rat

Mehdi Rafiei¹, Soosan Sadeghian¹, Nakisa Torabinia², Valiollah Hajhashemi³

¹Department of Orthodontics, School of Dentistry, Islamic Azad University, Isfahan (Khorasgan) Branch, ²Dental Materials Research Center and Department of Oral Pathology, School of Dentistry, Isfahan University of Medical Sciences, ³Department of Pharmacology, Isfahan University of Medical Sciences, Isfahan, Iran

ABSTRACT

Background: Antidepressant drugs such as fluoxetine are of the most commonly used drugs among the public. These drugs may impact the regulation of bone cell functioning, and thus affect orthodontic tooth movement. The aim of this study was to determine the effect of fluoxetine on tooth movements during orthodontic treatment in rats.

Materials and Methods: In this study, 30 male rats were randomly assigned into two groups and injected with fluoxetine 10 mg/kg (experimental group) and normal saline (control group) for a period of 1-month intraperitoneally 5 times/week. Then, the rats were anesthetized and a nickel-titanium closed-coil spring was placed between the left maxillary first molar and left maxillary central incisors of all samples, and then fluoxetine (experimental group) and normal saline (control group) were injected for another 3 weeks by the same method. After measuring tooth movements, rats were sacrificed, and histomorphometric analyses were conducted and the obtained data were statistically analyzed using independent *t*-test and the significance was set at 0.05.

Results: Following the fluoxetine injection, the mean amount of tooth movements in the experimental group was reduced compared to the control group, which was not statistically significant ($P = 0.14$). There was no significant difference between the two groups regarding bone apposition rate ($P = 0.83$), external root resorption rate ($P = 0.1$), and mean number of root resorption lacunae ($P = 0.16$).

Conclusion: Within the limitations of this study, systemic use of fluoxetine may cause insignificant reduction of tooth movement rate in rats; however, this subject needs more evaluations.

Key Words: Antidepressant drugs, bone remodeling, fluoxetine, root resorption, tooth movement

Received: May 2014
Accepted: May 2015

Address for correspondence:

Dr. Soosan Sadeghian,
Department of
Orthodontics, School
of Dentistry, Islamic
Azad University, Isfahan
(Khorasgan) Branch, Isfahan,
Iran.
E-mail: m_rafiei@
hotmail.com

INTRODUCTION

Orthodontic treatment includes controlled force application onto the teeth and their surrounding structures.^[1] After applying orthodontic forces, the

periodontium goes out of balance; on the resorption side, osteoclast precursors move to the bone surface

This is an open access article distributed under the terms of the Creative Commons Attribution-NonCommercial-ShareAlike 3.0 License, which allows others to remix, tweak, and build upon the work non-commercially, as long as the author is credited and the new creations are licensed under the identical terms.

For reprints contact: reprints@medknow.com

How to cite this article: Citation will be included before issue gets online***

Access this article online



Website: www.drj.ir
www.drjjournal.net
www.ncbi.nlm.nih.gov/pmc/journals/1480

and differentiate. At the same time, osteoblasts that are derived from local cells form the bone on the tension side and start the process of remodeling in the resorbed areas in the pressure side.^[2]

Prostaglandin E has an important role in the cascade of signals related to tooth movement, and it seems that its inhibitors also affect the tooth movement. Several drug classes, such as tricyclic antidepressant drugs, can affect prostaglandins and the orthodontic force responses.^[2] On the other hand, given the increasing rate of depression among adolescents and young adults in Iran and the world which results in the consumption of antidepressants, the significance of these drugs has increased.^[3] Accordingly, it is likely that a considerable percentage of those who are candidates for orthodontic treatment may be consuming these types of drugs to treat their depression. Fluoxetine is an antidepressant of the selective serotonin reuptake inhibitor (SSRI) class, which can treat disorders such as depression, anxiety, and obsession. This drug can have an important role in bone regulation in growing individuals because it remains for a long time in bone marrow after complete elimination from plasma and brain.^[4]

In studying the effects of several antidepressant drugs such as fluoxetine, it was discovered that this drug has destructive effects on both trabecular and cortical bones.^[5] Furthermore, it was determined that peripheral serotonin produced by the intestinal cells lead to a decrease in osteoblast proliferation and can affect the bone density.^[6]

Branco-de-Almeida *et al.*^[7] evaluated the anti-inflammatory effects of fluoxetine on lab rats and showed that fluoxetine reduces the inflammatory response and prevents the bone loss, and it may be beneficial in treating periodontal diseases. Furthermore, Mortazavi *et al.*^[8] found that fluoxetine can improve the level of bone regeneration in calvarial bone lesions.

Finally, considering that the effects of antidepressant drugs on the bones have been proven, but the effects of these drugs on alveolar bone and following tooth movement have not been studied, and also the high prevalence of antidepressant drugs' consumption, especially fluoxetine, in the Iranian society,^[3] in this study, we attempted to investigate the effect of fluoxetine on tooth movements and alveolar bone in lab rats.

MATERIALS AND METHODS

This experimental animal study was performed on 30 male rats between the ages of 8 and 10 weeks (beginning of rats' sexual maturation). The rats were randomly divided into two groups of experimental and control (15 rats in each group). Given the maximum variance equal to $\alpha = 0.05$ unit, the required number of rats for both groups was 27, which 30 rats (15 in each group) were collected and sampling was conducted in the animals' convenience form.

The experimental group rats were intraperitoneally injected with 10 mg/kg fluoxetine^[9] (Abidi Pharmacy, Iran) 5 times/week and the control group rats were injected with normal saline in the same method. After 1-month, the rats were anesthetized using 20 mg/kg ketamine hydrochloride 10% (Dork Davis, France). The distance between the maxillary central incisor's incisal edge and the mesiobuccal cusp of the upper first molar on the left side was measured using a digital caliper^[10] (1108-150, Insize Co., China). Then, the first molar and left maxillary central incisor were perforated using a fissure bur (flat end cylinder 835, Teeskavan, Iran) and a 0.01 inch ligature wire (Ligature Ties 0.01, Orthotechnology, USA) which a nickel-titanium closed-coil spring (close coil spring with eyelets, size 9F, G & H wire Co., USA) had gone through it, was tied around the first molar and maxillary central incisor, so that a 50 g load could be applied in the desired area. After that, the drug injection was continued for another 3 weeks by the same method.

Due to the difficulty of maintaining the coil spring inside the rat's oral cavity, the drug was injected first and after 1-month the appliance was placed. Regarding the continuous eruption of rat's mandibular incisors which cause attrition in maxillary incisors, the coil spring would have become detached if maintained for a long time. According to similar studies, 3 weeks was enough for inducing tooth movement.^[11] However, 6 weeks is necessary for evaluating the fluoxetine effect on the bone structure.^[9]

After 3 weeks, the rats were anesthetized, and the distance between the incisor and maxillary molar was measured with a digital caliper again. The tooth movements throughout the 21 days were calculated and then the rats were sacrificed, decapitated, placed in 10% formalin (Merck, Germany) and were sent to the laboratory. In the laboratory, samples were prepared from the maxillary first molar along with

the adjacent bone. Samples were then stabilized in buffered 10% formalin (Merck, Germany) for 24 h and after that, they were kept in acid for 24 h, and the preparation steps were conducted.

Tissues were sectioned longitudinally from the mesiobuccal root and the adjacent bone (serial section with 4-5 micron thickness), by using a microtome (Leica, RM 2035, Germany). The sections were placed on slides and stained with trichromasson stain (Merk, Germany) for identifying bone formation [Figures 1 and 2].

The number of root resorption lacunae was calculated in 5 nonoverlapping high power fields by light microscope (Olympus BX-51, Japan) with magnification $\times 400$ by an oral pathologist twice and with a time interval of 4 weeks.

The percentage of bone apposition was calculated histomorphologically using Nilu software (Nilu pathology image analyzer, Iran). This software is based on different color identification. In Trichrome Masson staining, bone formation is colored as blue and histomorphologically, in $\times 100$ magnification, the percentage of bone formation was calculated.

Root resorption rate was measured using the described software (Nilu pathology image analyzer, Iran). For this purpose, the surface area of the whole root and the surface area of the root resorption lacunae were measured in each cross section. Using the following formula, the percentage of root resorption area was calculated.

$$\frac{\text{SARRL}}{\text{SAWR}} = \text{PRRA}$$

All measurements were performed by a pathologist 2 times and with a time interval of 4 weeks.

Finally, the mean values for the two experimental and control groups were analyzed through the independent *t*-test and SPSS version 18 (SPSS Inc., Chicago, IL, USA) was used for data analysis. The significance was set at 0.05.

RESULTS

In this study, the following results were obtained:

- The mean tooth movements for the experimental group samples was 1.5 ± 0.76 mm and for the control group was 2.07 ± 0.49 mm, which indicates that the level of tooth movements was reduced subsequent to the injection of fluoxetine, but this was not statistically significant ($P = 0.14$) [Table 1].
- The mean bone apposition rate was $7.02\% \pm 4.05\%$ in the control group and $6.52\% \pm 3.91\%$ for the experimental group, which showed that there was no significant difference between two groups regarding bone mineral apposition rates ($P = 0.83$) [Table 1].
- The mean external root resorption was $0.49\% \pm 0.36\%$ in the control group and $0.14\% \pm 0.35\%$ in the experimental group that revealed that there was no significant difference between the two groups

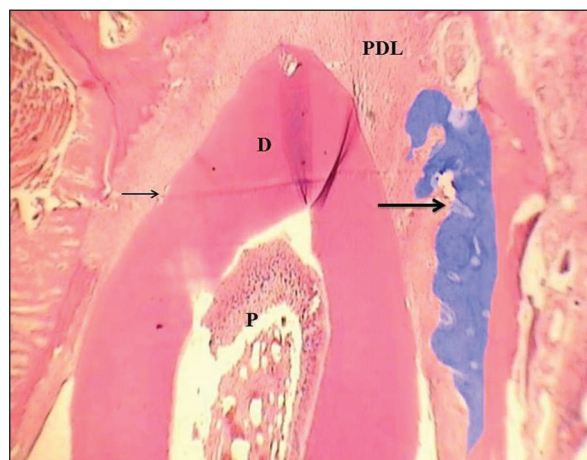


Figure 1: Microscopic view of first mesiobuccal root of lab rat in control group staining with Trichrome Masson. P: Pulp; D: Dentine; PDL: Periodontal ligament; Large arrow: New bone apposition; Small arrow: Resorption area.

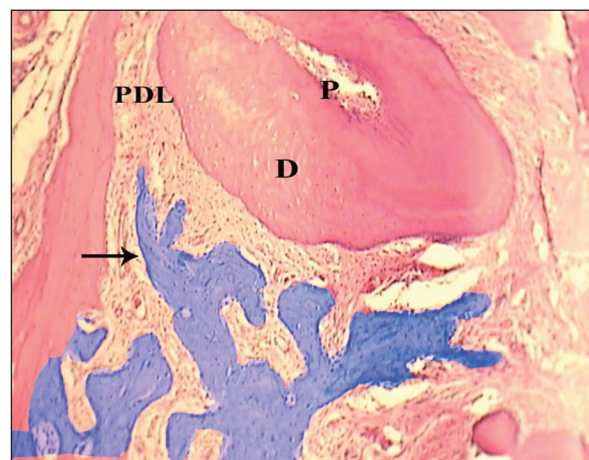


Figure 2: Microscopic view of first mesiobuccal root of lab rat in experimental group staining with Trichrome Masson. P: Pulp; D: Dentine; PDL: Periodontal ligament; Large arrow: New bone apposition; Small arrow: Resorption area.

Table 1: Amount of tooth movement (mm), bone apposition rate, root resorption rate, and number of root resorption lacunae in experimental and control groups. ($\alpha=0.05$)

Variable	Group	Mean \pm SD	P
Amount of tooth movement	Control	2.07 \pm 0.49	0.14
	Experimental	1.50 \pm 0.76	
Bone apposition rate	Control	7.02 \pm 4.05	0.83
	Experimental	6.52 \pm 3.91	
Root resorption rate	Control	0.46 \pm 0.36	0.1
	Experimental	0.14 \pm 0.35	
Number of root resorption lacuna	Control	1.75 \pm 0.98	0.16
	Experimental	1.21 \pm 0.67	

SD: Standard deviation

regarding the external root resorption rates ($P = 0.1$) [Table 1].

- The mean number of root resorption lacunae in control group samples was 1.57 ± 0.98 and in the experimental group was 1.21 ± 0.67 , which shows that there was no significant difference ($P = 0.16$) [Table 1].

DISCUSSION

In this research, we investigated how fluoxetine effects the amount of tooth movements and root resorption during the tooth movements. In this study, we concluded that tooth movement rate was reduced after fluoxetine injection.

The reason for selecting fluoxetine in this study was a high prevalence of its consumption in the society. Although there are many studies which have evaluated the effect of antidepressant drugs on bone formation and bone density, no study has yet evaluated the effects of these drugs on the amount of tooth movement.

Applying orthodontic forces on the pressure side, cytokines such as prostaglandin E2 and interleukin 1 and 6 and also tumor necrosis factor- α are released from the periodontal ligament cells, which leads to inflammation and increase of receptor activator of nuclear factor kappa-B ligand and followed by that the osteoclasts are activated and cause bone loss in the pressure side and cause tooth movements.^[12] If this inflammatory process could be reduced in the pressure side, tooth movement could be decreased.

Many studies have evaluated the anti-inflammatory effect of fluoxetine. Waiskopf *et al.*^[13] showed the anti-inflammatory effects of fluoxetine. Branco-de-Almeida *et al.*^[7] also showed the anti-inflammatory

effects of this drug on lab rats. Furthermore, Alboni *et al.*^[14] revealed the anti-inflammatory effects of long-term consumption of fluoxetine and imipramine on the hypothalamus of rat. Thus, the reduction of tooth movements in the present study is associated with the anti-inflammatory effects of fluoxetine. However, the drug's effect on the osteoblasts and osteoclasts can also be considered.

In depression, the brain's serotonin level decreases. Fluoxetine occupies the serotonin receptors; therefore, its reuptake is reduced which leads to higher serotonin levels. Serotonin has various receptors in the peripheral organs. Osteoclast and osteoblast also have serotonin receptors and the effect of fluoxetine on bone cells is through these receptors.

Contradictory results have been reported regarding the effects of fluoxetine on the increase in resorption and apposition. Battaglino *et al.*^[9] showed that systematically prescribing fluoxetine leads to an increase of trabecular and a decrease of the trabecular space in the bone. Mortazavi *et al.*^[8] also showed the increase of ossification when using fluoxetine in the calvarial lesions of lab rats. Gustafsson *et al.*^[15] also showed positive effects of serotonin on increasing ossification and decreasing bone loss in lab rats, which the results of these studies correspond to the reduction of tooth movements obtained in the present study. Fluoxetine does not always cause an increase in the osteoblast activity. Some studies have reported an increasing risk of osteoporosis in patients who consume this drug, which shows an increase in osteoclast activity.^[5,16-18] Bonnet *et al.*^[5] showed a reduction in bone strength and a reduction of minerals in the femur of rats after consuming fluoxetine. Warden *et al.*^[17] confirmed the anti-anabolic effects of fluoxetine and the anabolic effects of lithium behavior stabilizing antidepressant drugs. Shea *et al.*^[18] observed more bone loss after using SSRI drugs. Diem *et al.*^[16] and Richards *et al.*^[12] showed that antidepressant drugs lead to an increase in clinical fractures. The results of these studies do not agree with the reduction of tooth movements observed in the present study. Maybe if another antidepressant drug was used instead of fluoxetine, the reduction in tooth movements would be more evident. Because these drugs in addition to their anti-inflammatory properties, which is also seen in fluoxetine, have positive effects on bone mineral density and bone anabolic properties. However, in the case of fluoxetine, the results were contradictory.

As it has been shown in two previous studies,^[8,19] ossification rate is highly dependent on the dose, if fluoxetine was used in different doses, different results would be obtained.

In the microscopic evaluation, the level of ossification adjacent to the mesiobuccal root of the maxillary first molar was investigated, which was used to determine the effect of fluoxetine on the mineralization during alveolar bone remodeling. The lower amount of bone apposition observed in the experimental group could be associated with the ability of fluoxetine in preventing human mesenchymal stem cells and preosteoblast. This finding agrees with the results of Bonnet *et al.*,^[5] Warden *et al.*^[17] and Richards *et al.*^[12] which indicated that fluoxetine consumption reduces bone mineral density and increases the rate of bone fracture.

The external root resorption rate and mean number of root resorption lacunae in the experimental and control groups showed a reduction in the root resorption rate in the experimental group, yet the amount of this reduction was not significant. The minor root resorption reduction in the experimental group can be related to fluoxetine's anti-inflammatory effects. Inflammation activates osteoclasts which as a side effect can cause root resorption during orthodontic movements,^[1] and this finding agrees with the results of Reitan^[20] that stated lateral root resorption during orthodontic tooth movements is common.

There is also a relationship between bone density and root resorption. Teeth that are moved close to the dense cortical bone show more root resorption compared to cases where the tooth is moved in the trabecular bone.^[21] In this study, due to the effect of the fluoxetine injection, the bone's mineral apposition rate was reduced. The lower amount of root resorption observed in the experimental group, in addition to the anti-inflammatory effects of the drug, was due to this less bone density. Finally, the reduced mineral apposition rate of the experimental group compared to the control group confirms the drug's ability to reduce osteoblastic activity and increase osteoclastic activity. Therefore, the less tooth movement in the experimental group is due to the drug's anti-inflammatory function, which can be the cause for less root resorption in the experimental group.

It should be mentioned that the results of animal studies cannot be always extended to humans because the dose, duration of force prescription, bone

structure, and force level are not the same between human and rat.

CONCLUSION

Within limitations of this study, systemic use of fluoxetine can cause insignificant reduction of tooth movement rate in rats; however, this subject needs more clarification by future research.

Financial support and sponsorship

Nil.

Conflicts of interest

The authors of this manuscript declare that they have no conflicts of interest, real or perceived, financial or non-financial in this article.

REFERENCES

1. Graber LW, Vanarsdall RL, Vig KW. Orthodontics Current Principle and Techniques. 5th ed. Philadelphia: Elsevier; 2011. p. 247-85, 921.
2. Proffit WR, Henry WF, Sarver DM, Ackerman JL. Contemporary Orthodontics. 5th ed. St. Louis: Elsevier; 2013. p. 278-312.
3. Jahan News. Comparison of depression between Iran and other countries. Available from: <http://www.jahannews.com/vdccsmqp.2bq4i8laa2.html>. [Last accessed on 2009 Jun 28; Last accessed on 2014 Jun 07].
4. Bolo NR, Hodé Y, Macher JP. Long-term sequestration of fluorinated compounds in tissues after fluvoxamine or fluoxetine treatment: A fluorine magnetic resonance spectroscopy study *in vivo*. *MAGMA* 2004;16:268-76.
5. Bonnet N, Bernard P, Beaupied H, Bizot JC, Trovero F, Courteix D, *et al.* Various effects of antidepressant drugs on bone microarchitecture, mechanical properties and bone remodeling. *Toxicol Appl Pharmacol* 2007;221:111-8.
6. De Vernejoul MC, Collet C, Chabbi-Achengli Y. Serotonin: Good or bad for bone. *Bonekey Rep* 2012;1:120.
7. Branco-de-Almeida LS, Franco GC, Castro ML, Dos Santos JG, Anbinder AL, Cortelli SC, *et al.* Fluoxetine inhibits inflammatory response and bone loss in a rat model of ligature-induced periodontitis. *J Periodontol* 2012;83:664-71.
8. Mortazavi SH, Khojasteh A, Vaziri H, Khoshzaban A, Roudsari MV, Razavi SH. The effect of fluoxetine on bone regeneration in rat calvarial bone defects. *Oral Surg Oral Med Oral Pathol Oral Radiol Endod* 2009;108:22-7.
9. Battaglino R, Vokes M, Schulze-Späte U, Sharma A, Graves D, Kohler T, *et al.* Fluoxetine treatment increases trabecular bone formation in mice. *J Cell Biochem* 2007;100:1387-94.
10. Esfahani NE, Sadeghian S, Razavi SM, Minaiyan M, Afsari E. The effects of simvastatin on bone remodeling, tooth movement and root resorption in orthodontic treatments. *Biomed Pharm J* 2013;6:271-8.
11. Igarashi K, Mitani H, Adachi H, Shinoda H. Anchorage and retentive effects of a bisphosphonate (AHBuBP) on

- tooth movements in rats. *Am J Orthod Dentofacial Orthop* 1994;106:279-89.
12. Richards JB, Papaioannou A, Adachi JD, Joseph L, Whitson HE, Prior JC, *et al.* Effect of selective serotonin reuptake inhibitors on the risk of fracture. *Arch Intern Med* 2007;167:188-94.
 13. Waiskopf N, Ofek K, Gilboa-Geffen A, Bekenstein U, Bahat A, Bennett ER, *et al.* AChE and RACK1 promote the anti-inflammatory properties of fluoxetine. *J Mol Neurosci* 2014;53:306-15.
 14. Alboni S, Benatti C, Montanari C, Tascetta F, Brunello N. Chronic antidepressant treatments resulted in altered expression of genes involved in inflammation in the rat hypothalamus. *Eur J Pharmacol* 2013;721:158-67.
 15. Gustafsson BI, Thommesen L, Fossmark R, Waldum HL, Syversen U. Serotonin affects bone metabolism *in vitro* and leads to increased bone mineral density (BMD) in female rats. *J Bone Miner Res* 2003;18 Suppl 2:s193.
 16. Diem SJ, Blackwell TL, Stone KL, Yaffe K, Haney EM, Bliziotes MM, *et al.* Use of antidepressants and rates of hip bone loss in older women: The study of osteoporotic fractures. *Arch Intern Med* 2007;167:1240-5.
 17. Warden SJ, Hassett SM, Bond JL, Rydberg J, Grogg JD, Hilles EL, *et al.* Psychotropic drugs have contrasting skeletal effects that are independent of their effects on physical activity levels. *Bone* 2010;46:985-92.
 18. Shea ML, Garfield LD, Teitelbaum S, Civitelli R, Mulsant BH, Reynolds CF 3rd, *et al.* Serotonin-norepinephrine reuptake inhibitor therapy in late-life depression is associated with increased marker of bone resorption. *Osteoporos Int* 2013;24:1741-9.
 19. Gustafsson BI, Thommesen L, Stunes AK, Tommeras K, Westbroek I, Waldum HL, *et al.* Serotonin and fluoxetine modulate bone cell function *in vitro*. *J Cell Biochem* 2006;98:139-51.
 20. Reitan K. Tissue behavior during orthodontic tooth movement. *Am J Orthod* 1960;46:881.
 21. Horiuchi A, Hotokezaka H, Kobayashi K. Correlation between cortical plate proximity and apical root resorption. *Am J Orthod Dentofacial Orthop* 1998;114:311-8.