

## Review Article

# Cyclosporine A: Novel concepts in its role in drug-induced gingival overgrowth

Deepa Ponnaiyan<sup>1</sup>, Visakan Jegadeesan<sup>2</sup>

<sup>1</sup>Department of Periodontics, SRM Dental College and Hospital, Ramapuram, <sup>2</sup>Department of Oral and Maxillofacial Surgery, MIOT Hospitals, Manapakkam, Chennai, Tamil Nadu, India

## ABSTRACT

Cyclosporine is a selective immunosuppressant that has a variety of applications in medical practice. Like phenytoin and the calcium channel blockers, the drug is associated with gingival overgrowth. This review considers the pharmacokinetics, pharmacodynamics, and unwanted effects of cyclosporine, in particular the action of the drug on the gingival tissues. In addition, elucidates the current concepts in mechanisms of cyclosporine-induced gingival overgrowth. Clinical and cell culture studies suggest that the mechanism of gingival overgrowth is a result of the interaction between the drug and its metabolites with susceptible gingival fibroblasts. Plaque-induced gingival inflammation appears to enhance this interaction. However, understanding of the pathogenesis of gingival overgrowth is incomplete at best. Hence, it would be pertinent to identify and explore possible risk factors relating to both prevalence and severity of drug-induced gingival overgrowth. Newer molecular approaches are needed to clearly establish the pathogenesis of gingival overgrowth and to provide novel information for the design of future preventive and therapeutic modalities.

**Key Words:** Cyclosporine, fibroblast, gingival overgrowth, periodontitis, phenytoin, Renin-Angiotensin system

Received: April 2014  
Accepted: October 2014

Address for correspondence:  
Dr. Deepa Ponnaiyan,  
F4 Rajendra Apartments,  
9 Babu Rajendra Prasad  
Street, West Mambalam,  
Chennai - 600 033,  
Tamil Nadu, India.  
E-mail: [deepa\\_ponnaiyan@  
yahoo.co.in](mailto:deepa_ponnaiyan@yahoo.co.in)

## INTRODUCTION

The story of cyclosporine A (CsA) began in soil samples from Wisconsin (US) which was propagated and studied in the laboratories of the Sandoz Company in Switzerland. It yielded the fungus *Tolypocladium inflatum* gams which was used to synthesize cyclosporine.<sup>[1]</sup> The fungus is still used today for the production of CsA on a commercial scale via fermentation with remarkable immunosuppressive effect and extremely low toxicity. CsA a hydrophobic fungal metabolite is a potent immunosuppressant used as the first choice

for counteracting the rejection phenomena in organ transplantation patients and for the treatment of various autoimmune diseases.<sup>[2,3]</sup>

The use of CsA, however, is associated with various side effects including neurotoxicity,<sup>[4]</sup> hepatotoxicity,<sup>[5]</sup> nephrotoxicity,<sup>[6]</sup> hypertension,<sup>[7]</sup> and gingival hyperplasia.<sup>[8]</sup> CsA-induced gingival hyperplasia was first reported by Seymour *et al.* in 1983 occurring in 25-81% of patients taking CsA.<sup>[9]</sup> A wide range of prevalence rate has been reported estimated between 8% and 70% for CsA.<sup>[10]</sup> The lesion usually

This is an open access article distributed under the terms of the Creative Commons Attribution-NonCommercial-ShareAlike 3.0 License, which allows others to remix, tweak, and build upon the work non-commercially, as long as the author is credited and the new creations are licensed under the identical terms.

**For reprints contact:** [reprints@medknow.com](mailto:reprints@medknow.com)

**How to cite this article:** Ponnaiyan D, Jegadeesan V. Cyclosporine A: Novel concepts in its role in drug-induced gingival overgrowth. Dent Res J 2015;12:499-506.

Access this article online	
	Website: <a href="http://www.drj.ir">www.drj.ir</a> <a href="http://www.drjjournal.net">www.drjjournal.net</a> <a href="http://www.ncbi.nlm.nih.gov/pmc/journals/1480">www.ncbi.nlm.nih.gov/pmc/journals/1480</a>

develops in the first 6 months of CsA administration and initially appears as a papillary enlargement and is mostly restricted to the keratinized gingiva, but it may grow in size with time and cover the crowns of teeth causing difficulties in mastication, speech, and profound esthetic and psychological problems.<sup>[11]</sup> Despite the intensive studies investigating the cellular and molecular basis of the development of CsA-induced gingival hyperplasia, the exact mechanism underlying this condition is still unclear.<sup>[12]</sup> Various risk factors have been described including age, sex, genetic predisposition, duration of therapy, concomitant medication such as calcium channel blockers and gingival inflammation.<sup>[13]</sup> A recent study suggested that the imbalance between cell proliferation and apoptosis may contribute to the pathogenesis of the hypercellularity observed in CsA-induced gingival hyperplasia.<sup>[14]</sup>

The effect of CsA on proliferation of human gingival fibroblast (HGF) is still controversial ranging from absent to an increase or a decrease.<sup>[15]</sup> However, these discrepancies in studies have been attributed to heterogeneity of the HGF strain used,<sup>[16]</sup> or to differences in the experimental conditions applied.<sup>[17]</sup> Moreover, recent studies suggested that the accumulation of gingival fibroblasts observed in drug-associated gingival hyperplasia resulted from the inhibition of apoptosis.<sup>[14,18]</sup> Furthermore, recent attention has been drawn to the gingival keratinocytes as a potential part of the pathogenesis of CsA-associated gingival hyperplasia. The effect of CsA on gingival keratinocytes is still inconclusive ranging from being pro-proliferative, antiproliferative,<sup>[19]</sup> pro-apoptotic, antiapoptotic,<sup>[20]</sup> or no effect. However, all of these *in vitro* studies were conducted in monolayer cultures that lack the multilayer structure of the *in vivo* epithelium. It has been shown that the pathogenesis of CsA-induced gingival hyperplasia is associated with up-regulated level of salivary contents of proinflammatory cytokines including interleukin (IL) 1 $\alpha$ , IL-8, and IL-6 compared to healthy controls.<sup>[21]</sup> However, there have been no studies on release of these inflammatory cytokines in gingival keratinocytes following treatment with CsA. The clinical observations of the pathogenesis of CsA-induced gingival hyperplasia indicate a potential role for periodontal bacteria in the pathogenesis. However, most of these studies have been undertaken *in vivo*, and the findings are still inconclusive. It is not clear whether accumulation of dental plaque is a consequence of gingival changes caused by the drug

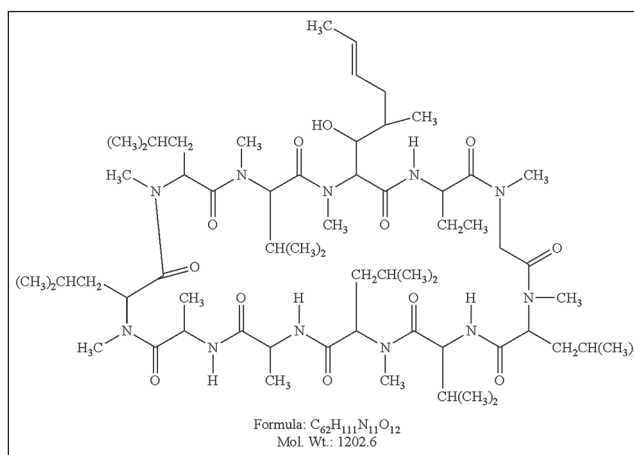
itself, or it is an essential factor for initiating the pathogenesis.<sup>[8]</sup> This difficulty in determining the exact role of gingival inflammation might be related to the complexity of the *in vivo* situation.

Seymour and Smith reported that maintaining adequate oral hygiene in humans markedly reduced the severity of CsA-induced gingival hyperplasia, but it did not prevent the development of the condition.<sup>[22]</sup> Recently, there has been evidence that CsA treatment can modulate the local expression of angiotensin II (Ang II) and up-regulation of angiotensin type 1 (AT1) receptors in gingival fibroblasts and contribute to the role of renin angiotensin axis being stimulated by CsA contributing to the pathogenesis of drug-induced gingival overgrowth.<sup>[23]</sup> However, understanding of the pathogenesis of gingival overgrowth is incomplete at best. Hence, it would be pertinent to identify and explore various possible pathogenesis of drug-induced gingival overgrowth for devising prevention and treatment strategies in susceptible patients.

The present review analyzes the current concepts in pathogenesis of CsA-induced gingival overgrowth.

## CYCLOSPORINE A PHARMACOLOGY

Cyclosporine A [Figure 1] is a neutral, hydrophobic cyclic peptide composed of 11 amino acids (mol. wt. 1202.6), all having the S-configuration of the L-amino acids, with the sole exception of the D-alanine in position 8, which has the R-configuration.<sup>[1]</sup> CsA taken orally in a vehicle such as olive oil enters the circulation where it is distributed and bound to blood components.<sup>[3]</sup> CsA rapidly equilibrates between plasma and red cells, with the establishment of a steady state within 20 min.<sup>[3]</sup> Erythrocytes account for



**Figure 1:** Depicting molecular structure of cyclosporine A.

50% of binding and lymphocytes 4-9%. Of the total amount of CsA in blood, about 5% is free drug, and 25% is bound to blood lipoproteins.

### ROLE OF CYCLOSPORINE IN INHIBITION OF GRAFT REJECTION

Cyclosporine is a selective immunosuppressant with a weak antimicrobial activity<sup>[24]</sup> and can be administered orally, intramuscularly or intravenously.<sup>[25]</sup> The main use of cyclosporine is to prevent graft rejection in organ transplantation. Several studies have shown that cyclosporine selectively acts on the T-lymphocyte response, with little or no action on B lymphocytes.<sup>[26]</sup> The pharmacodynamics of cyclosporine mainly involves the T-cell response. Hence, it is essential to know the role of T-lymphocytes in graft rejection.<sup>[9]</sup> The mechanisms by which the T-lymphocytes reject the graft are shown in Figure 2.

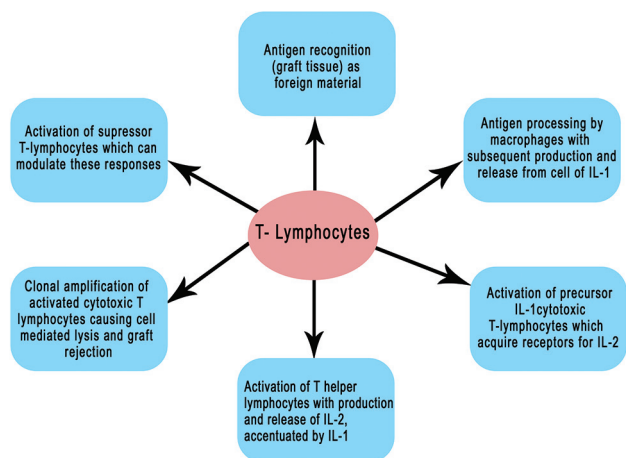
Cyclosporine inhibits many of the stages shown in Figure 2, acting at both the cellular and molecular level.<sup>[27]</sup> At low concentrations (10-20 ng/ml), it inhibits IL-2 synthesis, thereby limiting clonal amplification of cytotoxic T-lymphocytes. At a higher concentration (100 ng/ml), cyclosporine inhibits the ability of cytotoxic T-lymphocytes to respond to IL-2. The mechanism of this inhibition is uncertain but may be due to the drug blocking the induction of IL-2 receptors on these cells. By contrast, cyclosporine has a sparing effect on suppressor T-lymphocytes<sup>[25]</sup> to be resistant to cyclosporine, whereas cytotoxic T-lymphocytes and T-helper cells are sensitive to the drug.<sup>[25]</sup> Within the T-lymphocyte, cyclosporine binds

to several proteins, in particular calmodulin and cyclophilin. It has been postulated that the resistance or sensitivity of T-lymphocytes to cyclosporine may be related to the proportionate intracellular concentrations of calmodulin (involved in activation of T-lymphocytes) and cyclophilin.<sup>[28]</sup> An increase in cyclophilin will increase cyclosporine binding, and thus prevent the drug from interacting with calmodulin. Conversely, low levels of cyclophilin will allow cyclosporine to bind to calmodulin and inhibit its formation and subsequent T-lymphocyte activation.

### CYCLOSPORINE AND GINGIVAL OVERGROWTH

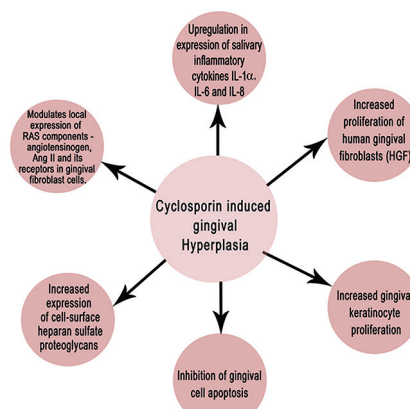
The precise mechanism of cyclosporine-induced gingival overgrowth is uncertain. Various investigations for pathogenesis of gingival overgrowth support the hypothesis that it is multifactorial.<sup>[29]</sup> A possible model is shown in Figure 3.<sup>[30,31]</sup> Cell culture studies have shown that both cyclosporine and cyclosporine metabolites have direct effects on gingival fibroblast proliferation, protein synthesis and collagen production.<sup>[9]</sup> Furthermore, there exists a genetically determined subpopulation of cyclosporine sensitive gingival fibroblasts. Indeed, the terms “responders” and “nonresponders” have appeared in the literature to identify those who show or do not show drug-induced gingival changes.<sup>[32]</sup> Both findings are important in the pathogenesis of cyclosporine-induced gingival overgrowth.

The results from clinical studies suggest that the incidence and severity of gingival overgrowth in



Role of T-lymphocytes in graft rejection

Figure 2: Role of cyclosporine in inhibition of graft rejection: Mechanisms by which the T-lymphocytes reject the graft.



Possible pathways of CsA-induced gingival hyperplasia

Figure 3: Pathogenesis of cyclosporine A-induced gingival overgrowth: Model depicting the various mechanisms by which cyclosporine A causes gingival enlargement.



cyclosporine-treated patients are dependent upon the interaction of several factors. These include plaque control, the level of gingival inflammation, extent of periodontal destruction, the dosage and duration of cyclosporine therapy, plasma and tissue concentrations of the drug and metabolites, age of the patient, and perhaps the underlying medical condition.<sup>[9]</sup>

Cyclosporine-induced gingival overgrowth commences as a papillary enlargement which is more pronounced on the labial aspects of the gingiva than the palatal or lingual surfaces.<sup>[28]</sup> The papillary enlargement increases and adjacent papillae appear to coalesce. This gives the gingival tissues a lobulated appearance [Figure 4].<sup>[13]</sup> Cyclosporine-induced gingival overgrowth has not been reported in edentulous subjects.<sup>[29]</sup> The hyperplastic gingival tissues often show marked inflammatory changes, bleed readily on probing and are generally more hyperemic than the gingival tissue from phenytoin-induced gingival overgrowth.<sup>[9]</sup>

## PATHOGENESIS OF CYCLOSPORINE A-INDUCED GINGIVAL OVERGROWTH

Some authors suggest that there is a significant relationship between amount of time without plaque control and development of gingival overgrowth,<sup>[8]</sup> whereas others believe there is no significant relation between cyclosporine-induced gingival overgrowth and plaque scores.<sup>[22]</sup> It is well-known that the lipopolysaccharide is an important component of bacterial cell wall which is known to be cytotoxic for fibroblasts. There are various concepts highlighting the cause of gingival enlargement due to CsA.

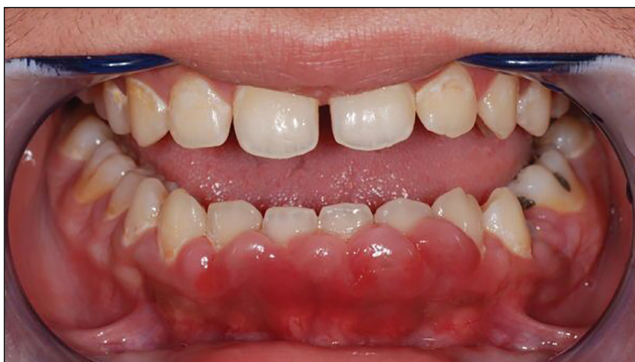### Up-regulation of salivary pro-inflammatory cytokines interleukin (IL-1 $\alpha$ ), IL-8 and IL-6

Cytokines and chemokines such as IL-1 $\alpha$ , IL-1  $\beta$ , IL-6, and IL-8 play a significant role in periodontal

diseases<sup>[33]</sup> and growing attention has been paid to their potential role in the pathogenesis of CsA-induced gingival hyperplasia with conflicting results. It has been observed that incubation of normal and overgrown gingival fibroblasts for 24 h in or with different concentrations of CsA released no detectable amount of IL-1 $\beta$  compared to control, whereas production of IL-6 in all fibroblast strains was suppressed in a dose-dependent manner with the maximal inhibition being reported at 2000 ng/ml CsA.<sup>[34]</sup> This was in contrast to a recent observation which demonstrated that 500 ng/ml CsA up-regulated production of IL-6 and transforming growth factor (TGF)  $\beta$ 1 in HGFs in a time-dependent manner with the maximal release being reported at 24 h.<sup>[35]</sup> But, it has been observed that neutralization of TGF- $\beta$ 1 resulted in a significant reduction in expression of CsA-induced IL-6 while release of CsA-induced TGF- $\beta$ 1 was not affected by blocking IL-6.<sup>[36]</sup> These findings suggest that TGF- $\beta$ 1 is an essential regulator of CsA-induced IL-6 release in HGFs. In addition, it has been reported that HGFs treated with IL-6 or TGF- $\beta$ 1 exhibited an increased rate of proliferation compared to control.<sup>[37]</sup> Furthermore, neutralizing IL-6 and TGF- $\beta$ 1 caused down-regulation of CsA-induced HGF proliferation rate.<sup>[36]</sup> The effect of CsA on IL-1 $\alpha$  and IL-8 has received little direct attention, although it has been suggested that the pathogenesis of CsA-induced gingival hyperplasia may involve alteration in the expression levels of various inflammatory cytokines in the gingiva.<sup>[21]</sup> It has been observed that an increase in the salivary levels of IL-1 $\alpha$ , IL-6, and IL-8 in patients with CsA-induced gingival hyperplasia occurs.<sup>[21,34]</sup> Up-regulation of these cytokines thus have a direct effect in causing gingival hyperplasia.

### Increase in proliferation of human gingival fibroblasts

Long-term exposure to CsA may have a stimulatory effect on gingival fibroblast proliferation.<sup>[10]</sup> Bartold<sup>[15]</sup> observed that 10-9 g/ml CsA up-regulated DNA synthesis and the proliferation rate of HGF with most noticeable stimulation being reported in the presence of 10% fetal bovine serum (FBS), and that this capacity was retained even in absence of FBS or in the presence of lipopolysaccharide that usually inhibit proliferation of these cells. In the agreement with Bartold's findings, Chae *et al.*<sup>[35]</sup> also showed that treatment of serum starved HGFs with CsA (100 and 500 ng/ml) for 6 days significantly



**Figure 4:** Clinical presentation of cyclosporine A-induced gingival overgrowth.

activated the cell cycle along with an increase in the cell viability and DNA incorporation. These findings were also in agreement with a flow cytometric study that showed an increase in the *in vitro* proliferative activity of CsA-treated HGF illustrated by a promoted progression of cell cycle and an increase in the expression level of cyclin B1.<sup>[37]</sup> It was recently observed that CsA up-regulated cell viability in HGF cell lines with a maximal increase being found in HGF cells obtained from CsA-induced overgrown gingival tissues.<sup>[38]</sup> Interestingly, a bimodal effect of CsA on proliferation of HGFs has been observed when cultured for 24 h; low doses of CsA ( $\leq 200$  ng/ml) stimulated HGF proliferation, whilst higher doses of CsA (400-800 ng/ml) inhibited proliferation of these cells.<sup>[36]</sup> In contrast to the previous findings, it was observed that long-term exposure to a low dose of CsA (200 ng/ml) had no effect on viability and proliferation of HGFs.<sup>[39]</sup> While extremely high doses of CsA (5-10 g/ml) induced a significant decrease in HGF proliferation.<sup>[37]</sup> Furthermore, *in vitro* 24 h stimulation with CsA failed to induce an increase in HGF proliferation.<sup>[18]</sup> However, these discrepancies between studies could be attributed to heterogeneity of cell line strains or to differences in the experimental conditions.

#### Effect on human gingival keratinocytes

It has been reported that the release of both keratinocyte growth factor and scatter factor (SF) was increased in both normal and overgrowth gingival fibroblast strains treated with 2000 ng/ml CsA. It was observed that normal gingival epithelial cells incubated with 500 ng/ml CsA for 3 days expressed higher levels of keratinocyte growth factor receptor (KGFR) compared to control. Thus, increased level in KGFR is consistent with the increase in proliferation rate of epithelial cells observed in CsA-induced gingival hyperplasia.<sup>[40]</sup>

Yoshida *et al.* assessed proliferation of cultured rat gingival cells after incubation for 3 days and showed that CsA at concentration of 200-800 ng/ml induced hyperproliferation of gingival cells by 23-25% compared to control.<sup>[41]</sup> These findings were supported by an animal study that showed that treatment with CsA caused buccal epithelial hyperplasia associated with an increase in proliferating cell nuclear antigen (PCNA) expression. It was suggested that CsA-induced gingival hyperplasia might be mediated by an increase in the proliferative activity of epithelium cells and that dental plaque might aggravate

the condition.<sup>[37]</sup> Similarly, it was demonstrated immunohistochemically that the epithelial hyperplasia reported in CsA-induced gingival hyperplasia was associated with hyperproliferation in both sulcular and oral gingival epithelium with a maximal proliferative activity being observed in the oral gingival epithelium.<sup>[40]</sup> However, conflicting data were also found through an animal study that showed the increase in the epithelial thickness observed in CsA-induced gingival hyperplasia was associated with an increase in cyclin D1 and PCNA expression.<sup>[41]</sup> Flow cytometric study on human oral epidermoid carcinoma cell lines showed that CsA caused a cell cycle stasis.<sup>[19,20]</sup> Interestingly, both the inhibitory and stimulatory effect of CsA on human gingival keratinocyte proliferation has been observed where CsA significantly reduced their proliferation rate from day 3 to day 6 and then stimulated their proliferation from day 6 to day 9 with maximal increase being observed on day 9 at a concentration of 1,000 ng/ml.<sup>[40]</sup>

#### Overexpression of noncollagenous extracellular matrix proteins like heparan sulfate proteoglycans

There has been considerable interest on the effect of CsA on the extracellular matrix of gingival tissues. It has been observed that there are alterations in gene expression of extracellular matrix proteoglycans in CsA-induced gingival tissue alterations. CsA-induced gingival overgrowth seems to be associated with increased expression of perlecan, a typical basement membrane proteoglycan but not decorin, biglycan or versican.<sup>[42]</sup> Recently, the gene expression of cell surface heparin sulfate proteoglycans syndecan-2, syndecan-4, and betaglycan was observed in gingival tissues of transplant patients exposed to CsA. It was observed there was a high expression of noncollagenous extracellular matrix proteoglycans syndecan-4 and syndecan-2.<sup>[42]</sup>

#### Stimulation of the renin angiotensin axis

The renin angiotensin system (RAS) is considered as a hormonal circulatory system involved in maintaining blood pressure, electrolyte, and fluid homeostasis. RAS components can be synthesized in local tissues and are found to play a role in gingival overgrowth. Recently, its role has been implicated in causing drug-induced gingival overgrowth. The expression of Ang II and its receptors was observed in gingival fibroblast cells treated with cyclosporine. Ang II mRNA and protein expression was significantly higher in patients with drug-induced gingival enlargement

than in patients with periodontitis and healthy subjects. The angiotensin II receptor type I (AT1) mRNA was expressed more than AT2 in all examined tissues. In gingival fibroblasts, Ang II and AT1 expressions were increased with cyclosporine incorporation compared to controls.<sup>[23]</sup> It was thus suggested that cyclosporine can modulate local expression of RAS components such as the angiotensinogen, Ang II, and its receptors in gingival tissues and gingival fibroblast cells.

#### Effect of cyclosporine A on gingival cell apoptosis

Apoptosis, programmed cell death, is stimulated mainly by two characteristic pathways: An extrinsic pathway that is mediated by death receptor (tumor necrosis factor- $\alpha$ ) and an intrinsic or mitochondrial pathway that is regulated by pro-apoptotic proteins such as Bax and Bid and antiapoptotic proteins like Bcl-2. Both pathways are executed by a key component referred to as caspase-3 that is activated after being cleaved, leading in the end to cell apoptosis.<sup>[43]</sup> It has been observed that the increased number in HGF in CsA-induced gingival hyperplasia was the result of reduced apoptosis coupled with increased proliferative activity.<sup>[14]</sup> Further, *in vitro* studies revealed that stimulation of HGF with CsA for 24 h caused a significant decrease in apoptosis rate through both the intrinsic and extrinsic pathways suggesting that the decreased level of apoptosis might play a more significant effect than the increase in cell proliferation in increasing the HGF number.<sup>[15,18,20]</sup> Recently, it was reported that CsA increased the cell viability of HGF cultures *in vitro* and this increase was resulted from a reduced apoptosis, illustrated by reduced expression Bax/Bcl-2 ratio, rather than increased cell proliferation.<sup>[18]</sup>

## PREVENTION AND TREATMENT OF DRUG-INDUCED GINGIVAL ENLARGEMENT

### Prevention

In the susceptible patient, drug-associated gingival enlargement may be ameliorated but not prevented by elimination of local factors, meticulous plaque control, and regular periodontal maintenance therapy. The 3-6 month interval for periodontal maintenance therapy has been recommended for patients taking drugs associated with gingival enlargement.<sup>[30]</sup> Each recall appointment should include detailed oral hygiene instructions and thorough prophylaxis with supra and subgingival calculus removal as needed. It is important that the

dental professional encourage improved tooth cleaning in a supportive and positive manner, as well as providing information about the role of dental plaque in promoting gingival overgrowth. Mild gingival enlargement will often diminish with removal of plaque and calculus deposits. Even moderate gingival enlargement may reduce enough to avoid surgical intervention. Attempts at improving oral hygiene are of limited benefit in severe gingival enlargement, as surgical gingival excision is generally indicated.<sup>[44]</sup>

## TREATMENT

### Drug substitution or withdrawal

The most effective treatment of drug-related gingival enlargement is withdrawal or substitution of medication. Many cases of gingival enlargement will respond to local treatment, but consideration should be given to altering the medication if gingival enlargement covers more than about a third of the tooth surface. When possible, reducing the dose or changing to another drug may bring about partial or complete regression of the lesion. Most patients will observe an alteration in the soft tissues within a few days.<sup>[31]</sup> When this treatment approach is taken as suggested by another case report, it may take from 1 to 8 weeks for resolution of gingival lesions.<sup>[32]</sup> Unfortunately, not all patients respond to this mode of treatment, especially those with long-standing gingival overgrowth.<sup>[28]</sup>

### Nonsurgical treatment

Mild gingival enlargement may only require local management as improvement in oral hygiene, together with professional cleaning of the teeth, can lead to resolution of inflammation and reduction in gingival enlargement. Professional debridement with scaling and root planing as needed has been shown to offer some relief in gingival overgrowth patients.<sup>[30]</sup> Treatment planning becomes more complex where there is periodontitis associated with gingival enlargement, which poses a cosmetic or functional problem. Periodontitis alone can be treated using conventional clinical care, but when associated with the gingival enlargement, may require changes in the medication regimen, periodontal surgery (flap technique) pocket elimination along with removal of excess tissue, or a combination of the two.<sup>[44]</sup>

### Surgical periodontal treatment

Since the anterior labial gingiva is frequently involved, surgery is commonly performed for esthetic reasons before any functional consequences are



present. The classical surgical approach has been the external bevel gingivectomy.<sup>[31]</sup> However, the total or partial internal gingivectomy approach has been suggested as an alternative.<sup>[44]</sup> This is a more technically demanding approach, which has the benefit of limiting a large denuded connective tissue wound that results from the external gingivectomy, thereby minimizing postoperative inflammation, pain and bleeding. The use of electrocautery and carbon dioxide lasers has shown some utility for reducing gingival enlargement, an approach which provides rapid postoperative hemostasis.<sup>[31]</sup> Consultation with the patient's physician prior to surgical treatment regarding antibiotic and steroid coverage should take place in the immune suppressed patient.<sup>[44]</sup>

## CONCLUSION

Gingival overgrowth is a side effect of the long-term administration of cyclosporine and may also be influenced by other predisposing factors, like bacterial plaque. It needs to be emphasized that elimination of local factors followed by thorough maintenance has a definitive significant inhibitory effect on gingival overgrowth. Surgical treatment to excise and remodel the gingival contour should be considered whenever gingival overgrowth causes esthetic and functional problems.

Understanding the various mechanisms, underlying the pathogenesis of cyclosporine-induced gingival overgrowth, will help the clinician devise better prevention strategies in patients susceptible to gingival overgrowth. Hence, it would be pertinent to identify and explore possible risk factors relating to both prevalence and severity of drug-induced gingival overgrowth. Newer molecular approaches are needed to clearly establish the pathogenesis of gingival overgrowth and to provide novel information for the design of future preventive and therapeutic modalities.

## ACKNOWLEDGMENTS

We would like to thank SRM Dental College, Ramapuram, Chennai and SRM University for supporting this work.

### Financial support and sponsorship

Nil.

### Conflicts of interest

The authors of this manuscript declare that they have no conflicts of interest, real or perceived, financial or non-financial in this article.

## REFERENCES

1. Borel JF. The history of cyclosporine-A and its significance. In: White DJ, editor. Cyclosporin A: Proceedings of an International Conference on Cyclosporine A. 3<sup>rd</sup> ed. Cambridge: Elsevier; 1982. p. 5-17.
2. Condé SA, Aarestrup FM, Vieira BJ, Bastos MG. Roxithromycin reduces cyclosporine-induced gingival hyperplasia in renal transplant patients. *Transplant Proc* 2008;40:1435-8.
3. Faulds D, Goa KL, Benfield P. Cyclosporin. A review of its pharmacodynamic and pharmacokinetic properties, and therapeutic use in immunoregulatory disorders. *Drugs* 1993;45:953-1040.
4. Chang SH, Lim CS, Low TS, Chong HT, Tan SY. Cyclosporine-associated encephalopathy: A case report and literature review. *Transplant Proc* 2001;33:3700-1.
5. Galán AI, Fernández E, Morán D, Muñoz ME, Jiménez R. Cyclosporine A hepatotoxicity: Effect of prolonged treatment with cyclosporine on biliary lipid secretion in the rat. *Clin Exp Pharmacol Physiol* 1995;22:260-5.
6. Woolfson RG, Neild GH. Cyclosporin nephrotoxicity following cardiac transplantation. *Nephrol Dial Transplant* 1997;12:2054-6.
7. Textor SC, Canzanello VJ, Taler SJ, Wilson DJ, Schwartz LL, Augustine JE, *et al.* Cyclosporine-induced hypertension after transplantation. *Mayo Clin Proc* 1994;69:1182-93.
8. Seymour RA, Ellis JS, Thomason JM. Risk factors for drug-induced gingival overgrowth. *J Clin Periodontol* 2000;27:217-23.
9. Seymour RA, Jacobs DJ. Cyclosporin and the gingival tissues. *J Clin Periodontol* 1992;19:1-11.
10. Kataoka M, Kido J, Shinohara Y, Nagata T. Drug-induced gingival overgrowth — A review. *Biol Pharm Bull* 2005;28:1817-21.
11. Marshall RI, Bartold PM. A clinical review of drug-induced gingival overgrowths. *Aust Dent J* 1999;44:219-32.
12. Guo J, Wang W, Yao L, Yan F. Local inflammation exacerbates cyclosporine A-induced gingival overgrowth in rats. *Inflammation* 2008;31:399-407.
13. Bartoli F, Castronovo G, Stabile A. Risk factors conditioning the incidence and severity of cyclosporine A-induced gingival overgrowth and methods of prevention. *Minerva Stomatol* 2004;53:165-70.
14. Kantarci A, Augustin P, Firatli E, Sheff MC, Hasturk H, Graves DT, *et al.* Apoptosis in gingival overgrowth tissues. *J Dent Res* 2007;86:888-92.
15. Bartold PM. Regulation of human gingival fibroblast growth and synthetic activity by cyclosporine — A *in vitro*. *J Periodontal Res* 1989;24:314-21.
16. Hassell TM, Stanek EJ 3<sup>rd</sup>. Evidence that healthy human gingiva contains functionally heterogeneous fibroblast subpopulations. *Arch Oral Biol* 1983;28:617-25.
17. Leonardi A, DeFranchis G, Fregona IA, Violato D, Plebani M, Secchi AG. Effects of cyclosporin A on human conjunctival fibroblasts. *Arch Ophthalmol* 2001;119:1512-7.
18. Jung JY, Jeong YJ, Jeong TS, Chung HJ, Kim WJ. Inhibition of apoptotic signals in overgrowth of human gingival fibroblasts by cyclosporin A treatment. *Arch Oral Biol* 2008;53:1042-9.

19. Tu HP, Fu E, Chen YT, Wu MH, Cheng LC, Yang SF. Expression of p21 and p53 in rat gingival and human oral epithelial cells after cyclosporine A treatment. *J Periodontal Res* 2008;43:32-9.
20. Tu HP, Chen YT, Chiu HC, Chin YT, Huang SM, Cheng LC, *et al.* Cyclosporine A enhances apoptosis in gingival keratinocytes of rats and in OECM1 cells via the mitochondrial pathway. *J Periodontal Res* 2009;44:767-75.
21. Ruhl S, Hamberger S, Betz R, Sukkar T, Schmalz G, Seymour RA, *et al.* Salivary proteins and cytokines in drug-induced gingival overgrowth. *J Dent Res* 2004;83:322-6.
22. Seymour RA, Smith DG. The effect of a plaque control programme on the incidence and severity of cyclosporin-induced gingival changes. *J Clin Periodontol* 1991;18:107-10.
23. Subramani T, Senthilkumar K, Periasamy S, Rao S. Expression of angiotensin II and its receptors in cyclosporine-induced gingival overgrowth. *J Periodontal Res* 2013;48:386-91.
24. Borel JF, Feurer C, Gubler HU, Stähelin H. Biological effects of cyclosporin A: A new antilymphocytic agent. *Agents Actions* 1976;6:468-75.
25. Beveridge T, Gratwohl A, Michot F. Cyclosporine A: Pharmacokinetics after a single dose in man and serum levels after multiple dosing in recipients of allogenic bone marrow grafts. *Curr Ther Res* 1981;30:5-10.
26. Britton S, Palacios R. Cyclosporin A — Usefulness, risks and mechanism of action. *Immunol Rev* 1982;65:5-22.
27. Hegde R, Kale R, Jain S. Cyclosporine and amlodipine induced severe gingival overgrowth-etiopathogenesis and management of a case with electrocautery and carbon-dioxide(CO2) laser. *J Oral Health Commun Dent* 2012;6:34-42.
28. Seymour RA, Thomason JM, Ellis JS. The pathogenesis of drug-induced gingival overgrowth. *J Clin Periodontol* 1996;23:165-75.
29. Friskopp J, Klintmalm G. Gingival enlargement. A comparison between cyclosporine and azathioprine treated renal allograft recipients. *Swed Dent J* 1986;10:85-92.
30. Hall EE. Prevention and treatment considerations in patients with drug-induced gingival enlargement. *Curr Opin Periodontol* 1997;4:59-63.
31. Grover V, Kapoor A, Marya CM. Amlodipine induced gingival hyperplasia. *J Oral Health Commun Dent* 2007;1:19-22.
32. Tyldesley WR, Rotter E. Gingival hyperplasia induced by cyclosporin-A. *Br Dent J* 1984;157:305-9.
33. Okada H, Murakami S. Cytokine expression in periodontal health and disease. *Crit Rev Oral Biol Med* 1998;9:248-66.
34. Myrillas TT, Linden GJ, Marley JJ, Irwin CR. Cyclosporin A regulates interleukin-1beta and interleukin-6 expression in gingiva: Implications for gingival overgrowth. *J Periodontol* 1999;70:294-300.
35. Chae HJ, Ha MS, Yun DH, Pae HO, Chung HT, Chae SW, *et al.* Mechanism of cyclosporine-induced overgrowth in gingiva. *J Dent Res* 2006;85:515-9.
36. Cotrim P, Martelli-Junior H, Graner E, Sauk JJ, Coletta RD. Cyclosporin A induces proliferation in human gingival fibroblasts via induction of transforming growth factor-beta1. *J Periodontol* 2003;74:1625-33.
37. Parkar MH, Hussain F, Wickramaratna A, Olsen I. The immunosuppressant and hyperplasia-inducing drug cyclosporin A regulates the cell cycle and cyclin B1 gene expression in gingival fibroblasts *in vitro*. *Cell Tissue Res* 2004;317:221-5.
38. Kim JY, Park SH, Cho KS, Kim HJ, Lee CK, Park KK, *et al.* Mechanism of azithromycin treatment on gingival overgrowth. *J Dent Res* 2008;87:1075-9.
39. Yamaguchi M, Naruishi K, Yamada-Naruishi H, Omori K, Nishimura F, Takashiba S. Long-term cyclosporin A exposure suppresses cathepsin-B and-L activity in gingival fibroblasts. *J Periodontal Res* 2004;39:320-6.
40. Hyland PL, McKeown ST, Mackenzie IC, Irwin CR. Regulation of keratinocyte growth factor and scatter factor in cyclosporin-induced gingival overgrowth. *J Oral Pathol Med* 2004;33:391-7.
41. Yoshida T, Nagata J, Yamane A. Growth factors and proliferation of cultured rat gingival cells in response to cyclosporin A. *J Periodontal Res* 2005;40:11-9.
42. Gnoatto N, Lotufo RF, Matsuda M, Penna V, Marquezini MV. Expression of cell-surface heparan sulfate proteoglycans in human cyclosporin-induced gingival overgrowth. *J Periodontal Res* 2007;42:553-8.
43. Fulda S, Debatin KM. Extrinsic versus intrinsic apoptosis pathways in anticancer chemotherapy. *Oncogene* 2006;25:4798-811.
44. Barbara AT. Management of drug-induced gingival enlargement. *Aust Prescriber* 2003;26:11-3.