

## Original Article

# A randomized controlled evaluation of alveolar ridge preservation following tooth extraction using deproteinized bovine bone mineral and demineralized freeze-dried bone allograft

Rokhsareh Sadeghi<sup>1</sup>, Maryam Babaei<sup>2</sup>, S. Asghar Miremadi<sup>3</sup>, Fatemeh Mashadi Abbas<sup>4</sup>

<sup>1</sup>Department of Periodontics, Faculty of Dentistry, Shahed University, Tehran, <sup>2</sup>Department of Periodontics, Faculty of Dentistry, Zanzan University of Medical Sciences, Zanzan, <sup>3</sup>Department of Periodontics, Faculty of Dentistry, Tehran University of Medical Sciences, <sup>4</sup>Department of Oral and Maxillofacial Pathology, Faculty of Dentistry, Shahid Beheshti University of Medical Sciences, Tehran, Iran

## ABSTRACT

**Background:** Alveolar ridge preservation could be performed immediately following tooth extraction to limit dimensional changes of alveolar process due to bone resorption. The aim of this study was to compare the clinical and histologic outcomes of socket preservation using two different graft materials; deproteinized bovine bone mineral (DBBM) and demineralized freeze-dried bone allograft (DFDBA) with absorbable collagen membrane.

**Materials and Methods:** Twenty extraction sockets in 20 patients were randomly divided into 2 treatment groups: 10 sockets were augmented with DBBM and collagen membrane whereas 10 sockets were filled with DFDBA and covered by collagen membrane. Primary closure was achieved over extraction sockets by flap advancement. Horizontal and vertical ridge dimensional changes were assessed at baseline and after 4–6 months at the time of implant placement. For histological and histomorphometrical analysis, bone samples were harvested from the augmented sites with trephine during implant surgery. All data were analyzed using SPSS version 18 ( $\alpha=0.05$ ).

**Results:** Clinical measurements revealed that average horizontal reduction was  $2.3 \pm 0.64$  mm for DFDBA and  $2.26 \pm 0.51$  mm for DBBM. Mean vertical ridge resorption at buccal side was  $1.29 \pm 0.68$  mm for DFDBA and  $1.1 \pm 0.17$  mm for DBBM. Moreover, mean vertical ridge reduction at lingual site was  $0.41 \pm 0.38$  mm and  $0.35 \pm 0.34$  mm for DFDBA and DBBM, respectively. No significant differences were seen between two groups in any of those clinical parameters. Histologic analysis showed statistically significant more new bone deposition for DFDBA compared to DBBM ( $34.49 \pm 3.19$  vs.  $18.76 \pm 3.54$ ) ( $P < 0.01$ ). Residual graft particles were identified significantly more in DBBM ( $12.77 \pm 1.85$ ) than DFDBA ( $6.06 \pm 1.02$ ).

**Conclusion:** Based on the findings of this study, both materials have positive effect on alveolar ridge preservation after tooth extraction, but there was more new bone formation and less residual graft particles in DFDBA group than in DBBM group.

**Key Words:** Collagen, membrane, extraction, socket, graft, material, preservation

Received: April 2015  
Accepted: December 2015

### Address for correspondence:

Dr. Maryam Babaei,  
Department of Periodontics,  
Faculty of Dentistry,  
Zanzan University of Medical  
Sciences, Zanzan, Iran.  
E-mail: m.babaei@  
zums.ac.ir

### Access this article online



Website: [www.drj.ir](http://www.drj.ir)  
[www.drjournal.net](http://www.drjournal.net)  
[www.ncbi.nlm.nih.gov/pmc/journals/1480](http://www.ncbi.nlm.nih.gov/pmc/journals/1480)

This is an open access article distributed under the terms of the Creative Commons Attribution-NonCommercial-ShareAlike 3.0 License, which allows others to remix, tweak, and build upon the work non-commercially, as long as the author is credited and the new creations are licensed under the identical terms.

**For reprints contact:** [reprints@medknow.com](mailto:reprints@medknow.com)

**How to cite this article:** Sadeghi R, Babaei M, Miremadi SA, Abbas FM. A randomized controlled evaluation of alveolar ridge preservation following tooth extraction using deproteinized bovine bone mineral and demineralized freeze-dried bone allograft. *Dent Res J* 2016;13:151-9.

## INTRODUCTION

Tooth extraction often results in alveolar ridge resorption with substantial reduction in height and width of the alveolar bone. The extent of resorption may be affected by several factors, for example, the number of bony socket walls, bone density, severity of periodontal bone loss, the presence of infection, and the absence of adjacent teeth.<sup>[1-5]</sup> Alveolar bone remodeling and resorption after tooth extraction is considerably greater at buccal plate than at lingual plate of both maxilla and mandible.<sup>[6]</sup> In addition, it has been reported that 50% reduction in the bucco-lingual width of postextraction sites will occur after 12 months.<sup>[7]</sup> Frequently, the resorbed ridge cannot properly accommodate root form dental implants.<sup>[8]</sup> Decreased dimensions of the ridge may result in the insertion of shorter and narrower implant, which may influence long-term function and stability of the implant supported restoration.<sup>[9]</sup> Furthermore, it may inhibit the placement of an implant in a prosthetically and esthetically acceptable location.<sup>[10]</sup>

When immediate implant placement is not indicated, socket preservation is a method of choice used to minimize the dimensional changes in soft and hard tissues after tooth extraction.

For this purpose, different graft materials and techniques have been introduced.<sup>[1-3,11-16]</sup> A number of studies have used guided bone regeneration technique for ridge preservation and reported that the technique can preserve the ridge dimensions more predictably than natural healing does.<sup>[1-3,13,14,17]</sup> However, using graft materials in extraction sockets can result in remaining nonvital graft particles,<sup>[3,8,14-20]</sup> which may interfere with the normal healing process of sockets in which dental implants have to be inserted.<sup>[14-16,21]</sup>

It is not known whether implants inserted in residual graft particles will show long-term success or not, but most clinicians prefer placing implants into vital bone.<sup>[21]</sup> Therefore, a material which can preserve ridge dimension and also promote socket fill with vital bone will be the most acceptable one. The primary objective of this randomized clinical trial was to assess horizontal and vertical ridge changes following socket preservation using resorbable collagen membrane and two different graft materials; deproteinized bovine bone mineral (DBBM) and demineralized freeze-dried bone allograft (DFDBA); the second objective was to evaluate healing of the grafted sockets via histologic and histomorphometric analysis.

## MATERIALS AND METHODS

The research protocol of this randomized controlled study was approved by the Ethical Committee of Shahed University, Tehran, Iran, and was registered in Iranian Registry of Clinical Trials (IRCT) with registry code: IRCT2013080414270N1. Twenty-five teeth scheduled for extraction were selected in 25 patients; 17 females and 8 males with mean age of 35.35 years (age range from 21 to 62 years). Patients were chosen from the individuals looking for tooth extraction and implant therapy at the Departments of Periodontology and Implantology, Faculty of Dentistry, Shahed University, Tehran, Iran They were included in this study based on the following criteria:

- Single rooted teeth with hopeless prognosis
- Buccal plate with 2 mm and more dehiscence or thickness <1 mm.

The exclusion criteria were consisted of any systemic disease or medication that interfered with bone healing (such as diabetes, autoimmune diseases, prolonged corticosteroids therapy, or chemotherapy), smoking, allergic reaction, and current pregnancy.

Before entering the study, patients were given an explanation of the nature of the investigation and they signed an informed consent form. Patients were randomly allocated to one of the treatment groups (DFDBA or DBBM) by a computer-generated randomization list.

### Clinical measurements

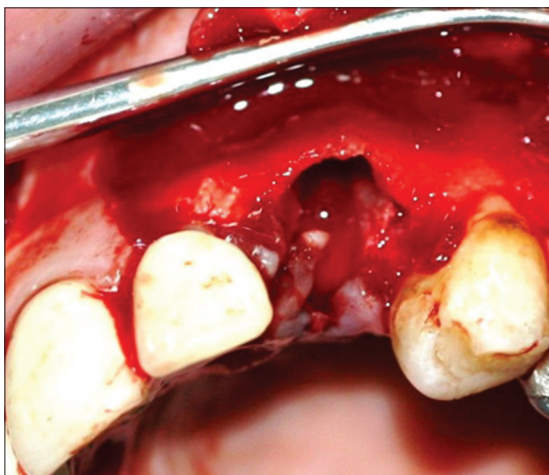
A comprehensive periodontal examination was performed and oral hygiene instructions were given for all patients. Periapical/panoramic radiographs, clinical photographs, and study cast were taken. In cases with abscess formation, systemic antibiotics including amoxicillin and metronidazole were given 1 week prior to extraction. Customized acrylic stents were fabricated on study casts to serve as fixed reference guides for measurement of vertical and horizontal dimensional changes of alveolar ridge. A narrow vertical notch was prepared on both sides of the stent along the midpoint of the extraction socket. The following clinical parameters were assessed: (1) Horizontal measurement which was the distance from coronal border of buccal aspect to the coronal border of the lingual/palatal aspect of the alveolus or ridge at midpoint. This measurement was performed with a caliper to the nearest tenth of millimeter; (2) vertical measurements, (a) the distance between the most coronal point of buccal side of the socket

or ridge and the most apical end of the stent at the place of its notch, and (b) similar measurement at lingual/palatal aspect. Michigan-O-probe with William marking was used to determine vertical measurements.

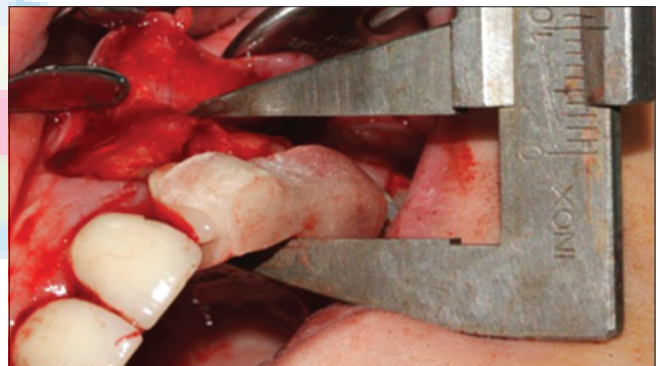
### Surgical procedures

Following administration of local anesthesia, sulcular incision was made around tooth to be extracted and two adjacent teeth on buccal and palatal/lingual sides. On buccal side, two vertical incisions were made at mesial and distal papilla of the adjacent teeth. These incisions were extended beyond mucogingival junction. After full-thickness flap reflection on buccal and lingual sides, atraumatic tooth extraction using periosteal elevator was performed. Sockets were debrided with curette to remove all granulation tissues and periradicular lesions [Figure 1]. The periosteum of buccal flap was incised; this would allow coronal advancement of facial flap and a tension-free primary

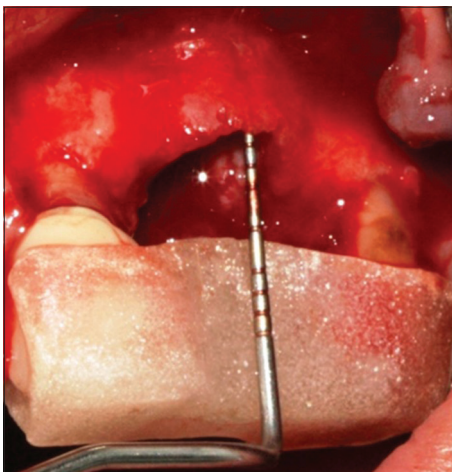
closure. Acrylic stent was placed on neighboring teeth, and then measurements were recorded as described before [Figures 2 and 3]. Extraction sockets were divided into two treatment groups randomly and were grafted with DFDBA (CenoBone<sup>®</sup>; Tissue Regeneration Corporation, Kish Island, Iran) or DBBM (Bio-Oss<sup>®</sup>; Geistlich Pharma AG, Wollhusen, Switzerland). Collagen membrane (Bio-Gide<sup>®</sup>; GeistlichPharma) was trimmed and placed over the grafted socket and alveolar bone in both groups [Figure 4]. Each material was applied according to the manufacturer's instructions. Buccal and lingual/palatal flaps were approximate using interrupted simple loop and vertical mattress sutures. Patients were visited weekly until suture removal which was 14 days after surgery. After that, they were visited monthly. Postsurgical medication consisted of amoxicillin 500 mg every 8 h for 1 week, 400 mg ibuprofen every 6 h, if needed, and 0.2% chlorhexidine mouth rinse twice a day for 3 weeks. Patients scheduled for dental implant surgery 4–6 months after the first surgery. At this stage, full-thickness buccal



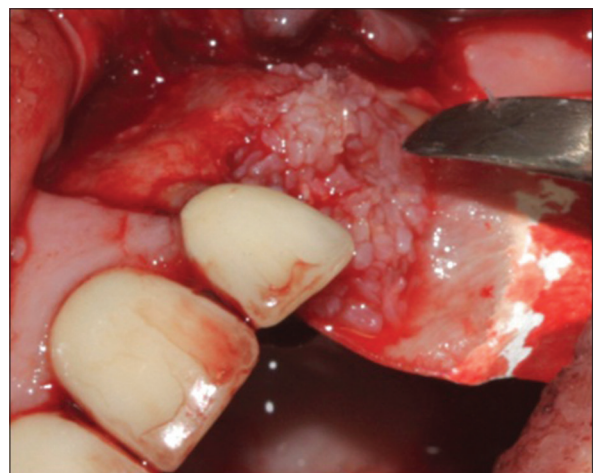**Figure 1:** Occlusal view after atraumatic extraction of canine tooth. The socket was debrided with curette to remove all granulation tissues and periradicular lesion.



**Figure 3:** Horizontal measurement.



**Figure 2:** Vertical measurements with acrylic stent in place.



**Figure 4:** The socket was grafted with demineralized freeze-dried bone allograft and trimmed collagen membrane covered the socket and buccal bone.



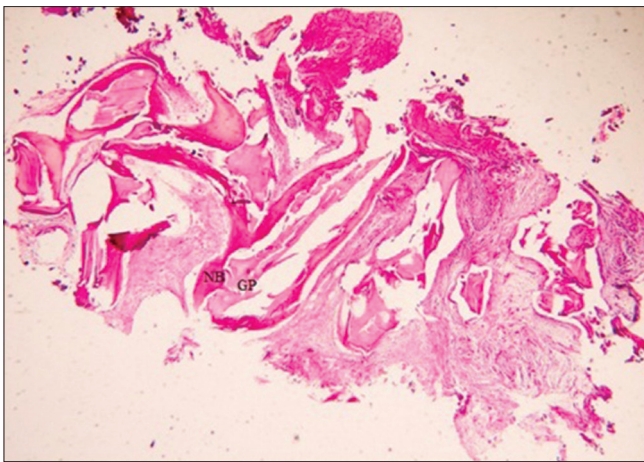
and palatal/lingual mucoperiosteal flaps were elevated. Clinical measurements were recorded similar to the first surgery. An osseous core (2 mm × 6 mm) was obtained from the center of the grafted socket using a trephine with a 2 mm inner and 3 mm outer diameter. The implant osteotomy was completed afterward and the implant was inserted.

For histological and histomorphometrical evaluation, the harvested bone specimens were fixed in 10% buffered formalin then decalcified in 10% formic acid for 2 days. The blocks were processed and sectioned in 4 µm thick serial longitudinal sections through central part of core specimens, then stained with hematoxylin and eosin. The sections were analyzed by a single examiner blinded to the type of treatment. Histomorphometric analysis was performed

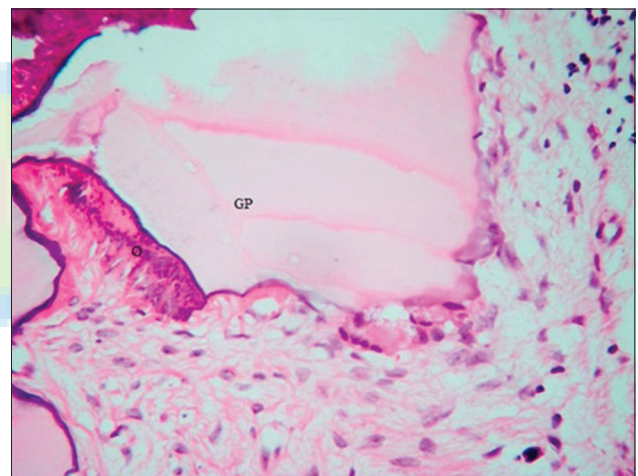
under optic microscopy (magnification ×40) with image analysis software (Iranian HistoMorpho Meter, IHMM, Version 1.0, SBMU, Iran). At least three randomly selected fields, 1 per section for each patient were used to calculate the percentage of lamellar bone and woven bone, and residual graft particles. In addition, the number and percentage of sockets with different amount of inflammation and two types of bone marrow (fibro-vascular or fatty-vascular/fibrous) were assessed [Figures 5-8].

### Statistical analysis

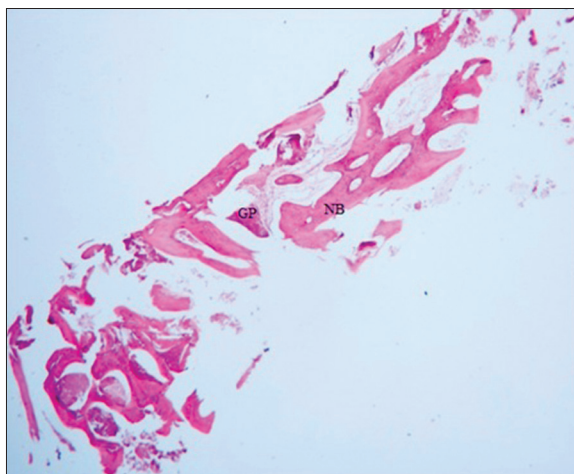
In this study, Shapiro–Wilk and Levene’s tests were used to assess the normal distribution of the values and equality of variances, respectively. Statistical significance of differences between two treatment groups for horizontal and vertical measurements, woven and lamellar bone, and residual graft particles were analyzed using *t*-test and Mann–Whitney U-test. For comparing qualitative variables (bone marrow and inflammation)



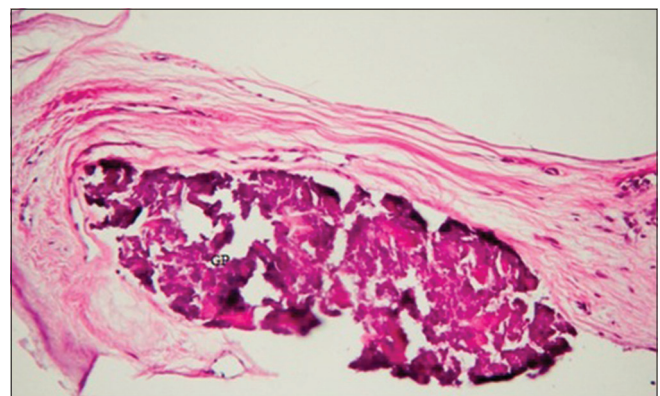
**Figure 5:** Section from a deproteinized bovine bone mineral site specimen. Newly formed bone (NB) and residual graft particles (GP) were present (×40).



**Figure 7:** Calcifying osteoid (O) in close contact with residual graft particles (GP) of deproteinized bovine bone mineral (×400).



**Figure 6:** Section from a demineralized freeze-dried bone allograft site specimen. Newly formed bone (NB) and residual graft particles (GP) were present (×40).



**Figure 8:** Residual graft particles (GP) of demineralized freeze-dried bone allograft in the proximity of the fatty vascular connective tissue (×400).

between two groups, Fisher's exact test was used. Type I error was set at 0.05 and all analyses were done using SPSS version 18 (SPSS Inc., Chicago, IL, USA).

## RESULTS

Twenty-five patients completed the socket preservation surgery. Five patients refused to continue the research protocol due to lack of compliance with the scheduled appointments and did not take part in the implant placement surgery. Twenty patients (14 women, 6 men, mean age 35.5, and age range 21–62 years) completed the study. Surgical procedures were performed without complications and the postsurgical healing phase was uneventful. Horizontal ridge changes are shown in Table 1. Horizontal measurements revealed that in DFDBA group, 29.75% ± 2.61 reduction in ridge width occurred between baseline and 4–6 months postsocket preservation. Similarly, DBBM group showed 28.58% ± 1.82 reduction in ridge width from baseline to final. The difference in ridge width between baseline and postextraction was statistically significant in each group, but there was no statistically significant difference between two groups in this regard ( $P = 0.878$ ). Vertical measurements at baseline and 4–6 months postsurgery showed 1.29 ± 0.68 mm (23.91% ± 4.55) and 1.1 ± 0.17 mm (18.02% ± 1.58) reductions in ridge height at buccal aspect in DFDBA and DBBM groups, respectively. These values were 0.41 ± 0.38 mm (7.84% ± 2.3) and 0.35 ± 0.34 mm (5.83% ± 1.71) at lingual side [Table 2]. The differences in vertical height reduction between baseline and postextraction were statistically significant in each group. Although this reduction was greater in both buccal and palatal/lingual sides in DFDBA group than in DBBM group, there were no statistically significant differences in these values between two groups.

### Histologic and histomorphometric evaluation

All sections showed bone formation that included lamellar bone and woven bone [Table 3]. The average amount of lamellar bone was higher in DFDBA group than in the DBBM group, but the difference was not statistically significant ( $P = 0.101$ ). New bone with increased osteoblastic activity was observed in intimate contact with DBBM particles [Figure 7]. There were no statistically significant differences between the two groups with respect to the types of bone marrow [Table 4] ( $P = 0.141$ ). The amount of

**Table 1: Horizontal measurement (mm) for demineralized freeze-dried bone allograft and deproteinized bovine bone mineral groups at baseline and 4-6 months postsocket preservation**

Group	Mean±SD			P
	Baseline	4-6 months	Difference	
DBBM	7.89±0.63	5.63±0.60	-2.26±0.51	<0.001
DFDBA	7.79±0.89	5.49±0.99	-2.30±0.64	<0.001
Difference	0.10±0.35	0.14±0.36	0.04±0.26	
P	0.777	0.706	0.878	

DFDBA: Demineralized freeze-dried bone allograft; DBBM: Deproteinized bovine bone mineral; SD: Standard deviation

**Table 2: Vertical measurements (mm) for demineralized freeze-dried bone allograft and deproteinized bovine bone mineral groups at baseline and 4-6 months postsocket preservation**

Group	Mean±SD			P
	Baseline	4-6 months	Difference	
<b>Buccal side</b>				
DBBM	6.23±1.45	7.33±1.46	1.1±0.17	<0.01
DFDBA	5.65±1.11	6.94±1.30	1.29±0.68	<0.001
Difference	0.700±0.56	0.27±0.66	-0.43±0.32	
P	0.226	0.686	0.195	
<b>Lingual side</b>				
DBBM	6.25±1.48	6.60±1.51	0.35±0.34	<0.05
DFDBA	5.85±1.55	6.26±1.44	0.41±0.38	<0.01
Difference	0.40±0.68	0.34±0.66	-0.06±0.16	
P	0.562	0.612	0.714	

DFDBA: Demineralized freeze-dried bone allograft; DBBM: Deproteinized bovine bone mineral; SD: Standard deviation

**Table 3: Mean percentage of lamellar and woven bone**

Group	Mean (%)±SD	
	Lamellar bone	Woven bone
DFDBA	66.6±7.77	35.30±7.14
DBBM	44.5±10.12	55.40±10.1

DFDBA: Demineralized freeze-dried bone allograft; DBBM: Deproteinized bovine bone mineral; SD: Standard deviation

**Table 4: Type of bone marrow in demineralized freeze-dried bone allograft and deproteinized bovine bone mineral groups**

Group (%)	Fatty vascular	Fibrosis	Total
DFDBA count	5 (50)	5 (50)	10 (100)
DBBM count	1 (10)	9 (90)	10 (100)
Total	6 (30)	14 (70)	20 (100)

DFDBA: Demineralized freeze-dried bone allograft; DBBM: Deproteinized bovine bone mineral

inflammation was higher in DBBM group than in DFDBA group [Table 5], but the difference was not statistically significant ( $P = 0.653$ ). Results of histomorphometric analysis are shown in Table 6.

**Table 5: The amount of inflammation in two study groups**

Group (%)	Inflammation <10 within group	Inflammation >10 within group	Total
DFDBA count	6 (60)	4 (40)	10 (100)
DBBM count	5 (50)	5 (50)	10 (100)
Total count	11 (55)	9 (45)	20 (100)

DFDBA: Demineralized freeze-dried bone allograft; DBBM: Deproteinized bovine bone mineral

**Table 6: Histomorphometric data (percentage of new bone and residual graft materials) in two study groups**

Group	Mean (%)±SD	
	New bone	Residual graft material
DFDBA	34.49±3.19	6.06±1.02
DBBM	18.76±3.54	12.77±1.85
P	0.004	0.005

DFDBA: Demineralized freeze-dried bone allograft; DBBM: Deproteinized bovine bone mineral; SD: Standard deviation

The mean percentage of vital bone for DBBM group was 18.76% ± 3.54 and for DFDBA group it was 34.49% ± 3.19. There was statistically significant difference in total bone between groups ( $P = 0.004$ ). DFDBA-treated sockets showed 6.06 ± 1.02% of residual graft particles whereas DBBM-treated sockets contained 12.77% ± 1.85 residual graft particles. The difference between two groups was statistically significant ( $P = 0.005$ ).

## DISCUSSION

The present randomized clinical trial compared DBBM with DFDBA in ridge preservation following tooth extraction. DBBM (Bio-Oss®) is Deproteinized Bovine Bone Mineral with high osseointegrative property proved by clinical and histologic studies.<sup>[22-25]</sup> DFDBA is supposed to cause bone regeneration through both osseointegration and osseointegration properties.<sup>[26]</sup> Animal studies have demonstrated that the process of demineralization exposes bone morphogenic proteins which have the potential to induce the differentiation of local uncommitted connective tissue cells into osteoblasts.<sup>[27,28]</sup>

In this 4–6 months study, changes in ridge width occurred clinically following tooth extraction in both groups. The average loss of alveolar width was 2.26 ± 0.51 mm (28.58%) for the DBBM and 2.3 ± 0.64 mm (29.75%) for the DFDBA group, but the intergroup difference was not statistically significant. Cardaropoli *et al.*<sup>[29]</sup> used DBBM

and collagen membrane to preserve extraction sockets and reported alveolar ridge changes were less in the treated group (1.04 ± 1.08 mm) than control group (4.48 ± 0.65 mm). Their study includes premolar and molar teeth, and augmentation was performed without flap elevation. Gholami *et al.*<sup>[30]</sup> showed 1.07 mm loss of ridge width in nonmolar sockets filled with DBBM, but their study was different from ours in the way they included the teeth that had complete socket walls. Moreover, our findings were not in agreement with Kotsakis *et al.*'s investigation that showed mean reduction in the buccolingual dimension of 1.39 ± 0.57 mm in DBBM group.<sup>[31]</sup> The reason for this difference could be attributed to utilizing socket plug technique and molar and premolar extracted sockets. Iasella *et al.*<sup>[3]</sup> showed that ridge preservation using freeze-dried bone allograft and collagen membrane resulted in less alveolar ridge loss compared to extraction alone (1.2 ± 0.9 mm vs. 2.6 ± 2.3 mm). Vance *et al.*<sup>[21]</sup> showed in their study on nonmolar teeth 0.5 ± 0.8 mm loss of ridge width in both Bio-Oss® and collagen membrane group and DFDBA in a putty carrier group.

In the present study, height of the alveolar ridge decreased in buccal and lingual/palatal sides of preserved sockets in both groups, DFDBA group experienced a 1.29 mm loss in buccal sides, whereas DBBM group showed reduction of 1.1 mm. The difference was not statistically significant between the two groups. More bone loss occurred in the buccal than in the lingual/palatal side following tooth extraction. This is in agreement with the results of other studies.<sup>[32,33]</sup> Nevins *et al.*<sup>[33]</sup> evaluated the fate of buccal plate in maxillary anterior teeth by comparing pre- and post-extraction computed tomography scans. They showed a vertical resorption of 2.42 ± 2.58 mm in sockets grafted with Bio-Oss®, while it was 5.24 ± 3.72 mm in control group. Cardaropoli *et al.*<sup>[29]</sup> reported 0.46 mm mean height reduction after 4 months using Bio-Oss® collagen. This value was 0.7 mm in Barone *et al.*<sup>[32]</sup> study using DBBM. In addition, Vance *et al.*<sup>[21]</sup> reported 0.3 ± 0.7 mm vertical loss in DFDBA and 0.7 ± 1.2 mm vertical gain in Bio-Oss® groups. The more positive outcome obtained by DBBM may be related to its low resorption rate, enabling the graft to act as a scaffold for longer time.<sup>[29,34]</sup>

Van der Weijden *et al.*<sup>[35]</sup> showed that spontaneous healing following tooth extraction resulted in average reduction of 3.87 mm in width and 1.67 mm in height



of alveolar ridge. Based on systematic reviews, when socket augmentation is performed, ridge dimensions can be preserved to some extent.<sup>[36,37]</sup> The results seem to depend on the type of materials and technique used<sup>[38]</sup> and on the condition of the socket. Many studies performed on intact sockets included molar teeth that have thick buccal and lingual plates while many conducted on sockets with bony defects. Flap closure over the augmented socket is another issue that was varying in different studies.

For histologic and histomorphometric evaluation, bone was harvested from implant sites with trephine bur. To be ensured that specimens were obtained from grafted portion of sockets not the native bone, a narrow trephine with 2 mm internal diameter and 3 mm external diameter was used and only a 3 mm × 6 mm bony core was taken. The mean amount of new bone for DFDBA group was 34.49% which was in line with Froum *et al.*<sup>[19]</sup> and Wood *et al.*<sup>[39]</sup> studies, they showed 34.7% and 38.4% new bone in socket grafted with DFDBA. In our study, the mean amount of new bone for DBBM was 18.76% which was significantly less than DFDBA group. Calasans-Maia *et al.* demonstrated a mean value of 19.3% (±22.6) new bone formation in socket grafted with Bio-Oss<sup>®</sup> after a 24-week healing period which was in line with our study.<sup>[40]</sup>

Lee *et al.*<sup>[23]</sup> reported 23.6% new bone formation in sockets grafted with DBBM and Gholami *et al.* showed 27.35% in their 6–8 months study. Artzi *et al.*<sup>[41]</sup> in a 9 months study reported 46% bone formation using same material. Differences in the amount of bone formation between studies could be due to different follow-up time. In our research, the amount of new bone in DFDBA group (34.49%) was more than DBBM group (18.76%). The difference may be attributed to low resorption rate of DBBM and demineralized nature of DFDBA. Chan *et al.* in a systematic review reported that the mean percentage of vital bone in natural healing sockets was 38.5%, the use of DFDBA did not affect the amount of vital bone formation, and DBBM showed conflicting results.<sup>[37]</sup> Vance *et al.* who augmented sockets with DFDBA in a carrier (carboxymethylcellulose and calcium sulfate) or DBBM presented 61 ± 9% vital bone in DFDBA group versus 26 ± 20% in the DBBM group after 4 months. They have explained that higher percentage of vital bone in DFDBA group may be related to earlier and greater vascular and cellular growth in porous structure of the carrier material.<sup>[21]</sup>

In the present work, residual graft particles in DFDBA group (6.06%) were less than DBBM group (12.77%), which is in agreement with other studies.<sup>[21,23,39]</sup> However, the amount of residual DBBM (12.77%) was still significantly less than the mentioned amount by Zitzmann *et al.*<sup>[42]</sup> (40%) for successful implant placement.

The residual particles of DBBM were in contact with both new bone and osteoid [Figure 7], this is in agreement with other studies.<sup>[29,41]</sup> The incorporation of the DBBM particles with new bone provide a dense scaffold for further bone deposition and a good support for dental implants.<sup>[42]</sup> Furthermore, DBBM graft particles are known to be resorbed and replaced with bone slowly, which means that the graft material takes part in bone remodeling.<sup>[34,43]</sup>

## CONCLUSION

The results of this 4–6 months study exhibited that from the clinical point of view, both DFDBA and DBBM covered by collagen membrane have similar effects on horizontal and vertical bone resorption of extraction sockets. Histomorphometrically, the percentage of new bone formation in DFDBA group was more than DBBM group while DBBM was associated with higher residual graft particles.

## Financial support and sponsorship

Nil.

## Conflicts of interest

The authors of this manuscript declare that they have no conflicts of interest, real or perceived, financial or non-financial in this article.

## REFERENCES

1. Lekovic V, Kenney EB, Weinlaender M, Han T, Klokkevold P, Nedic M, *et al.* A bone regenerative approach to alveolar ridge maintenance following tooth extraction. Report of 10 cases. *J Periodontol* 1997;68:563-70.
2. Lekovic V, Camargo PM, Klokkevold PR, Weinlaender M, Kenney EB, Dimitrijevic B, *et al.* Preservation of alveolar bone in extraction sockets using bioabsorbable membranes. *J Periodontol* 1998;69:1044-9.
3. Iasella JM, Greenwell H, Miller RL, Hill M, Drisko C, Bohra AA, *et al.* Ridge preservation with freeze-dried bone allograft and a collagen membrane compared to extraction alone for implant site development: A clinical and histologic study in humans. *J Periodontol* 2003;74:990-9.
4. Sobolik CF. Alveolar bone resorption. *J Prosthet Dent* 1960;10:612-9.

5. Garg AK. Alveolar ridge preservation during and after surgical tooth removal. Interview. Dent Implantol Update 2001;12:57-62.
6. Pietrokovski J, Massler M. Alveolar ridge resorption following tooth extraction. J Prosthet Dent 1967;17:21-7.
7. Schropp L, Wenzel A, Kostopoulos L, Karring T. Bone healing and soft tissue contour changes following single-tooth extraction: A clinical and radiographic 12-month prospective study. Int J Periodontics Restorative Dent 2003;23:313-23.
8. Artzi Z, Tal H, Dayan D. Porous bovine bone mineral in healing of human extraction sockets: 2. Histochemical observations at 9 months. J Periodontol 2001;72:152-9.
9. Buser D, Dula K, Hirt HP, Schenk RK. Lateral ridge augmentation using autografts and barrier membranes: A clinical study with 40 partially edentulous patients. J Oral Maxillofac Surg 1996;54:420-32.
10. Belser UC, Buser D, Hess D, Schmid B, Bernard JP, Lang NP. Aesthetic implant restorations in partially edentulous patients – A critical appraisal. Periodontol 2000 1998;17:132-50.
11. Adriaens PA. Preservation of bony sites. In: Lang NP, Karring T, Lindhe J, editors. Proceeding of the Third European Workshop on Periodontology: Implant Dentistry. Chicago: Quintessence Publishing Co. Inc.; 1999. p. 266-80.
12. Nevins M, Mellonig JT. Enhancement of the damaged edentulous ridge to receive dental implants: A combination of allograft and the GORE-TEX membrane. Int J Periodontics Restorative Dent 1992;12:96-111.
13. Keith JD Jr., Salama MA. Ridge preservation and augmentation using regenerative materials to enhance implant predictability and esthetics. Compend Contin Educ Dent 2007;28:614-21.
14. Becker W, Becker BE, Caffesse R. A comparison of demineralized freeze-dried bone and autologous bone to induce bone formation in human extraction sockets. J Periodontol 1994;65:1128-33. Erratum in: J Periodontol 1995;66:309.
15. Becker W, Urist M, Becker BE, Jackson W, Parry DA, Bartold M, *et al.* Clinical and histologic observations of sites implanted with intraoral autologous bone grafts or allografts 15 human case reports. J Periodontol 1996;67:1025-33.
16. Becker W, Clokie C, Sennerby L, Urist MR, Becker BE. Histologic findings after implantation and evaluation of different grafting materials and titanium micro screws into extraction sockets: Case reports. J Periodontol 1998;69:414-21.
17. Smukler H, Landi L, Setayesh R. Histomorphometric evaluation of extraction sockets and deficient alveolar ridges treated with allograft and barrier membrane: A pilot study. Int J Oral Maxillofac Implants 1999;14:407-16.
18. Brugnami F, Then PR, Moroi H, Kabani S, Leone CW. GBR in human extraction sockets and ridge defects prior to implant placement: Clinical results and histologic evidence of osteoblastic and osteoclastic activities in DFDBA. Int J Periodontics Restorative Dent 1999;19:259-67.
19. Froum S, Cho SC, Rosenberg E, Rohrer M, Tarnow D. Histological comparison of healing extraction sockets implanted with bioactive glass or demineralized freeze-dried bone allograft: A pilot study. J Periodontol 2002;73:94-102.
20. Artzi Z, Nemcovsky CE. The application of deproteinized bovine bone mineral for ridge preservation prior to implantation. Clinical and histological observations in a case report. J Periodontol 1998;69:1062-7.
21. Vance GS, Greenwell H, Miller RL, Hill M, Johnston H, Scheetz JP. Comparison of an allograft in an experimental putty carrier and a bovine-derived xenograft used in ridge preservation: A clinical and histologic study in humans. Int J Oral Maxillofac Implants 2004;19:491-7.
22. Hämmerle CH, Jung RE, Yaman D, Lang NP. Ridge augmentation by applying bioresorbable membranes and deproteinized bovine bone mineral: A report of twelve consecutive cases. Clin Oral Implants Res 2008;19:19-25.
23. Lee DW, Pi SH, Lee SK, Kim EC. Comparative histomorphometric analysis of extraction sockets healing implanted with bovine xenografts, irradiated cancellous allografts, and solvent-dehydrated allografts in humans. Int J Oral Maxillofac Implants 2009;24:609-15.
24. Berglundh T, Lindhe J. Healing around implants placed in bone defects treated with Bio-Oss. An experimental study in the dog. Clin Oral Implants Res 1997;8:117-24.
25. Skoglund A, Hising P, Young C. A clinical and histologic examination in humans of the osseous response to implanted natural bone mineral. Int J Oral Maxillofac Implants 1997;12:194-9.
26. Goldberg VM, Stevenson S. Natural history of autografts and allografts. Clin Orthop Relat Res 1987;Des(225):7-16.
27. Urist MR, Strates BS. Bone formation in implants of partially and wholly demineralized bone matrix. Including observations on acetone-fixed intra and extracellular proteins. Clin Orthop Relat Res 1970;71:271-8.
28. Mellonig JT, Bowers GM, Bailey RC. Comparison of bone graft materials. Part I. New bone formation with autografts and allografts determined by Strontium-85. J Periodontol 1981;52:291-6.
29. Cardaropoli D, Tamagnone L, Roffredo A, Gaveglia L, Cardaropoli G. Socket preservation using bovine bone mineral and collagen membrane: A randomized controlled clinical trial with histologic analysis. Int J Periodontics Restorative Dent 2012;32:421-30.
30. Gholami GA, Najafi B, Mashhadiabbas F, Goetz W, Najafi S. Clinical, histologic and histomorphometric evaluation of socket preservation using a synthetic nanocrystalline hydroxyapatite in comparison with a bovine xenograft: A randomized clinical trial. Clin Oral Implants Res 2012;23:1198-204.
31. Kotsakis GA, Salama M, Chrepa V, Hinrichs JE, Gaillard P. A randomized, blinded, controlled clinical study of particulate anorganic bovine bone mineral and calcium phosphosilicate putty bone substitutes for socket preservation. Int J Oral Maxillofac Implants 2014;29:141-51.
32. Barone A, Aldini NN, Fini M, Giardino R, Calvo Guirado JL, Covani U. Xenograft versus extraction alone for ridge preservation after tooth removal: A clinical and histomorphometric study. J Periodontol 2008;79:1370-7.
33. Nevins M, Camelo M, De Paoli S, Friedland B, Schenk RK, Parma-Benfenati S, *et al.* A study of the fate of the buccal wall of extraction sockets of teeth with prominent roots. Int J Periodontics Restorative Dent 2006;26:19-29.
34. Araújo MG, Liljenberg B, Lindhe J. Dynamics of Bio-Oss Collagen incorporation in fresh extraction wounds: An



- experimental study in the dog. *Clin Oral Implants Res* 2010;21:55-64.
35. van der Weijden F, Dell'Acqua F, Slot DE. Alveolar bone dimensional changes of post-extraction sockets in humans: A systematic review. *J Clin Periodontol* 2009;36:1048-58.
  36. Ten Heggeler JM, Slot DE, van der Weijden GA. Effect of socket preservation therapies following tooth extraction in non-molar regions in humans: A systematic review. *Clin Oral Implants Res* 2011;22:779-88.
  37. Chan HL, Lin GH, Fu JH, Wang HL. Alterations in bone quality after socket preservation with grafting materials: A systematic review. *Int J Oral Maxillofac Implants* 2013;28:710-20.
  38. Araújo MG, Lindhe J. Dimensional ridge alterations following tooth extraction. An experimental study in the dog. *J Clin Periodontol* 2005;32:212-8.
  39. Wood RA, Mealey BL. Histologic comparison of healing after tooth extraction with ridge preservation using mineralized versus demineralized freeze-dried bone allograft. *J Periodontol* 2012;83:329-36.
  40. Calasans-Maia M, Resende R, Fernandes G, Calasans-Maia J, Alves AT, Granjeiro JM. A randomized controlled clinical trial to evaluate a new xenograft for alveolar socket preservation. *Clin Oral Implants Res* 2014;25:1125-30.
  41. Artzi Z, Tal H, Dayan D. Porous bovine bone mineral in healing of human extraction sockets. Part 1: Histomorphometric evaluations at 9 months. *J Periodontol* 2000;71:1015-23.
  42. Zitzmann NU, Schärer P, Marinello CP, Schüpbach P, Berglundh T. Alveolar ridge augmentation with Bio-Oss: A histologic study in humans. *Int J Periodontics Restorative Dent* 2001;21:288-95.
  43. Carmagnola D, Adriaens P, Berglundh T. Healing of human extraction sockets filled with Bio-Oss. *Clin Oral Implants Res* 2003;14:137-43.

