

Case Report

Successful treatment of a large implant periapical lesion that caused paraesthesia and perimandibular abscess

Mohammad Jafarian¹, Farshid Rayati², Elnaz Najafi³

¹Department of Oral and Maxillofacial Surgery, Dental Research Center, Dental School and A. Taleghani Medical Center, Shahid Beheshti University of Medical Sciences, ³Private Practice, Tehran, ²Department of Oral and Maxillofacial Surgery, Dental Caries Prevention Research Center, Qazvin University of Medical Sciences, Qazvin, Iran

ABSTRACT

Successful treatment of a large implant periapical lesion (IPL) that caused paraesthesia and perimandibular abscess. IPL is a pathologic phenomenon that rarely involves implants. This event first described in 1992 with an incidence rate of 0.26–9.9% and the origin is not well known. The most likely suggested causes are presence of preexisting bone pathology, contamination of implant surface, bone overheating during implant surgery, vascular ischemia, excessive tightening of the implant, fenestration of the buccal plate and different implant surface designs. In the present case report, we describe relatively large periapical lesions involving several implants caused severe abscess accompanied by transient inferior alveolar nerve paraesthesia and its successful management. A brief review of the literature and a discussion of possible causes and different treatment plans are also included.

Key Words: Implant periapical lesion, paraesthesia, perimandibular abscess

Received: May 2015

Accepted: December 2015

Address for correspondence:

Dr. Farshid Rayati,
Department of Oral and
Maxillofacial Surgery, Dental
Caries Prevention Research
Center, Qazvin University
of Medical Sciences,
Bahonar Blvd., Qazvin, Iran.
E-mail: frayati@qums.ac.ir

INTRODUCTION

Implant periapical lesion (IPL) or apical peri-implantitis is one possible cause of dental implant failure. It is a rare event first described in 1992,^[1] with the incidence of 0.26–9.9%.^[2] The etiology of these lesions still remains unknown. The most likely suggested causes are presence of preexisting bone pathology,^[3] contamination of implant surface,^[4] bone overheating during implant surgery,^[5] vascular ischemia,^[6] excessive tightening of the implant, fenestration of the buccal plate, and different implant surface designs.^[2] According to the clinical behavior, IPLs are classified into inactive and active lesions.^[7] The diagnosis is based on clinical signs and symptoms and radiographic findings. The

inactive form is similar to a periapical scar, shows no clinical symptoms and may result from a heat-induced aseptic bone necrosis or placing shorter implants in longer prepared sites.^[7] This form seems to need a mere clinical and radiographic follow-up.^[8] Active lesions are usually accompanied by pain, swelling, tenderness and fistulation. Treatment for active types is surgical removal of the lesion and debridement to achieve bacterial eradication. Most of the studies in the literature reported periapical implant lesions in cases with single implant insertions. The present case report describes a patient with active peri-implantitis in two adjacent implants who underwent 19 implant placements in two sessions. Besides, to the best of

Access this article online



Website: www.drj.ir
www.drjournal.net
www.ncbi.nlm.nih.gov/pmc/journals/1480

This is an open access article distributed under the terms of the Creative Commons Attribution-NonCommercial-ShareAlike 3.0 License, which allows others to remix, tweak, and build upon the work non-commercially, as long as the author is credited and the new creations are licensed under the identical terms.

For reprints contact: reprints@medknow.com

How to cite this article: Jafarian M, Rayati F, Najafi E. Successful treatment of a large implant periapical lesion that caused paraesthesia and perimandibular abscess. *Dent Res J* 2016;13:188-92.

our knowledge, in none of the previously reported IPL cases, the infection was so extensive to cause paraesthesia of peripheral nerves or necessitate an incision and drainage procedure.

CASE REPORT

A healthy 49-year-old Caucasian man presented with totally edentulous lower and upper jaws. His teeth were extracted 1 year ago, and a conventional denture was used thereafter. His chief complaint was denture unfitness. No preexisting bone pathology was evident according to the preoperative panoramic, and cone-beam computed tomography (CBCT) radiographs.

One hour after taking 2 g of Amoxicillin orally as prophylaxis the patient underwent placement of 19 submerged implants (Branemark System, MK III, Nobel Bio Care AB, Goteborg, Sweden) in two sessions 10 days apart, using a modification of Nobel Bio-Guide System (10 in maxilla and 9 in mandible). All the drilling procedure accomplished with 800 rpm and under copious saline irrigation.

After surgery, Amoxicillin (500 mg, q8h) and Ibuprofen (400 mg, q6h) were prescribed for 10 days and the patient asked to rinse with Chlorhexidine 0.2% mouthwash twice daily for 2 weeks. During routine radiographic follow-up, radiolucent lesions were noted around 6 of 9 mandibular implants that considered to be due to over drilling [Figure 1].

In subsequent orthopantomograph taken 1 week later, the radiolucent lesions around two implants appeared to become larger. Within 10 days patient returned with pain, perimandibular abscess, mental nerve paraesthesia and pus drainage in his left mandibular premolar area. Another panoramic radiograph revealed well circumscribed periapical radiolucencies in all mandibular implants. In mandibular left premolar area, radiolucent lesions involved the apex and middle portion of two adjacent implants. The CBCT images confirmed the bony defects and revealed buccal cortical plate dehiscence in that area.

Due to the relatively large size of the abscess an incision and drainage procedure performed and Clindamycin (300 mg, q8h) was prescribed for 10 days. We chose Clindamycin because of its good bone penetration and failure of the Amoxicillin to control the infection. The symptoms failed to subside completely with antibiotic treatment and a periapical

surgery and exploration considered as a diagnostic, therapeutic treatment modality. A full thickness flap was reflected by a sulcular incision, and a large periapical defect was observed [Figure 2].

Debridement of the inflamed tissue at the defect site was followed by complete curettage of implant surface and surrounding bone using sterile plastic and Teflon coated instruments. The implants were stable, and no mobility was evident. After copious irrigation of the bony defect with sterile normal saline, it was filled with xenograft bone substitute (Cerabone, Botiss dental GmbH, Germany) and covered with resorbable collagen membrane (Jason Membrane, Botiss dental GmbH, Germany) [Figures 3 and 4]. Wound closure obtained with 4-0 silk sutures. Following surgery, systemic antibiotic (Amoxicillin 500 mg, three times daily) was prescribed for 10 days and patient asked to rinse with Chlorhexidine 0.2% mouthwash for 2 weeks. One week later, all the symptoms, including paraesthesia subsided. All radiolucencies gradually resolved (how long did it take to resolve) entirely according to monthly radiographic evaluation [Figure 5].

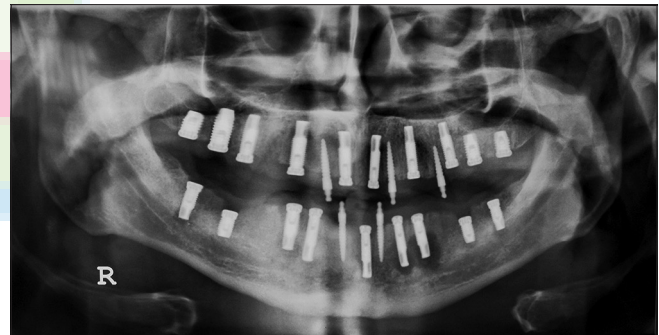


Figure 1: Panoramic view of the patient showing periapical lesion around multiple implants.

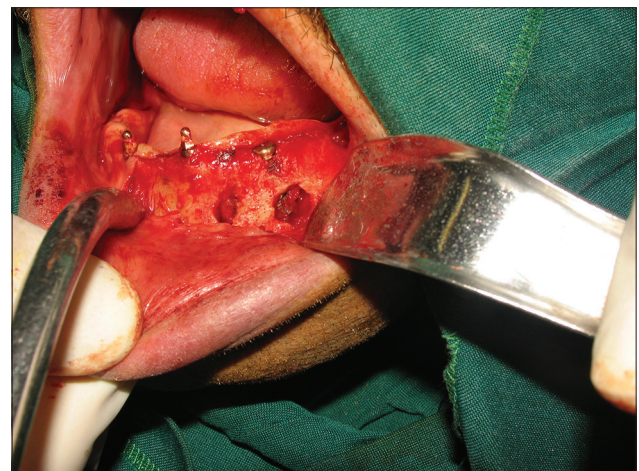

Figure 2: Bony defects around apical part of implants.

Four months later, all implants were loaded with fixed implant-supported prosthesis. After 6 months from

prosthetic rehabilitation, no clinical or radiographic alterations were observed.

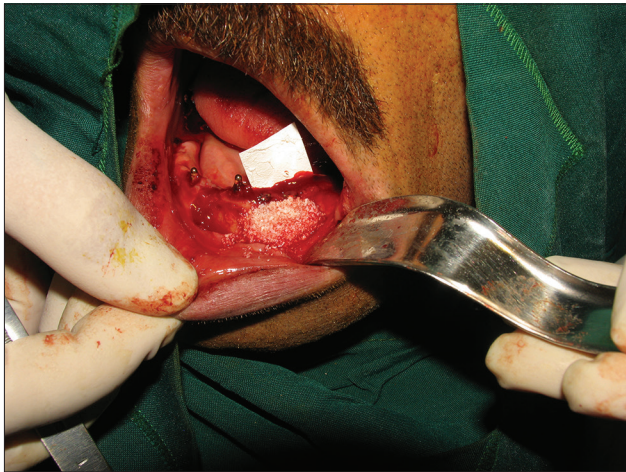

Figure 3: Defects filled with bone substitute after complete debridement.

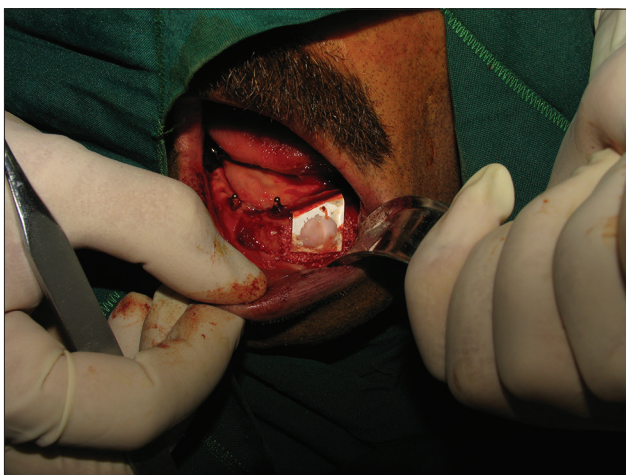


Figure 4: Covering the surgical area with a resorbable membrane.

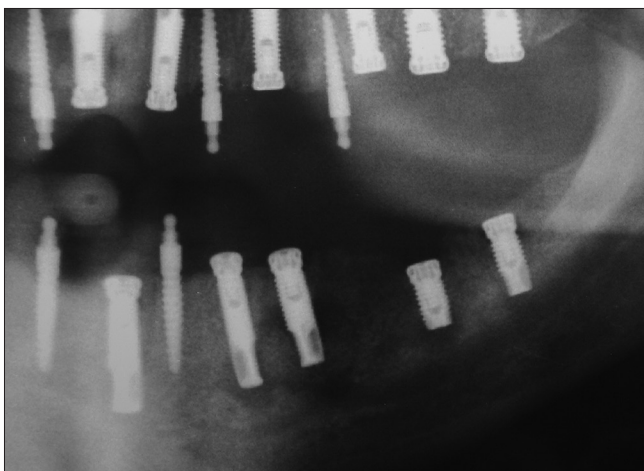


Figure 5: Three-month postoperative radiography.

DISCUSSION

Apical peri-implantitis is a rare lesion. Reiser and Nevins reported just 10 cases with IPL out of 3,800 implants.^[7] IPL is reported to affect maxillary implants more than mandibular ones, predominantly in premolar sites.^[9] IPL is more common in the anterior part of the jaws. In our case, only implants in mandibular first and second premolar sites showed active IPL and none of the maxillary implants were affected. The affected implants had a length more than 12 mm which was the same as the majority of reported IPLs. According to available data, the standard 2-stage protocol had almost always been used for the affected implants and IPL occurred most frequently before loading. The affected implants in our case had the same situation, too.

Although various etiologic factors for apical bone loss have been suggested, it seems to have a multi factorial origin. Quirynen *et al.* suggested that the residual infection of the apical endodontic pathology of the natural adjacent tooth or teeth that had pathology prior to extraction were the most likely cause of the lesions.^[10] However, the presence of preexisting bone pathology cannot be an etiological factor in our case, because the patient had been edentulous for 1 year, and presurgical radiographs did not reveal any pathologies or root remnants. Surgical trauma such as bone overheating during implant placement was considered as the second most likely cause of IPL.^[11] In our case, clinical examination, treatment history, radiographic analysis, and histological examination suggested two probable causes for IPL: (1) Bone overheating: Despite meticulous irrigation during surgery, using Nobel Bio Guide System and drilling through the metal sleeves may reduce the efficacy of saline cooling. Besides, our affected implants were 13 mm and 15 mm in length and it was reported that preparing the osteotomy site with external irrigation for long implant (>12 mm) can cause bone overheating. (2) Buccal cortical bone fenestration: No clinical evidence of buccal bone fenestration was found during and after surgery. Among all nine inserted implants in mandible, just two of them in left premolar area showed active IPL and in follow-up CBCT sections, buccal bone fenestration was evident just in this site that seems to be due to the pathologic

events and not a preexisting one. One possibility is a lack of enough cortical bone thickness on the buccal side (<0.5 mm). As our implants had not been loaded, overloading can be ruled out. Quirynen *et al.* observed that despite lower failure rate of rough surface implants, the incidence of IPL was significantly higher with them when compared with machine surface implants.^[10] In this case, all 19 implants had rough surfaces. Surface texture does not seem to have a significant role in our case.

There is no general agreement on the exact treatment modality for an IPL. Stable, asymptomatic and inactive lesions do not require any specific treatment and regular follow-up and radiographic assessment seems to be sufficient. In active lesions different therapies have been suggested, including: (1) Nonsurgical treatment through systemic antibiotic administration; (2) resective treatments including thorough debridement of infected lesion along with implant surface detoxification and implant apicoectomy; (3) regenerative treatments, including debridement, implant surface detoxification, implant apicoectomy and guided bone regeneration (GBR) and (4) complete implant removal. Most of the reported active IPLs, including our case, did not respond to monotherapy via systemic antibiotics.^[9] Only Chang *et al.* reported successful IPL treatment by amoxicillin and augmentin administration.^[2] [in that article (abstract is attached): Amoxicillin with acetaminophen didn't work but prednisolone + Augmentin + mefenamic acid worked. Atabaki]. Some authors reported resolution of implant apical radiolucencies using the respective treatment procedures.^[12-14] In a situation when the implant surface characteristics, geometry or implant type limits/prevents proper debridement, implant apicoectomies may be indicated, too.^[7,15,16] The size and shape of the lesion has an important role in choosing an appropriate treatment plan. In reports with only resective procedures, the size of the lesion was relatively small, and there was an acceptable amount of bone around implant bodies. In our case, despite the presence of a relatively large lesion the four-wall characteristic of the bony defect which resulted a "contained cavity type" defect, GBR procedure made an acceptable and promising treatment modality. The defect covered with a collagen membrane to prevent possible in growth of overlying soft tissue. One year follow-up of the patient demonstrated an eventful healing without failure of any of the implants.

CONCLUSION

To prevent IPL, evaluation of planned implant sites for potential contaminants, careful surgical technique, and meticulous sterilization methods are mandatory. No systematic and standard treatment procedure is introduced, and therapy is based mainly on empirical experiences. Some factors such as the size of the lesion and implant stability should also be taken into consideration to select appropriate treatment. In this case, despite the extension of the bony destruction caused by active IPL, both of the affected implants could be saved using GBR technique beside mechanical debridement (Atabaki).

Financial support and sponsorship

Nil.

Conflicts of interest

The authors of this manuscript declare that they have no conflicts of interest, real or perceived, financial or non-financial in this article.

REFERENCES

1. McAllister BS, Masters D, Meffert RM. Treatment of implants demonstrating periapical radiolucencies. *Pract Periodontics Aesthet Dent* 1992;4:37-41.
2. Chang LC, Hsu CS, Lee YL. Successful medical treatment of an implant periapical lesion: A case report. *Chang Gung Med J* 2011;34:109-14.
3. Scarano A, Di Domizio P, Petrone G, Iezzi G, Piattelli A. Implant periapical lesion: A clinical and histologic case report. *J Oral Implantol* 2000;26:109-13.
4. Piattelli A, Scarano A, Piattelli M, Podda G. Implant periapical lesions: Clinical, histologic, and histochemical aspects. A case report. *Int J Periodontics Restorative Dent* 1998;18:181-7.
5. Piattelli A, Scarano A, Balleri P, Favero GA. Clinical and histologic evaluation of an active "implant periapical lesion": A case report. *Int J Oral Maxillofac Implants* 1998;13:713-6.
6. Peñarrocha-Diogo M, Boronat-Lopez A, García-Mira B. Inflammatory implant periapical lesion: Etiology, diagnosis, and treatment – Presentation of 7 cases. *J Oral Maxillofac Surg* 2009;67:168-73.
7. Reiser GM, Nevins M. The implant periapical lesion: Etiology, prevention, and treatment. *Compend Contin Educ Dent* 1995;16:768, 770, 772.
8. Silva GC, Oliveira DR, Vieira TC, Magalhães CS, Moreira AN. Unusual presentation of active implant periapical lesions: A report of two cases. *J Oral Sci* 2010;52:491-4.
9. Park SH, Sorensen WP, Wang HL. Management and prevention of retrograde peri-implant infection from retained root tips: Two case reports. *Int J Periodontics Restorative Dent* 2004;24:422-33.
10. Quirynen M, Vogels R, Alsaadi G, Naert I, Jacobs R, van Steenberghe D. Predisposing conditions for retrograde

Jafarian, *et al.*: Treatment of a large implant periapical lesion

- peri-implantitis, and treatment suggestions. *Clin Oral Implants Res* 2005;16:599-608.
11. Rosendahl K, Dahlberg G, Kisch J, Nilner K. Implant periapical lesion. A case series report. *Swed Dent J* 2009;33:49-58.
 12. Sussman HI, Moss SS. Localized osteomyelitis secondary to endodontic-implant pathosis. A case report. *J Periodontol* 1993;64:306-10.
 13. Balshi SF, Wolfinger GJ, Balshi TJ. A retrospective evaluation of a treatment protocol for dental implant periapical lesions: Long-term results of 39 implant apicoectomies. *Int J Oral Maxillofac Implants* 2007;22:267-72.
 14. Ayango L, Sheridan PJ. Development and treatment of retrograde peri-implantitis involving a site with a history of failed endodontic and apicoectomy procedures: A series of reports. *Int J Oral Maxillofac Implants* 2001;16:412-7.
 15. Jalbout ZN, Tarnow DP. The implant periapical lesion: Four case reports and review of the literature. *Pract Proced Aesthet Dent* 2001;13:107-12.
 16. Oh TJ, Yoon J, Wang HL. Management of the implant periapical lesion: A case report. *Implant Dent* 2003;12:41-6.

