

Case Report

Maxillary tooth displacement in the infratemporal fossa

Korosh Roshanghias¹, Andre Peisker², Jörg Olaf Zieron¹

¹Practice for Oral and Maxillofacial Surgery, Bergedorfer Schlossstrasse, Hamburg, ²Clinic for Oral and Maxillofacial Surgery, Jena University Hospital, Erlanger Allee, Jena, Germany

ABSTRACT

Wisdom tooth operations are sometimes accompanied by complications. This case report shows complications during upper jaw third molar removal. Expectable problems during oral surgery should be planned to be solved in advance. Displacement of the third molar during oral surgeries as a considerable complication is rarely discussed scientifically. A good design of flap, adequate power for extraction, and clear view on the surgical field are crucial. Three-dimensional radiographic diagnostics in terms of cone beam computed tomography is helpful after tooth displacement into the infratemporal fossa.

Key Words: Cone beam computed tomography, oral surgery, tooth, displacement, wisdom tooth, operations

Received: September 2015
Accepted: January 2016

Address for correspondence:
Dr. Korosh Roshanghias,
Practice for Oral and
Maxillofacial Surgery,
Hamburg, Germany.
E-mail: roshanghias@
icloud.com

INTRODUCTION

Occurring complications during oral surgeries such as in wisdom tooth operations are undesirable and aggravating. One of the important ones is displacement of extracted tooth, which is well-known, however, rarely reported in current literature.^[1] There are different opinions about the subsequent procedure. Some recommend hospitalization and immediate removal of tooth or tooth fragments under general anesthesia. Others prefer later intervention.^[2] Frequent complications during third molar surgery such as root fracture, tuber fracture, or displacement of root fragments in the maxillary sinus are managed quite simply. There are no defined protocols in the management of displaced teeth in the current literature.^[3] This case report shows an upper third molar dislocation into infratemporal fossa, diagnostic consequences, and surgical procedure. The important

role of the cone beam computed tomography (CBCT) in determining the localization of the displaced tooth is demonstrated.

CASE REPORT

A 14-year-old patient was transferred to our practice for –oral and maxillofacial surgery after unsuccessful osteotomy of the third upper molar on the left side. The tooth was disappeared in the tissue and not palpable in the soft tissue. After clinical diagnostics, the CBCT showed the dislocated tooth in the infratemporal fossa closed to the zygomatic arch. The axial cross-sections of the CBCT also displayed the precise localization of the tooth [Figure 1]. The volumetric CBCT reconstruction for location identification showed the entire tooth in the infratemporal fossa [Figure 2]. The patient was informed about the surgical procedure

Access this article online



Website: www.drj.ir
www.drjournal.net
www.ncbi.nlm.nih.gov/pmc/journals/1480

This is an open access article distributed under the terms of the Creative Commons Attribution-NonCommercial-ShareAlike 3.0 License, which allows others to remix, tweak, and build upon the work non-commercially, as long as the author is credited and the new creations are licensed under the identical terms.

For reprints contact: reprints@medknow.com

How to cite this article: Roshanghias K, Peisker A, Zieron JO. Maxillary tooth displacement in the infratemporal fossa. *Dent Res J* 2016;13:373-5.

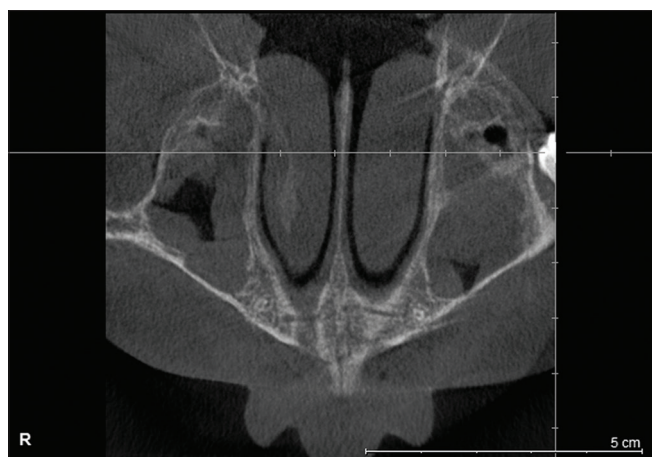

Figure 1: Displacement of the third upper molar in the axial view.

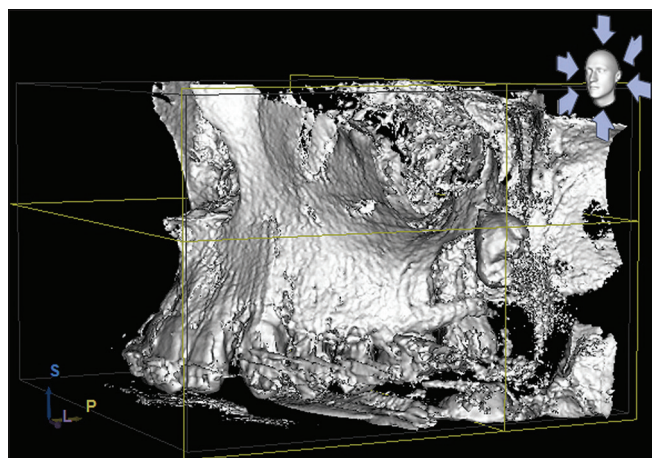


Figure 2: The three-dimensional cone beam computed tomography reconstruction.

and retrieval of the tooth. The indication to the operation was obvious. A full flap was mobilized via the intraoral extended incision marginal on the first molar under general anesthesia. The Bichat fat pad was distracted and the tooth recovered. The incision was sutured with absorbable stitches. To reduce the inflammatory infiltration, an antibiotic treatment using $\times 1$ g amoxicillin with clavulanic acid b.i.d was started for 7 days. Postoperative pain was controlled by ibuprofen 600 mg/q.i.d for 7 days. Within 3 weeks postsurgical, the patient was recovered without any swelling, diplopia, or other sequelae.

DISCUSSION

The main reason for tooth displacement of third molars into the infratemporal fossa is poor extraction technique like forced power under limited visibility. Nevertheless, tooth displacement also may happen

to the experienced oral surgeon.^[4] Third maxillary molars usually are dislocated into the maxillary sinus and rarely into the infratemporal fossa.^[5] Usually, a maxillary third molar which disappeared is supposed to be in the maxillary sinus.^[6] Removing a displaced tooth from the infratemporal fossa can entail serious hemorrhage of the maxillary artery blood vessel and neurologic injury of the maxillary nerve. Even more severe complications such as diplopia are reported.^[1] Other authors performed a Gilles approach through a small incision to provide the displaced tooth from the infratemporal fossa to the intraoral incision.^[2] Therefore, a proper planning of the operation taking possible complications in the account is mandatory. In cases with very high impacted upper wisdom teeth, we recommend a marginal incision from the maxillary tuberosity to the mesial papilla of the first molar. To provide good visibility, a vertical incision from the mesial papilla of the first upper molar to the point between the root tips of the first and second premolar is helpful. This flap design provides good visibility to the posterior maxilla. In case of dislocation of the wisdom tooth into the maxillary sinus, a good approach to its facial wall is possible. Elevating the mucoperiosteal flap, attention should be payed to preserve its continuity as herniation of the Bichat fat pad is the consequence of losing the proper surgical plane. If dislocation of the upper third molar occurs, the position of the tooth may change due to other muscular loges. Radiographic examination is obligatory to identify the displaced tooth. Thereby, a clear view on the surgical field is achievable.

In this report, we used the CBCT with less X-ray beam in comparison to conventional CT. The CBCT provides the exact anatomical location of the displaced tooth. Once the Bichat fat pad is seen during the wisdom teeth operation, the surgeon and the assistants have to handle with care. To prevent displacement of the tooth into the fat pad, a distal retractor should be placed under the tissue. An adequate flap design is also an essential part of the third molar surgery. Proper preoperative diagnostics and suitable flap design are mandatory for taking possible complications in the account.

Financial support and sponsorship

Nil.

Conflicts of interest

The authors of this manuscript declare that they have no conflicts of interest, real or perceived, financial or non-financial in this article.

REFERENCES

1. Durmus E, Dolanmaz D, Kucukkolbsi H, Mutlu N. Accidental displacement of impacted maxillary and mandibular third molars. *Quintessence Int* 2004;35:375-7.
2. Patel M, Down K. Accidental displacement of impacted maxillary third molars. *Br Dent J* 1994;177:57-9.
3. Svezut CE, Trivellato AE, Svezut AT, de Matos FP, Kato RB. Removal of a maxillary third molar accidentally displaced into the infratemporal fossa via intraoral approach under local anesthesia: Report of a case. *J Oral Maxillofac Surg* 2009;67:1316-20.
4. Baig MH, Punjabi S, Khan M. Displacement of maxillary third molar in the infratemporal fossa. *Pak Oral Dent J* 2012;32:39-41.
5. Dimitrakopoulos I, Papadaki M. Displacement of a maxillary third molar into the infratemporal fossa: Case report. *Quintessence Int* 2007;38:607-10.
6. Gulbrandsen SR, Jackson IT, Turlington EG. Recovery of a maxillary third molar from the infratemporal space via a hemicoronal approach. *J Oral Maxillofac Surg* 1987;45:279-82.

