

Original Article

Can tert-butylhydroquinone improve the healing of extracted tooth socket in rats?

Somayeh Khoramian Tusi¹, Tahereh Eslam Manesh², Mahmood Sheikh Fathollahi³, Ali Bagherian⁴

¹Department of Pediatric Dentistry, School of Dentistry, Rafsanjan University of Medical Sciences, ²Department of Pathology, School of Medicine, Rafsanjan University of Medical Sciences, ³Occupational Environment Research Center, School of Medicine, Rafsanjan University of Medical Sciences, Rafsanjan, ⁴Dental Research Center, Faculty of Dentistry, Mashhad University of Medical Sciences, Mashhad, Iran

ABSTRACT

Background: Tooth extraction causes an open wound in the soft and hard tissues. During the inflammatory phase of the healing process, a large amount of free radicals are produced and cause oxidative stress, which leads to tissue damage and delayed wound healing. Thus, in this study, we evaluated the effect of tert-butylhydroquinone (TBHQ), as an antioxidant, on the healing process of tooth sockets in rats.

Materials and Methods: To conduct this experimental study, male Wistar rats ($n = 42$) were divided into two groups. In each case, one upper second molar was extracted under general anesthesia. After the extraction, the tooth sockets of the experimental group were treated with a 0.02% TBHQ solution (0.1 ml) while the same volume of distilled water placed in the sockets of the control group. On days 3, 7, and 21 postoperatively, 7 rats from each group were euthanized, and histological slides were prepared from their tooth sockets. The prepared slides were examined histopathologically using a light microscope and compared using an independent two-sample *t*-test. The significance level was set at 0.05.

Results: In the experimental group, a statistically significant ($P = 0.003$) increase in granulation tissue was observed on day 3, in comparison to the control group. The extent of bony trabeculation was also significantly higher in the TBHQ-treated group than in the control group on day 21 ($P < 0.001$).

Conclusion: Considering the limitations of an experimental study, it can be concluded that TBHQ may enhance the healing of the hard tissue in the tooth sockets.

Key Words: Antioxidants, rats, tooth extraction, wound healing

Received: January 2016
Accepted: November 2016

Address for correspondence:

Dr. Ali Bagherian,
Dental Research Center,
Faculty of Dentistry,
Mashhad University
of Medical Sciences,
Mashhad, Iran.
E-mail: drbagherian@
yahoo.com

INTRODUCTION

Tooth extraction causes an open wound in the soft tissue and bone. The wound healing process is divided into four phases such as coagulation, inflammation, proliferation, and reconstruction.^[1] The acute inflammatory response of gingival tissues within 24–48 h after tooth extraction causes infiltration

of multicore white blood cells to the area of inflammation. In the inflammation phase, neutrophils release free radicals to kill the bacteria. Free radicals are molecules that have an unpaired electron in their valence shell and are highly reactive.^[2] Oxidative stress, caused by an imbalance between the creation

This is an open access article distributed under the terms of the Creative Commons Attribution-NonCommercial-ShareAlike 3.0 License, which allows others to remix, tweak, and build upon the work non-commercially, as long as the author is credited and the new creations are licensed under the identical terms.

For reprints contact: reprints@medknow.com

How to cite this article: Tusi SK, Manesh TE, Fathollahi MS, Bagherian A. Can tert-butylhydroquinone improve the healing of extracted tooth socket in rats?. Dent Res J 2017;14:8-12.

Access this article online



Website: www.drj.ir
www.drjjournal.net
www.ncbi.nlm.nih.gov/pmc/journals/1480

of free radicals and their neutralization by antioxidant enzymes produced by body cells and tissues, leads to tissue destruction and a delay in healing.^[3-5] Cutando *et al.* showed that the topical use of melatonin in the alveolar cavity of dogs reduces the oxidative stress resulting from tooth extraction.^[2] Yoneda *et al.* studied the effect of topical antioxidant substances (coenzyme Q₁₀) on soft-tissue healing after tooth extraction in rats. They concluded that the topical application of coenzyme Q₁₀ causes more rapid healing of the soft tissue cavity but has an inhibitory effect on bone remodeling.^[6]

Tert-Butylhydroquinone (TBHQ) is an antioxidant with a documented effect on reducing oxidative stress. It has been considered the gold standard for antioxidants and is used in food products.^[7,8] TBHQ protects cells against acute toxicity and oxidative stress by inducing the production of a large number of cell protective enzymes and neutralization of toxins such as epoxide hydrolase, glutathione-s-transferase, and glucuronyl transferase.^[9] The effect of TBHQ on the healing of an extracted tooth socket remains to be studied. Therefore, in this study, we aimed to investigate the effect of TBHQ on the healing of tooth sockets after tooth extraction in rats.

MATERIALS AND METHODS

This double-blinded experimental study was performed on male Wistar rats ($n = 42$) of the same size, weight (weighing 120–180 g), and age (3–4 months). All procedures were approved by the Institutional Animal Care Committee and were in accordance with guidelines approved by the National Institutes of Health guide for the care and use of laboratory animals (NIH Publications No. 8023, Revised 1978).

The rats were kept in individual cages under standard conditions in the Department of Physiology of Rafsanjan University of Medical Sciences, Iran. A veterinarian assessed the animals regarding general health and the required conditions for surgery before the beginning of the study. Then, the rats were placed under general anesthesia using an intraperitoneal injection of 0.1 ml/100 g with a combination of anesthetic ketamine 100 mg/ml (Iran Darou, Tehran, Iran) and xylazine 100 mg/ml (Iran Darou) in a ratio of 1:1.^[10]

One maxillary second molar of each animal was extracted. In the experimental group (21 rats),

approximately 0.1 ml of the 0.02% TBHQ solution (Sigma, MO, USA) was placed in the tooth socket (20 mg TBHQ powder was dissolved in 100 ml of distilled water). This concentration was the maximum acceptable concentration of TBHQ used in the food industry. To control the procedure influence, the same volume of distilled water was placed in the sockets of the control group (21 rats). For retaining the compound in the sockets, the animals were kept under anesthesia for approximately 4 h in the supine position.^[10] After recovery, the animals were kept in isolated cages with free access to food and water. The day of the surgery was considered day 0. On the days 3, 7, and 21 postoperatively, 7 rats from each group (experimental and control) were euthanized. The rats' heads were separated by guillotine and kept in a 10% formalin solution (Doctor Mojallali, Tehran, Iran) for 1 week. After 1 week, they were removed from the formalin and placed in ethylenediaminetetraacetic acid 4% (Merck, Berlin, Germany) for bone decalcification.^[10] After softening the bone tissue, tissue passage was conducted using a tissue processor device (Sakura Finetechnical Co., Tokyo, Japan). Then, 5 μ slices were made along the sagittal axis using a microtome (SIEE Medial, Mainz, Germany), and hematoxylin and eosin staining was performed.^[10]

The extent of granulation tissue (mm²), extent of bone trabeculae (mm²), inflammatory cell count, number of fibroblasts, and angiogenesis were the variables that were evaluated to assess restoration under a CXR2 microscope (Labomed, Los Angeles, USA). For the inflammatory cell count of neutrophils, lymphocytes, macrophages, and fibroblasts, the number of cells was counted under $\times 400$ magnification in at least five different fields. Next, the mean cell count in these five fields was calculated for statistical analysis. The number of blood vessels was counted in ten microscopic fields under $\times 400$ magnification. Subsequently, their mean was calculated and recorded for statistical analysis.

Statistical analysis methods

Data were then analyzed using SPSS software (version 18, SPSS Inc., Chicago, IL, USA). The quantitative data were expressed as mean \pm standard deviation, and the change range was reported as the largest observation–smallest observation. The independent two-sample *t*-test was used to compare the mean value of histopathological variables (lymphocytes, macrophages, neutrophils, fibroblasts,

the number of newly formed vessels, extent of granulation tissue, and newly formed bone trabeculae) on days 3, 7, and 21 in both of the groups. $P < 0.05$ was considered statistically significant.

RESULTS

The independent *t*-test showed that the mean size of the granulation tissue (mm^2) was significantly greater in the TBHQ group than in the control group ($P = 0.003$) on day 3 [Table 1]. The mean value of other histopathological variables on day 3 in the two study groups was not statistically significant ($P > 0.050$). The independent *t*-test indicated no significant difference in the mean value of histopathological variables in the two study groups ($P > 0.050$) on day 7 [Table 1]. The independent *t*-test indicated that the mean value of neutrophils was significantly lower in the TBHQ group than in the control group ($P = 0.030$) on day 21 [Table 1]. The mean value of the extent of bone trabeculation was significantly greater in the TBHQ group than in the control group [$P = 0.001$, Figure 1]. The mean value of other histopathological variables in the two groups showed no statistically significant difference ($P > 0.050$) on day 21.

DISCUSSION

In the process of wound healing, the production of reactive oxygen species (ROS) is necessary to defend body against pathogens.^[11,12] However, exposure to ROS can cause oxidative stress induction and delayed wound healing.^[13] Therefore, improvement of the oxidative stress status using antioxidants accelerates the healing process. Thus far, to the best of our knowledge, no studies have been conducted on the effects of TBHQ on wound healing after tooth extraction, and no similar study was available. Therefore, the findings of this study are compared with the findings of studies that have examined the effect of TBHQ on skin wound healing and that have examined other antioxidants' effects on healing after tooth extraction. With respect to healing

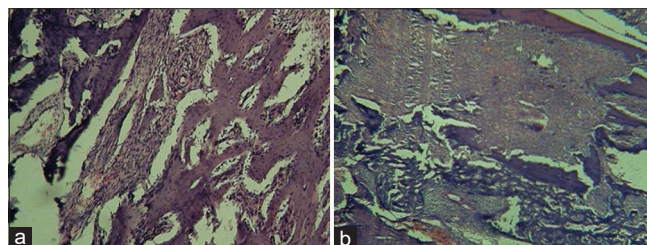


Figure 1: Healing of extracted tooth socket on day 21. (a) Experimental group (b) control group.

Table 1: Comparison of histopathological variables between the two groups on day 3, 7, and 21

Histopathological variable	Day	Mean±SD (change range)		P
		TBHQ (n=7)	Control (n=7)	
The number of newly formed vessels	3	9.00±2.16 (6-13)	7.00±1.83 (5-10)	0.086
	7	7.43±1.27 (6-9)	6.29±1.11 (5-8)	0.099
	21	2.71±0.76 (2-4)	3.57±0.98 (2-5)	0.091
Neutrophils (%)	3	14.71±5.53 (9-25)	19.14±4.22 (11-22)	0.597
	7	11.71±2.81 (9-17)	15.00±2.94 (10-18)	0.054
	21	3.71±1.11 (2-5)	5.00±0.82 (4-6)	0.030*
Lymphocytes (%)	3	9.00±2.31 (6-12)	9.00±3.27 (5-14)	0.999
	7	4.57±1.51 (3-7)	5.00±1.16 (4-7)	0.562
	21	5.00±1.53 (3-7)	5.14±1.57 (3-8)	0.866
Macrophages (%)	3	48.00±7.12 (35-56)	44.14±1.68 (41-46)	0.208
	7	35.86±5.58 (30-43)	33.29±4.31 (30-40)	0.354
	21	27.29±4.39 (21-32)	31.14±5.40 (23-37)	0.168
Fibroblasts (%)	3	28.29±6.29 (22-38)	30.71±4.89 (24-36)	0.436
	7	47.86±6.18 (39-55)	46.71±4.07 (39-51)	0.690
	21	64.00±5.57 (57-72)	58.71±5.62 (53-67)	0.102
The extent of granulation tissue (mm^2)	3	1.74±0.13 (1.58-1.93)	1.36±0.25 (1.10-1.80)	0.003*
	7	0.80±0.11 (0.64-0.94)	0.70±0.10 (0.59-0.88)	0.099
	21	0.32±0.07 (0.21-0.42)	0.40±0.06 (0.31-0.50)	0.620
The formation of bone trabeculae (mm^2)	3	-	-	-
	7	0.86±0.13 (0.62-1.01)	0.82±0.13 (0.65-1.01)	0.601
	21	2.89±0.10 (2.77-3.00)	2.42±0.21 (2.00-2.62)	<0.001*

Independent *t*-test was used. *Significance. TBHQ: tert-Butylhydroquinone; SD: Standard deviation

steps (replacement of acute inflammatory cells by chronic types, granulation tissue formation, osteoid formation, and mature bone formation), these days (3, 7, and 21) were considered in this study.

Increased granulation tissue on day 3 was statistically significant in the experimental group compared to the control group. This could indicate the acceleration of wound healing in the presence of TBHQ. The study by Jelenko *et al.* also showed acceleration in the healing of skin burns in the presence of TBHQ.^[14] The findings of this study were also consistent with that of Yoneda *et al.*^[6] In their study, increased granulation tissue was observed in the presence of an antioxidant (coenzyme Q₁₀) in the tooth cavity on the day 3.^[6]

In this study, the extent of bone trabeculation on day 21 was significantly greater in the TBHQ group than in the control group. This finding indicates that the recovery of hard tissue is faster in the presence of TBHQ. Yoneda *et al.* concluded that the antioxidant coenzyme Q₁₀ is more effective on soft tissue repair than on hard tissue repair.^[6] The difference between the findings of this study and the study by Yoneda *et al.* may be due to the difference in the type of antioxidants that were evaluated.

In this study, the neutrophils count on day 3 in the experimental group was lower than the control group. Although this difference was not statistically significant, the reduction in the number of these cells on day 3 showed a reduction of the inflammatory phase and progression of the natural process of wound healing. In addition, in the study by Yoneda *et al.*, the neutrophils count decreased in the presence of antioxidants on day 3.^[6]

In this study, the macrophages were the largest number of cells present on day 3. These cells stimulate the proliferation of fibroblasts through lactate synthesis and are gradually reduced during the process of restoration through the replacement of fibroblasts with these cells.^[15] On day 3 of the study, the extent of angiogenesis was greater in the TBHQ group than in the control group; however, this difference was not statistically significant. Nevertheless, it indicated the natural process of tissue repair in the presence of TBHQ.

On day 7 of the study, a decrease in neutrophils and an increase in fibroblasts counts were observed in the TBHQ group as compared to the control group, but this difference was not statistically significant. The

low volume and concentration of TBHQ in the tooth sockets were perhaps the reasons for the insignificant results of this study. Due to the limitation of budget, it was impossible to determine the maximum TBHQ concentration without toxic effects on the mouth tissues before the study. Because no study was conducted on the effect of TBHQ on tooth socket healing, the concentration used in this study was the maximum acceptable concentration of TBHQ used in the food industry. In this concentration, the TBHQ was in solution form and not paste and this was one of the limitations of this study. This limitation may increase the chance of washing-out the material from socket by blood and saliva. Hence, we decided to decrease the chance of washing-out by 4 h supine position after extraction that has been recommended in Mendes study.^[10] However, by increasing the concentration of TBHQ to the extent that it does not have toxic effects on tissues, wound healing in the tooth socket may be improved. One of the limitations of this study was as follow: the results of this study could be more reliable in a split-mouth design; however, because of the chance of leakage of TBHQ into saliva and reaching to the other side, it has been done in a case-control manner.

It appears that the use of antioxidants in oral and periodontal surgery are the way forward for improving and accelerating healing procedures.

CONCLUSION

Considering the limitations of an experimental study, it can be concluded that TBHQ may enhance the healing of the hard tissue in teeth sockets.

Acknowledgment

Our sincere appreciation goes to the Research Deputy of Rafsanjan University of Medical Sciences for the financial support of this study.

Financial support and sponsorship

Rafsanjan University of Medical Sciences.

Conflicts of interest

The authors of this manuscript declare that they have no conflicts of interest, real or perceived, financial or non-financial in this article.

REFERENCES

1. Pandith H, Zhang X, Liggett J, Min KW, Gritsanapan W, Baek SJ. Hemostatic and wound healing properties of *Chromolaena odorata* leaf extract. *ISRN Dermatol* 2013;21:1-9.

2. Cutando A, Arana C, Gómez-Moreno G, Escames G, López A, Ferrera MJ, *et al.* Local application of melatonin into alveolar sockets of beagle dogs reduces tooth removal-induced oxidative stress. *J Periodontol* 2007;78:576-83.
3. Czesnikiewicz-Guzik M, Konturek SJ, Loster B, Wisniewska G, Majewski S. Melatonin and its role in oxidative stress related diseases of oral cavity. *J Physiol Pharmacol* 2007;58 Suppl 3:5-19.
4. Murthy S, Gautam MK, Goel SH, Purohit V, Sharma H, Goel RK. Evaluation of *in vivo* wound healing activity of *Bacopa monniera* on different wound model in Rats. *Biomed Res Int* 2013;12:1-9.
5. Manke A, Wang L, Rojanasakul Y. Mechanisms of nano particle-induced oxidative stress and toxicity. *Biomed Res Int* 2013;36:1-9.
6. Yoneda T, Tomofuji T, Kawabata Y, Ekuni D, Azuma T, Kataoka K, *et al.* Application of coenzyme Q10 for accelerating soft tissue wound healing after tooth extraction in rats. *Nutrients* 2014;6:5756-69.
7. Bahia PK, Pugh V, Hoyland K, Hensley V, Rattray M, Williams RJ. Neuroprotective effects of phenolic antioxidant tBHQ associate with inhibition of FoxO3a nuclear translocation and activity. *J Neurochem* 2012;123:182-91.
8. Abdel-Wahab MH. Potential neuroprotective effect of t-butylhydroquinone against neurotoxicity-induced by 1-methyl-4-(2'-methylphenyl)-1,2,3,6-tetrahydropyridine (2'-methyl-MPTP) in mice. *J Biochem Mol Toxicol* 2005;19:32-41.
9. Jin W, Ni H, Dai Y, Wang H, Lu T, Wu J, *et al.* Effects of tert-butylhydroquinone on intestinal inflammatory response and apoptosis following traumatic brain injury in mice. *Mediators Inflamm* 2010;2010:502564.
10. Mendes RM, Silva GA, Lima MF, Calliari MV, Almeida AP, Alves JB, *et al.* Sodium hyaluronate accelerates the healing process in tooth sockets of rats. *Arch Oral Biol* 2008;53:1155-62.
11. Sarsour EH, Kumar MG, Chaudhuri L, Kalen AL, Goswami PC. Redox control of the cell cycle in health and disease. *Antioxid Redox Signal* 2009;11:2985-3011.
12. Sen CK, Roy S. Redox signals in wound healing. *Biochim Biophys Acta* 2008;1780:1348-61.
13. Guo S, Dipietro LA. Factors affecting wound healing. *J Dent Res* 2010;89:219-29.
14. Jelenko C, Wheeler ML, Anderson AP, Callaway BD, McKinley JC. Studies in burns: XIV, Healing in burn wounds treated with Ethyl Linoleate alone or in combination with selected topical antibacterial agents. *Ann Surg* 1975;182:562-6.
15. Okeniyi JA, Olubanjo OO, Ogunlesi TA, Oyelami OA. Comparison of healing of incised abscess wounds with honey and EUSOL dressing. *J Altern Complement Med* 2005;11:511-3.