

## Original Article

# Evaluation of myofibroblasts in oral submucous fibrosis and oral squamous cell carcinoma: The pathogenesis and correlation

Piyush Gandhi<sup>1</sup>, Umesh Chandra Prasad<sup>2</sup>

<sup>1</sup>Department of Oral Pathology, Dasmesh Institute of Research and Dental Sciences, Faridkot, Punjab, <sup>2</sup>Department of Oral Pathology, Kanti Devi Dental College, Mathura, Uttar Pradesh, India

## ABSTRACT

**Background:** Oral submucous fibrosis (OSMF) is a chronic debilitating disease of the oral cavity having premalignant potential and unclear pathogenesis. Recently, myofibroblast has been postulated to play an important role in its pathogenesis and in the process of carcinogenesis. The purpose of this study was to evaluate and compare the presence of myofibroblasts in normal mucosa, different grades of OSMF, and oral squamous cell carcinoma (OSCC).

**Materials and Methods:** The present *in vitro* cross-sectional descriptive study sample consisted of three groups, including 40 OSCCs, 40 OSMF, and 10 sections of normal oral epithelium taken as control group. Alpha-smooth muscle actin was used to identify myofibroblasts using immunohistochemical technique.  $P < 0.05$  was taken as statistically significant.

**Results:** The presence of myofibroblasts was significantly higher in OSMF cases when compared with normal epithelium specimens. The presence of myofibroblasts was significantly higher in OSCC compared to OSMF cases. A significant difference was not observed between the different grades of OSCC.

**Conclusion:** These findings favor the possibility that OSMF actually represents an abnormal healing process in response irritation caused by areca nut. A significant increase in myofibroblasts in OSCC as compared to OSMF also highlights the possible role it may play in the malignant transformation of OSMF.

**Key Words:** Alpha-smooth muscle actin, myofibroblast, oral squamous cell carcinoma, oral submucous fibrosis

Received: August 2016  
Accepted: April 2017

Address for correspondence:  
Dr. Piyush Gandhi,  
Department of Oral  
Pathology, Dasmesh  
Institute of Research  
and Dental Sciences,  
Faridkot, Punjab, India.  
E-mail: drpiyushgandhi86@  
yahoo.in

## INTRODUCTION

Oral submucous fibrosis (OSMF) is a chronic debilitating disease of the oral cavity. Although the pathogenesis of the disease is not clearly understood; epidemiological data and evidence strongly suggest an association between areca nut and oral OSMF.<sup>[1]</sup> Fibrosis is often considered as a wound-healing process that has gone out of control

which initially is beneficial but becomes pathogenic if it remains unchecked and will result in extracellular matrix (ECM) remodeling and formation of permanent scar tissue.<sup>[2]</sup> Substantial ECM remodeling and exuberant collagen formation in OSMF has been compared with an excessive scar tissue formation in healing wounds.<sup>[1]</sup> Fibroblasts are the principal cells involved in wound healing and tissue repair. Recent

This is an open access article distributed under the terms of the Creative Commons Attribution-NonCommercial-ShareAlike 3.0 License, which allows others to remix, tweak, and build upon the work non-commercially, as long as the author is credited and the new creations are licensed under the identical terms.

**For reprints contact:** reprints@medknow.com

**How to cite this article:** Gandhi P, Prasad UC. Evaluation of myofibroblasts in oral submucous fibrosis and oral squamous cell carcinoma: The pathogenesis and correlation. Dent Res J 2017;14:314-20.

Access this article online



Website: [www.drj.ir](http://www.drj.ir)  
[www.drjjournal.net](http://www.drjjournal.net)  
[www.ncbi.nlm.nih.gov/pmc/journals/1480](http://www.ncbi.nlm.nih.gov/pmc/journals/1480)

evidence appreciate the notion that the transformation of fibroblast to myofibroblasts is essential for the cells to perform these functions. Myofibroblasts are a unique group of cells with smooth muscle properties and can be identified by the expression of alpha-smooth muscle actin ( $\alpha$ -SMA), and are believed to be primary producers of ECM after injury. Alteration in quantity and functioning myofibroblasts have been implicated in various fibrotic diseases.<sup>[1]</sup> The OSMF has a premalignant potential with the reported risk of malignant transformation being 7%–13%.<sup>[3]</sup>

Squamous cell carcinoma is defined as “a malignant epithelial neoplasm exhibiting squamous differentiation as characterized by the formation of keratin and/or intercellular bridges”.<sup>[4]</sup> The tumor stroma in oral squamous cell carcinoma (OSCC) is associated with the secretion of various cytokines such as transforming growth factor beta-1 from cancerous cells that promote differentiation of fibroblasts into myofibroblasts, neo-angiogenesis, increases the inflammatory cells and increases the expression of mesenchymal markers such as vimentin. Myofibroblasts, in turn, causes tumor growth by the destruction of ECM.<sup>[5]</sup> Recent studies have demonstrated the presence of myofibroblasts in the stroma of head and neck squamous cell carcinomas.<sup>[6]</sup> Recent data show poor prognosis in some tumor types associated with an increase in the presence of myofibroblasts in a neoplastic stroma.<sup>[7]</sup> Literature quotes very few studies of evaluation of myofibroblasts in OSCC and in OSMF. Angadi *et al.* observed higher expression of  $\alpha$ -SMA in OSMF cases in comparison to normal mucosa.<sup>[1]</sup> Etemad-Moghadam *et al.* observed presence of myofibroblasts in the stroma of OSCC but not dysplasia and normal mucosa.<sup>[8]</sup> Therefore, we aim to evaluate the presence of myofibroblasts in OSMF and OSCC, to find the role they play in the pathogenesis of the diseases, by immunohistochemistry (IHC) using  $\alpha$ -SMA antibody, which is considered to be the most reliable marker for myofibroblasts.

## MATERIALS AND METHODS

The study group in the present *in vitro* study comprised 40 specimens of OSMF (20 histological sections of early OSMF [EOSMF] and 20 histological sections of advanced OSMF [AOSMF]), 40 specimens of OSCC (20 histological sections of well-differentiated OSCC (WDO SCC), and

20 histological sections of poorly differentiated OSCC (PDO SCC) and ten specimens of normal oral mucosa (obtained from patients undergoing minor oral surgical procedures such as dental extractions, frenectomy) taken as control from the archives of department of oral pathology. All the OSMF cases were divided into EOSMF and AOSMF based on the criteria given by Pindborg and Sirsat.<sup>[9]</sup> The tissue sections were stained; one with hematoxylin and eosin stain and another with  $\alpha$ -SMA antibody by indirect peroxidase-antiperoxidase IHC methods using monoclonal (1A4) mouse anti-human SMA primary antibody of Leica Biosystems, New Delhi. The slides were coated with poly-L-lysine solution for adhesion of the tissues for IHC procedure.

### Evaluation criteria

Immunostaining was assessed by the evaluation of the staining intensity (SI) and percentage of  $\alpha$ -SMA-positive cells, according to the method used by Etemad-Moghadam *et al.*<sup>[8]</sup> The percentage of immunopositive cells in the noninflammatory and nonendothelial stromal cells in the subepithelial connective tissue of OSMF and nonendothelial and noninflammatory cells at the tumor invasive front of OSCC in 4 high power fields (HPF) and average percentage per HPF was calculated and recorded as: 0% = no positive cells, 1% = 1%–25% positive cells, 2% = 26%–50% positive cells, and 3% = 51%–100% positive cells. SI was evaluated as 0% = when there was no staining; 1% = in parts where positivity was observed only at a magnification of  $\times 400$ ; 2% = in cases where the staining was obvious at  $\times 100$ , but not at  $\times 40$ ; and 3% = in fields where immunopositive cells were seen even at  $\times 40$ . Multiplication of the percentage and intensity scores comprised the staining index (I) of each specimen. This index was classified as: zero = 0, low = 1, 2, moderate = 3, 4, and high = 6–9. Staining index for each group was calculated and compared.

All sections were counted twice to avoid intra-observer variability.

### Statistical analysis

All data analysis was carried out using Statistical Package for Social Science 17 (SPSS, version 17, IBM Analytics) for the descriptive analysis and statistical tests of significance. Kruskal–Wallis test and Mann–Whitney U-test was used to compare the mean scores among the study groups. The level of significance was set at 5% for all tests.

## RESULTS

All sections were counted twice to avoid intra-observer variability, and kappa value came out to be 0.8. Significant results were obtained while comparing the staining index score in OSMF group and the normal control group. However, the comparison between the EOSMF group and AOSMF group as well as between the OSCC group and the normal control group showed significant results. Nonsignificant results were obtained while the mean staining index score in PDOSCC group and WDOSCC group.

## DISCUSSION

Fibrosis is considered as a scarring disease characterized by ECM remodeling and accumulation of scarring ECM proteins disrupting the normal tissue architecture.<sup>[1]</sup> Most of the fibrotic diseases are alike in having a persistent chemical or physical irritant, despite the fact of having distinct etiological and clinical manifestations. These irritants sustain the production of various growth factors, fibrogenic and proteolytic agents, which abnormally remodel the ECM and destroy normal tissue architecture.<sup>[10]</sup>

OSMF is one such disorder manifesting as fibrosis in response to persistent chronic irritation by areca nut chewing resulting in trismus. Angadi *et al.* observed increased the presence of myofibroblasts in OSMF and suggested that arecoline could facilitate the differentiation of myofibroblast from various sources and provided a new insight toward the pathogenesis of OSMF.<sup>[1]</sup>

Inappropriate delay of apoptosis process, and thus increased survival of myofibroblasts activated during the healing process, may be responsible for causing excessive scarring in tissues undergoing fibrosis.<sup>[10]</sup> Recently, the role of myofibroblasts has been studied in OSMF. However, there is paucity in literature that mentions the role of myofibroblasts in the pathogenesis of OSMF. Hence, we evaluated the presence of myofibroblasts in different histological stages of OSMF immunohistochemically using  $\alpha$ -SMA antibody, further to elucidate whether myofibroblasts have any role in pathogenesis and disease progression. Mean and standard deviation of percentage of myofibroblasts score (A), SI score (B), and the final staining index score ( $A \times B$ ) observed in normal control ( $n = 10$ ), EOSMF ( $n = 20$ ), AOSMF ( $n = 20$ ), WDOSCC and PDOSCC ( $n = 20$ ) were calculated [Table 1].

We observed in all the OSMF sections that the staining index of  $\alpha$ -SMA positive cells (myofibroblasts) was significantly higher than the normal controls ( $P < 0.05$ ) [Table 2 and Figure 1]. We also observed that the staining index of  $\alpha$ -SMA positive cells (myofibroblasts) was significantly higher in AOSMF sections when compared to that of EOSMF sections ( $P < 0.05$ ) [Table 3 and Figures 2, 3]. These results were found to be consistent with the results of Angadi *et al.*,<sup>[1]</sup> 2011 and Philip *et al.*,<sup>[11]</sup> 2014, who also found a significant increase in staining index of myofibroblasts in different histological grades of EOSMF and AOSMF [Figures 2 and 3]. Similar findings have been reported in healing wounds, where in early healing stage, only few myofibroblast are present, but large number is seen in later stages.<sup>[12]</sup> The significant increase in myofibroblasts in AOSMF observed in our study supports the hypothesis of Angadi *et al.*, that OSMF might actually represents a failed wound-healing process of the oral mucosa after chronic sustained injury.<sup>[1]</sup> Hence, our observation of the presence of myofibroblasts in OSMF implicate them as one of the significant factors in the pathogenesis of OSMF along with other factors causing fibrosis.

OSMF has been defined by WHO as one of the precancerous conditions with high malignant transformation rate.<sup>[13]</sup> Hence, we also evaluated the presence of myofibroblasts in the stroma of different histological grades of OSCC. We found that staining index of myofibroblasts was positive in all the sections of OSCC and was significantly

**Table 1: Percentage of myofibroblasts score (A), staining intensity score (B) and the final staining index score ( $A \times B$ ) observed in normal control group ( $n=10$ ), early oral submucous fibrosis ( $n=20$ ), advanced oral submucous fibrosis ( $n=20$ ), well differentiated oral squamous cell carcinoma and poorly differentiated oral squamous cell carcinoma ( $n=20$ )**

Groups	Number of specimens	Percentage of myofibroblasts score (A)		Staining intensity score (B)		Staining index score (I), $I=A \times B$	
		Mean	SD	Mean	SD	Mean	SD
Controls	10	0.00	0.00	0.00	0.00	0.00	0.00
EOSMF	20	0.78	0.45	1.40	0.80	1.30	0.80
AOSMF	20	1.90	0.86	2.90	0.79	4.40	1.55
WDOSCC	20	2.90	0.79	2.90	0.79	7.40	2.55
PDOSCC	20	2.94	0.58	2.50	0.60	6.90	2.45

WDOSCC: Well-differentiated oral squamous cell carcinoma; PDOSCC: Poorly-differentiated oral squamous cell carcinoma; SD: Standard deviation; AOSMF: Advanced oral submucous fibrosis; EOSMF: Early oral submucous fibrosis



**Table 2: P value for comparison of percentage of myofibroblasts score (A), staining intensity of the myofibroblasts score (B), and the final staining index score (A × B) between oral submucous fibrosis (n=40) and normal control group (n=10)**

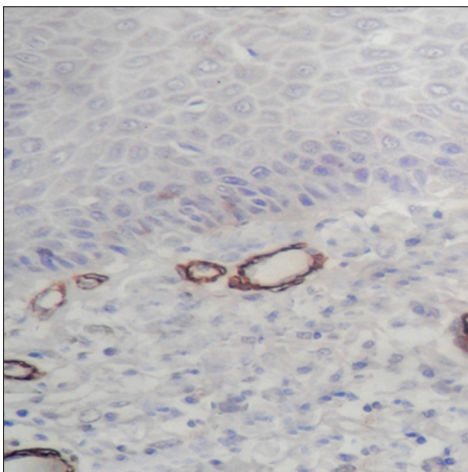
Groups	Number of specimens	P		
		Percentage of myofibroblasts score (A)	Staining intensity score (B)	Staining index score (I), I=A × B
OSMF versus control	45	0.023 (S)	0.028 (S)	0.021 (S)

OSMF: Oral submucous fibrosis; S: Significant

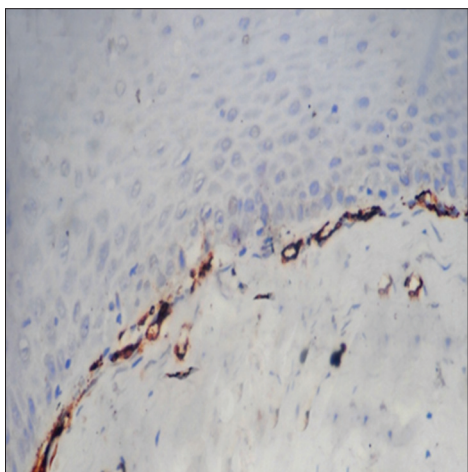
**Table 3: P value for comparison of percentage of myofibroblasts score (A), staining intensity of the myofibroblasts score (B), and the final staining index score (A × B) between early oral submucous fibrosis (n=20) and advanced oral submucous fibrosis (n=20)**

Groups	Number of specimens	P		
		Percentage of myofibroblasts score (A)	Staining intensity score (B)	Staining index score (I), I= A × B
EOSMF versus AOSMF	40	0.041 (S)	0.048 (S)	0.044 (S)

EOSMF: Early oral submucous fibrosis; AOSMF: Advanced oral submucous fibrosis; S: Significant



**Figure 1:** Immunohistochemistry stained section of normal control group showing no myofibroblasts (×40).



**Figure 2:** Immunohistochemistry section of advanced oral submucous fibrosis showing intense staining of myofibroblast in juxtaepithelial region (×40).

higher ( $P < 0.05$ ) as compared to normal control group [Table 4 and Figures 4, 5]. We also compared the myofibroblast staining index between different histological grades of OSCC and observed that out of 20 WDOSCC sections, 14 showed high staining index score and six showed moderate staining index score whereas out of 20 PDOSCC section, 12 showed high staining index and eight showed moderate staining index. However, statistically correlation was found to be nonsignificant ( $P > 0.05$ ) for staining index between WDOSCC and PDOSCC [Table 5]. Our results were consistent with the results obtained by Etemad-Moghadam *et al.*,<sup>[8]</sup> and Kellermann *et al.*<sup>[6]</sup> who did not find any positive correlation between OSCC histological grade differentiation and the observation of myofibroblasts. These findings may suggest that the formation and differentiation of myofibroblasts is induced somewhere in the invasive stage of OSCC, and further increase in severity and differentiation would not affect the number of these cells.

In addition, studies hypothesize that myofibroblasts may act as potential targets in the treatment of malignant disease. These strategies aim at preventing interaction between myofibroblasts and malignant cells including the inhibition of the signaling pathways involved in myofibroblast formation, differentiation, and direct eradication.<sup>[3]</sup>

Although the OSMF is a disorder of connective tissue, it has potential to develop OSCC. Hence, we compared the presence of myofibroblasts in OSMF and OSCC to elucidate whether myofibroblasts have any role in malignant transformation.

**Table 4:** *P* value for comparison of percentage of myfibroblasts score (A), staining intensity of the myfibroblasts score (B), and the final staining index score (A × B) between oral squamous cell carcinoma (*n*=40) and normal control group (*n*=10)

Groups	Number of specimens	<i>P</i>		
		Percentage of myfibroblasts score (A)	Staining intensity score (B)	Staining index score (I), I=A × B
OSCC versus control	50	0.010 (S)	0.019 (S)	0.010 (S)

OSCC: Oral squamous cell carcinoma; S: Significant

**Table 5:** *P* value for comparison of percentage of myfibroblasts score (A), staining intensity of the myfibroblasts score (B), and the final staining index score (A × B) between well-differentiated squamous cell carcinoma (*n*=20) and POSCC (*n*=20)

Groups	Number of specimens	<i>P</i>		
		Percentage of myfibroblasts score (A)	Staining intensity score (B)	Staining index score (I), I=A × B
WDOSCC versus PDSCC	20	0.150 (NS)	0.215 (NS)	0.410 (NS)

NS: Not significant; WDOSCC: Well-differentiated oral squamous cell carcinoma; PDSCC: Poorly differentiated squamous cell carcinoma

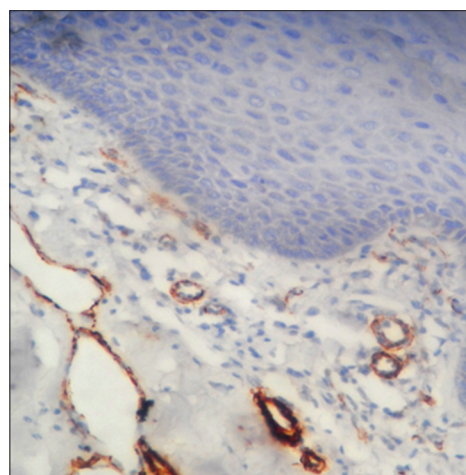
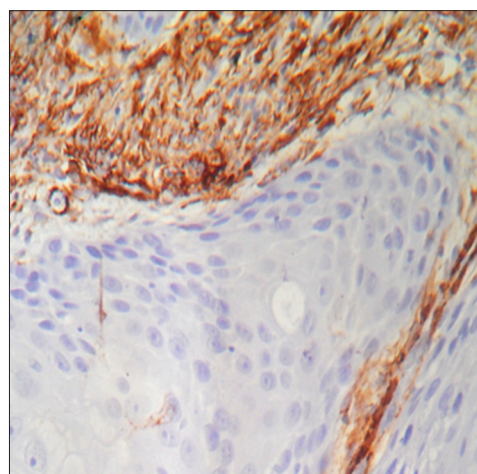
**Table 6:** Percentage of myfibroblasts score (A), staining intensity score (B) and the final staining index score (A × B) observed in oral squamous cell carcinoma (*n*=40) and oral submucous fibrosis (*n*=40)

Groups	Number of specimens	Percentage of myfibroblasts score (A)		Staining intensity score (B)		Staining index score (I), I=A × B	
		Mean	SD	Mean	SD	Mean	SD
OSCC	40	2.40	0.55	2.75	0.50	6.81	2.29
OSMF	40	1.44	0.70	1.97	0.99	2.55	1.77

OSCC: Oral squamous cell carcinoma; OSMF: Oral submucous fibrosis; SD: Standard deviation

We found that OSCC group had highest myfibroblast staining index score than OSMF group which was found to be higher than the normal controls ( $P < 0.05$ ). This progressive increase in the staining index score of myfibroblasts from normal controls to OSMF specimens and OSCC specimens suggests that myfibroblasts may play a possible role in malignant transformation of OSMF where myfibroblast evaluation can be used as a stromal marker [Tables 6 and 7]. However, further research can be carried out to ascertain the precise role of myfibroblasts in malignant transformation of OSMF.

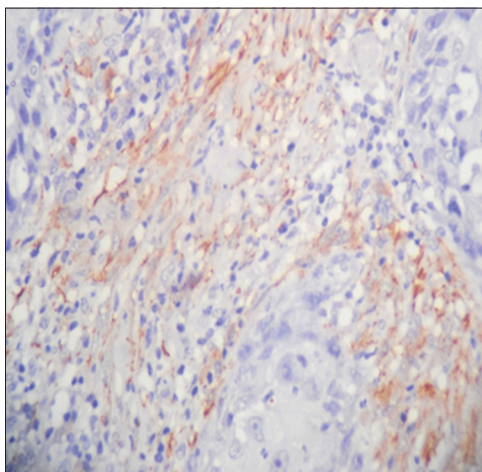
There is still ongoing research to find out the potential pathway through which an epithelial malignancy develops in a primarily connective tissue disorder. Recent data indicate that cancer development and progression is facilitated by interactions between epithelium and reactive connective tissue stroma containing  $\alpha$ -SMA positive myfibroblasts.<sup>[14,15]</sup>

**Figure 3:** Immunohistochemistry stained section of early oral submucous fibrosis showing few myfibroblasts (×40).**Figure 4:** Immunohistochemistry stained section of well-differentiated squamous cell carcinoma showing intense staining of myfibroblasts (×40).

**Table 7: P value for comparison of myofibroblasts score (A), staining intensity of the myofibroblasts score (B), and the final staining index score (A × B) between oral squamous cell carcinoma (n=40) and oral submucous fibrosis (n=40)**

Groups	Number of specimens	P		
		Percentage of myofibroblasts score (A)	Staining intensity score (B)	Staining index score (I), I=A × B
OSCC versus OSMF	80	0.001 (S)	0.002 (S)	0.001 (S)

S: Significant; OSCC: Oral squamous cell carcinoma; OSMF: Oral submucous fibrosis



**Figure 5:** Immunohistochemistry stained section of poorly-differentiated squamous cell carcinoma showing moderate staining of myofibroblasts (x40).

Animal study models provide proof that fibrotic and wounded tissues have the malignant potential suggesting the presence of oncogenic factors in both the afflicted tissues. Comparing this with OSMF, the possibility of epithelial–mesenchymal interactions resulting in an alteration in epithelial phenotype predisposing to the development of carcinoma in OSMF has been reported.<sup>[16,17]</sup> The possible role of myofibroblast in malignant transformation of OSMF requires further research.

## CONCLUSION

Myofibroblasts play a pivotal role in the pathogenesis of OSMF as well as its progression and the invasive behavior of OSCC. Its significant increase in OSCC as compared to OSMF also highlights the possible role it might play in the malignant transformation of OSMF. Hence, we suggest that myofibroblasts can be used as a stromal marker for observing the severity and progression of the OSMF and OSCC. However, further research can be carried out to understand the exact mechanisms by which myofibroblasts play a role in the pathogenesis of OSMF, behavior of OSCC

and their potential for malignant transformation of the OSMF.

## Financial support and sponsorship

Nil.

## Conflicts of interest

The authors of this manuscript declare that they have no conflicts of interest, real or perceived, financial or non-financial in this article.

## REFERENCES

1. Angadi PV, Kale AD, Hallikerimath S. Evaluation of myofibroblasts in oral submucous fibrosis: Correlation with disease severity. *J Oral Pathol Med* 2011;40:208-13.
2. Wynn TA. Common and unique mechanisms regulate fibrosis in various fibroproliferative diseases. *J Clin Invest* 2007;117:524-9.
3. Angadi PV, Rao SS. Areca nut in pathogenesis of oral submucous fibrosis: Revisited. *Oral Maxillofac Surg* 2011;15:1-9.
4. Rajendra R, Shivapathasundharam B, editors. *Shafer's Textbook of Oral Pathology*. 7<sup>th</sup> ed. India: Elsevier; 2006.
5. Seifi S, Shafaei S, Shafiq E, Sahabi SM, Ghasemi H. Myofibroblast stromal presence and distribution in squamous epithelial carcinomas, oral dysplasia and hyperkeratosis. *Asian Pac J Cancer Prev* 2010;11:359-64.
6. Kellermann MG, Sobral LM, da Silva SD, Zecchin KG, Graner E, Lopes MA, *et al*. Mutual paracrine effects of oral squamous cell carcinoma cells and normal oral fibroblasts: Induction of fibroblast to myofibroblast transdifferentiation and modulation of tumor cell proliferation. *Oral Oncol* 2008;44:509-17.
7. Lúcio PS, Cavalcanti AL, Alves PM, Godoy GP, Nonaka CF. Myofibroblasts and their relationship with oral squamous cell carcinoma. *Braz J Otorhinolaryngol* 2013;79:112-8.
8. Etemad-Moghadam S, Khalili M, Tirgary F, Alaeddini M. Evaluation of myofibroblasts in oral epithelial dysplasia and squamous cell carcinoma. *J Oral Pathol Med* 2009;38:639-43.
9. Pindborg JJ, Sirsat SM. Oral submucous fibrosis. *Oral Surg Oral Med Oral Pathol* 1966;22:764-79.
10. Wynn TA. Cellular and molecular mechanisms of fibrosis. *J Pathol* 2008;214:199-210.
11. Philip T, Kumar TD, Rajkumar K, Karthik KR, Priyadharsini N, Kumar AR. Immunohistochemical evaluation of myofibroblasts using alpha-smooth muscle actin in oral submucous fibrosis. *SRM J Res Dent Sci* 2014;4:243-7.
12. Darby I, Skalli O, Gabbiani G. Alpha-smooth muscle actin is

- transiently expressed by myofibroblasts during experimental wound healing. *Lab Invest* 1990;63:21-9.
13. Mahomed F. Oral submucous fibrosis – A potentially malignant condition of growing concern. *SADJ* 2012;67:562, 564-5.
  14. Murti PR, Bhonsle RB, Pindborg JJ, Daftary DK, Gupta PC, Mehta FS. Malignant transformation rate in oral submucous fibrosis over a 17 year period. *Community Dent Oral Epidemiol* 1985;13:340-1.
  15. Desmoulière A, Guyot C, Gabbiani G. The stroma reaction myofibroblast: A key player in the control of tumor cell behavior. *Int J Dev Biol* 2004;48:509-17.
  16. Xouri G, Christian S. Origin and function of tumor stroma fibroblasts. *Semin Cell Dev Biol* 2010;21:40-6.
  17. Radisky DC, Kenny PA, Bissell MJ. Fibrosis and cancer: Do myofibroblasts come also from epithelial cells via EMT? *J Cell Biochem* 2007;101:830-9.