

Original Article

Zygoma implants in oral rehabilitation: A review of 28 cases

Rowland Agbara^{1,2#}, Elizabeth Goetze^{1#}, Felix Koch¹, Wilfred Wagner¹

¹Department of Oral, Maxillofacial and Plastic Surgery, University Medical Center, Johannes Gutenberg-University, Mainz, Germany,

²Department of Dental and Maxillofacial Surgery, Oral and Maxillofacial Surgery Unit, Jos University Teaching Hospital, Plateau State, Nigeria

#Rowland Agbara and Elizabeth Goetze are equal authors

ABSTRACT

Background: The functional and esthetic rehabilitation of patients with atrophic maxilla or posterior maxillary defect is often challenging. The aim of this study was to determine patient demographics, indications, success rate, and complications following the use of zygoma implants.

Materials and Methods: All patients who had zygoma implant placement in our clinic between 1998 and 2013 were retrospectively assessed for implant outcome. Data were analyzed using Statistical Package for the Social Sciences (SPSS) version 16 and Microsoft Excel 2007 test for significance (ρ) using Pearson's Chi-square (χ^2) set at 0.05.

Results: A total of 28 patients consisting of 22 females (78.6%) and 6 males (21.4%) were treated, and their age ranged from 41 years to 83 years with a mean age of 60.3 ± 10.6 years. The main indication for zygoma implant placement was atrophic maxilla 12 (42.9%). In the prosthetic rehabilitation of the patients, 2 had epithetic prostheses, and 2 had obturators while 18 patients had conventional removable dental prostheses. Four patients (14.3%) had perimplantitis and one implant was accidentally placed into the maxillary sinus. A cumulative success rate of 88.1% was obtained from this retrospective analysis.

Conclusion: A cumulative success rate of 88.1% reported in this study is lower than the reports from other studies. The difference in success rates may be related to different criteria for assessment of zygoma implant success and to the difference in inclusion criteria and follow-up period.

Key Words: Maxilla, prostheses and implants, rehabilitation

Received: January 2016
Accepted: September 2017

Address for correspondence:

Dr. Rowland Agbara,
Department Oral,
Maxillofacial and Plastic
Surgery, University
Medical Center, Johannes
Gutenberg-University, Mainz,
Germany.
E-mail: row_prof@yahoo.
com

INTRODUCTION

In the functional and esthetic rehabilitation of patients with atrophic maxilla or posterior maxillary defect, several options exist. These options include total/segmental bone onlays or inlays, Le Fort 1 osteotomy with interpositional bone grafts, grafting of the maxillary sinus with autogenous bone and/or bone substitutes, placement of implants without bone grafting in anatomical buttresses (frontomaxillary, frontozygomatic, palatal vault, pterygomaxillary buttress,

etc.), use of short dental implants, and application of distraction osteogenesis technique.^[1] Bone grafting procedures to augment resorbed maxilla or posterior maxillary defects are associated with donor-site morbidity, and often involve a two-stage procedure with delayed implant placement.^[2] This translate to longer waiting time for the patient with regard to their rehabilitation, increased economic loss to the patient and their employer, and increased cost of treatment.

This is an open access article distributed under the terms of the Creative Commons Attribution-NonCommercial-ShareAlike 3.0 License, which allows others to remix, tweak, and build upon the work non-commercially, as long as the author is credited and the new creations are licensed under the identical terms.

For reprints contact: reprints@medknow.com

How to cite this article: Agbara R, Goetze E, Koch F, Wagner W. Zygoma implants in oral rehabilitation: A review of 28 cases. Dent Res J 2017;14:370-5.

Access this article online



Website: www.drj.ir
www.drjjournal.net
www.ncbi.nlm.nih.gov/pmc/journals/1480

Zygomatic implants remain an important nongrafting option in the functional and esthetic rehabilitation of patients with atrophic maxilla or posterior maxillary defect following tumor ablative surgery or trauma. Since its first design by Nobel Biocare and its introduction by Brånemark in 1988, the use of zygomatic implants has reduced the number of surgeries and treatment time required for the successful rehabilitation of such patients.^[3] Zygoma implants are used in situations where a posterior maxillary alveolar atrophy or defect exists but with adequate quantity and quality of bone in the anterior region to support conventional dental implants.^[4] The classification system proposed by Misch and Jucan be used in patient selection, and class A or B in the anterior maxillary region existing with class C or D in the posterior maxillary region is ideal for the use of zygomatic implants.^[5]

The available length for zygoma implants range from 30 mm to 52.5 mm and anchorage is derived from the zygoma bone with either a palatal emergence or emergence at the center of the resorbed alveolar ridge.^[6,7] The various anatomic-guided zygomatic implant pathways between the zygoma and the alveolar crest has been classified into group 04 with group 1 constituting about 49% of the reviewed implants.^[8]

However, despite the advantages of zygoma implant use when indicated in patients, certain disadvantages are associated with its use. Difficult surgical access that requires considerable expertise, risk of orbital injury, speech problems with palatal emergence, postoperative sinusitis, oroantral fistula, and periorbital and conjunctival hematoma are some of the documented problems associated with zygoma implant use.^[6,9]

Few studies on zygoma implants have previously been published in the literature. The aim of this retrospective study was to determine patient demographics, indications, success rate, and complications associated with zygoma implants placed in our department over a 16-year period.

MATERIALS AND METHODS

Patients

Twenty-eight patients who had zygoma implants placed at the Department of Oral, Maxillofacial, and Plastic Surgery, Johannes Gutenberg University Medical Center, Mainz, Germany, between 1998

and 2013 were retrospectively assessed for implant outcome.

The case notes and radiographs of the patients from the time of treatment to the last follow-up were carefully studied. Parameters retrieved included age at implant insertion, indication, history of systemic disease, smoking, radiotherapy and chemotherapy, length/number/location of zygoma and regular dental implants, number of failed zygoma implants, and complications.

Preoperative assessment

Patients had clinical and radiological assessment to rule out the presence of uncontrolled systemic disease, local infections, and other pathologies, and to assess bone quantity and quality. Radiological assessment was achieved using the panoramic view and computed tomography.

Surgical and prosthetic protocol

All zygoma implants were placed under general anesthesia supplemented by local injection of adrenaline at the site of incision. Placement of zygoma implants was done according to the Brånemark protocol with bone preparation performed under copious saline irrigation. Delayed prosthetic protocol was used for all the patients, and the patients were rehabilitated with removable prosthetic appliances.

Criteria for success and statistical analysis

A zygoma implant was regarded as successful if it is in position in the mouth and functional (satisfactorily supporting a prosthesis) in the absence of mobility, infection, pain, or fracture.

Data were analyzed using Statistical Package for the Social Sciences (SPSS) version 16 (SPSS Inc., Chicago, IL, USA) and Microsoft Excel 2007 (Microsoft, Redmond, WA, USA). Results from descriptive statistics were represented in the form of tables and charts with test for significance (*P*) set at 0.05.

RESULTS

A total of 28 patients were rehabilitated with 42 zygoma implants under the period reviewed. The patients age range from 41 years to 83 years with a mean age of 60.3 ± 10.6 years. The age groups 51–60 and 61–70 years constituted the largest (28.6% each) population of the patients rehabilitated with zygoma implants. There were 22 females and 6 males, giving a male to female ratio of 1:3.7. Of these patients,

2 (7.14%) were active smokers, 4 (14.29%) had comorbid systemic conditions (hypertension in 2 patients, epilepsy in 1 patient, hyperparathyroidism in 1 patient, and a combination of diabetes, hypertension, and renal disease in 1 patient), and 5 (17.86%) had radiotherapy.

The indications for zygoma implant placement were maxillary defect following tumor resection - 9 (32.1%), and atrophic maxilla - 12 (42.9%) [Figure 1]. In 7 (25%) patients, the indication was not stated. Fourteen patients had unilateral zygoma implants insertion while an equivalent number had bilateral insertion. There was no statistically significant relationship between the age of the patients and number of zygoma implant placed ($P = 0.454$). The upper right first molar region was the most common site of implant insertion. The zygoma implant length used range from 35 mm to 50.4 mm with the implant length 45 mm (17.9%) been the most frequently used [Table 1]. There was no statistically significant relationship between the sex of the patients and zygoma implant length used ($P = 0.513$). A two-stage protocol was used for all zygoma implants placed. Assessment of marginal bone loss around zygoma implants over time was difficult due to implant orientation.

Regular dental implants were used in conjunction with zygoma implants in patient's rehabilitation [Figure 2]. A total of 123 regular dental implants were placed in the maxilla, and this consisted of 109 (88.6%) standard dental implants and 14 (11.4%) short dental implants. In the prosthetic rehabilitation of the patients, 2 (7.1%) had epithetic prostheses, 2 (7.1%) had obturators, while 18 (64.3%) patients had conventional removable dental prostheses. There was no information on prosthetic rehabilitation in 6 (21.4%) patients.

Follow-up of patients ranged from 5 to 163 months with a mean follow-up period of 51.7 months. There was no record of maxillary sinusitis. However, 4 patients (14.3%) had perimplantitis, and none of this occurred in patients who are smokers or who had radiotherapy. In one patient, the zygoma implant was accidentally placed into the maxillary sinus. A total of 5 (11.9%) implants were considered to have failed. Three of the failed implants [Figure 3] were extracted, while 2 were in the mouth but nonfunctional (sleeping implants).

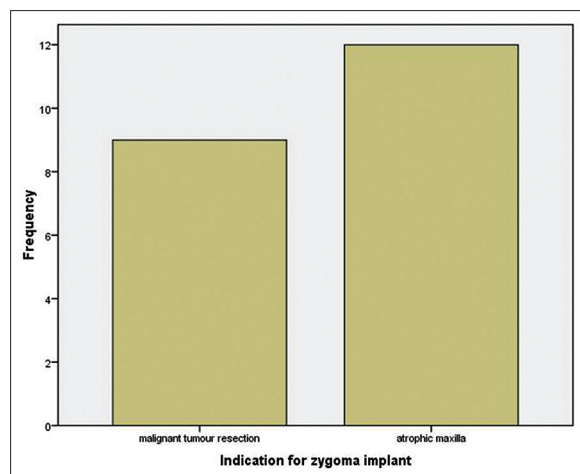


Figure 1: Indications for zygoma implant placement.

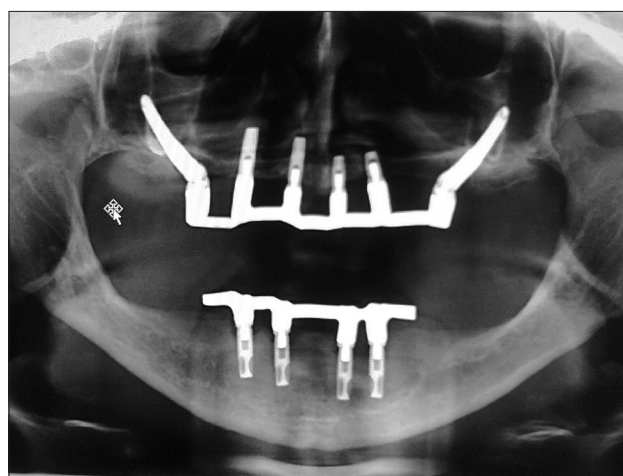


Figure 2: Zygoma implants with conventional dental implants in maxilla.



Figure 3: Extracted zygoma implant following perimplantitis.

DISCUSSION

Reduction in maxillary bone quantity may occur as a result of prolonged edentulism, tumor resection, trauma, or infection. Rehabilitation of the patients with reduced bone quantity can be quite challenging.

Table 1: Characteristics and outcome of zygoma implant placed

Year of implant placement	Zygoma implant length (mm)	Site(s) of placement	Year extracted	Perimplantitis
1998	50	27	-	Yes
1998	35/35	16/26	2001/2003	-
1999	40	16	-	-
1999	45	26	-	Yes
1998	40/40	16/26	-	-
1998	35	26	-	-
1999	40	26	-	-
1998	35/35	15/25	1999	Yes
1998	35	26	-	-
2000	45/40	16/26	-	-
1998	50/40	16/26	-	-
1998	35/35	16/26	-	-
1999	35/45	15/25	-	-
1999	45	26	-	-
1999	40/45	16/26	-	-
1999	40/35	16/26	-	Yes
1998	45/45	15/25	-	-
1999	50/40	15/25	-	-
1998	45	26	-	-
1999	35	26	-	-
1999	50	15	-	-
1999	40/45	16/26	-	-
2005	45	16	-	-
2005	40	26	-	-
2006	40/35	16/26	-	-
2013	47.5	26	-	-
2001	40/40	16/26	-	-
2000	45	16	-	-

The use of zygoma implants provides an acceptable nongrafting option in patient's rehabilitation.

In this retrospective study, the main indication for the insertion of zygoma implants was atrophic maxilla (42.9%). This is similar to findings from other studies.^[2,3,6,10] Zygoma implants were successfully used in patients of different age group in this analysis. Generally, the bone of elderly patients has been found to be less vascularized and to have reduced number of osteocytes;^[11] this may affect osseointegration. However, studies^[12,13] have shown success rates of implants in elderly patients that are comparable to that seen in younger patients. About 50% of the patients rehabilitated in this study were elderly (>60 years) and none of the implant failure occurred in this age group. Despite the presence of comorbid conditions in 4 of the patients reviewed, no implant failure was recorded in this group with systemic disease. The influence of comorbid conditions such as diabetes mellitus and epilepsy may be direct (from the disease itself) or indirect (as a result of medications such as phenytoin used in epilepsy and which is associated with gingival hyperplasia).

All implants were placed under general anesthesia supplemented by adrenaline containing local anesthesia at the surgical site to reduce hemorrhage (as a result of the local vasoconstricting property). General anesthesia has remained the major anesthetic technique for zygoma implant placement.^[2,14] This technique is safer and provides better comfort for the patient.^[15,16] However, Zanette reported two cases of zygoma implants placed under regional anesthesia and conscious sedation without complications. Unlike general anesthesia, regional anesthesia can be performed in the dental office, but this technique requires appropriate patient selection, skill and experience, and maintenance of operating room standards to minimize complications.^[17]

In this retrospective analysis, the two-stage protocol was used for rehabilitation of all the patients. The two-stage protocol is the most frequently reported.^[4,6,18] In the two-stage protocol, abutments are placed between 5 and 8 months after zygoma implant placement.^[2] The longer surgical step involved in the two-stage protocol before implant loading is a disadvantage both to the patient and the

clinician in terms of cost and comfort. The one-stage protocol (immediate loading) has been reported in other studies.^[5,19,20] It has the advantages of reducing treatment time and patients discomfort, increasing masticatory function and improving the psychological condition of the patient.^[21] Success with immediate loading requires careful patient selection and high initial primary stability.^[5]

A cumulative success rate of 88.1% reported in this study is lower than the reports from other studies. A cumulative survival rate of 96.3% was reported^[4] in a 36 months follow-up review, while a cumulative success rate of 95.1% was reported^[22] in a 10-year follow-up review. Similarly, a survival rate of 100%^[10] has been documented. However, a lower survival rate of 82%^[23] compared to our findings has previously been reported. The difference in the various outcomes may be related to different criteria for assessment of survival/success rate and to the difference in the follow-up periods. No major complication was reported in this study. Other studies^[2,4,6] reported suborbital hematoma, sinusitis, fistula formation, and infraorbital nerve paresthesia as some of the complications encountered.

CONCLUSION

The use of zygoma implants provide a satisfactory nongrafting option for rehabilitation of the patients with maxillary atrophy or defect. However, there is a need to use a common well-defined terminology (survival rate or success rate) in assessing outcome following implant placement. This will allow for comparison of data more accurately.

Financial support and sponsorship
Nil.

Conflicts of interest

The authors of this manuscript declared that they have no conflicts of interest, real or perceived, and financial or nonfinancial in this article.

REFERENCES

- Prithviraj DR, Vashisht R, Bhalla HK, Prithvi S, Suresh P, Sharma D. A review of management options for rehabilitation of posterior atrophic maxilla with implants. *J Dent Implants* 2013;13:35-41.
- Becktor JP, Isaksson S, Abrahamsson P, Sennerby L. Evaluation of 31 zygomatic implants and 74 regular dental implants used in 16 patients for prosthetic reconstruction of the atrophic maxilla with cross-arch fixed bridges. *Clin Implant Dent Relat Res* 2005;7:159-65.
- Urgell JP, Gutiérrez VR, Escoda CG. Rehabilitation of atrophic maxilla: A review of 101 zygomatic implants. *Med Oral Patol Oral Cir Bucal* 2008;13:E363-70.
- Kahnberg KE, Henry PJ, Hirsch JM, Ohnell LO, Andreasson L, Brånemark PI, *et al.* Clinical evaluation of the zygoma implant: 3-year follow-up at 16 clinics. *J Oral Maxillofac Surg* 2007;65:2033-8.
- Mozzati M, Monfrin SB, Pedretti G, Schierano G, Bassi F. Immediate loading of maxillary fixed prostheses retained by zygomatic and conventional implants: 24-month preliminary data for a series of clinical case reports. *Int J Oral Maxillofac Implants* 2008;23:308-14.
- Ahlgren F, Størksen K, Tornes K. A study of 25 zygomatic dental implants with 11 to 49 months' follow-up after loading. *Int J Oral Maxillofac Implants* 2006;21:421-5.
- Aparicio C, Ouazzani W, Aparicio A, Fortes V, Muela R, Pascual A, *et al.* Extrasinus zygomatic implants: Three year experience from a new surgical approach for patients with pronounced buccal concavities in the edentulous maxilla. *Clin Implant Dent Relat Res* 2010;12:55-61.
- Aparicio C. A proposed classification for zygomatic implant patient based on the zygoma anatomy guided approach (ZAGA): A cross-sectional survey. *Eur J Oral Implantol* 2011;4:269-75.
- Block MS, Haggerty CJ, Fisher GR. Nongrafting implant options for restoration of the edentulous maxilla. *J Oral Maxillofac Surg* 2009;67:872-81.
- Peñarrocha M, García B, Martí E, Boronat A. Rehabilitation of severely atrophic maxillae with fixed implant-supported prostheses using zygomatic implants placed using the sinus slot technique: Clinical report on a series of 21 patients. *Int J Oral Maxillofac Implants* 2007;22:645-50.
- van Steenberghe D, Quirynen M, Molly L, Jacobs R. Impact of systemic diseases and medication on osseointegration. *Periodontol* 2000 2003;33:163-71.
- Bass SL, Triplett RG. The effects of preoperative resorption and jaw anatomy on implant success. A report of 303 cases. *Clin Oral Implants Res* 1991;2:193-8.
- Bryant SR, Zarb GA. Osseointegration of oral implants in older and younger adults. *Int J Oral Maxillofac Implants* 1998;13:492-9.
- Aparicio C, Ouazzani W, Hatano N. The use of zygomatic implants for prosthetic rehabilitation of the severely resorbed maxilla. *Periodontol* 2000 2008;47:162-71.
- Zanette G. Zygomatic implants performed under regional anaesthesia and conscious sedation. *WebmedCentral Dent* 2012;3:1-7.
- Sharma A, Rahul GR. Zygomatic implants/fixture: A systematic review. *J Oral Implantol* 2013;39:215-24.
- Melloni C. Anesthesia and sedation outside the operating room: How to prevent risk and maintain good quality. *Curr Opin Anaesthesiol* 2007;20:513-9.
- Al-Nawas B, Wegener J, Bender C, Wagner W. Critical soft tissue parameters of the zygomatic implant. *J Clin Periodontol* 2004;31:497-500.
- Bedrossian E, Rangert B, Stumpel L, Indresano T. Immediate function with the zygomatic implant: A graftless solution for the

- patient with mild to advanced atrophy of the maxilla. *Int J Oral Maxillofac Implants* 2006;21:937-42.
20. Chow J, Hui E, Lee PK, Li W. Zygomatic implants-Protocol for immediate occlusal loading: A preliminary report. *J Oral Maxillofac Surg* 2006;64:804-11.
 21. Migliorança RM, Sotto-Maior BS, Senna PM, Francischone CE, Del Bel Cury AA. Immediate occlusal loading of extrasinus zygomatic implants: A prospective cohort study with a follow-up period of 8 years. *Int J Oral Maxillofac Surg* 2012;41:1072-6.
 22. Aparicio C, Manresa C, Francisco K, Ouazzani W, Claros P, Potau JM, *et al.* The long-term use of zygomatic implants: A 10-year clinical and radiographic report. *Clin Implant Dent Relat Res* 2014;16:447-59.
 23. Landes CA. Zygoma implant-supported midfacial prosthetic rehabilitation: A 4-year follow-up study including assessment of quality of life. *Clin Oral Implants Res* 2005;16:313-25.