

Original Article

Assessment of the anterior loop of mental nerve in an Iranian population using cone beam computed tomography scan

Mitra Karbasi Kheir¹, Mahnaz Sheikhi²

¹Department of Oral and Maxillofacial Radiology, School of Dentistry, Islamic Azad University Isfahan (Khorasgan Branch), ²Dental Research Center and Department of Oral and Maxillofacial Radiology, School of Dentistry, Isfahan University of Medical Sciences, Isfahan, Iran

ABSTRACT

Background: The anterior loop is an important structure in the interforaminal area of the mandible. The aim of the present study was to assess the prevalence and length of the anterior loop of mental nerve using cone beam computed tomography (CBCT) scan and to compare the differences between age, gender, and side.

Materials and Methods: A total of 180 projections were analyzed in different sectional planes. The inferior alveolar nerve was determined. To measure the length of anterior loop in tangential plane, two parallel lines from the anterior point of mental foramen and anterior point of anterior loop were drawn. The distance between these two lines was measured by drawing a perpendicular line on them. The data were analyzed by SPSS (version 22). McNemar's test, Chi-square test, and *t*-test were performed to compare the significance of findings regarding side, age, and gender. $P < 0.05$ was considered statistically significant.

Results: The results showed that 32.8% of images had anterior loop. The mean lengths of anterior loop in the right and left sides were 2.69 mm (standard deviation [SD] = 1.56) and 2.36 mm (SD = 1.16), respectively. There were no statistically significant differences between the mean lengths of the anterior loop in both sides ($P = 0.18$).

Conclusion: Great care is required when placing implants in proximity to mental foramen to avoid anterior loop injury. Because of the variations of anterior loop length in each patient, a fixed distance anterior to the mental foramen is not safe, and the anterior loop length should be determined for each individual. The use of CBCT provides accurate measurements of the length of anterior loop.

Key Words: Anterior loop of the inferior alveolar nerve, cone beam computed tomography-scan, implant

Received: October 2016
Accepted: July 2017

Address for correspondence:

Dr. Mitra Karbasi Kheir,
Department of Oral and
Maxillofacial Radiology, School
of Dentistry, Islamic Azad
University Isfahan (Khorasgan
Branch), Isfahan, Iran.
E-mail: mastoor28@
gmail.com

INTRODUCTION

The anterior loop is an extension of the inferior alveolar nerve, anterior to the mental foramen, which loops back to exit the mental foramen. This structure is important in determining a safe interforaminal area for the placement of dental endosseous implants and other surgeries such as open reduction of a mandibular

fracture and genioplasty to prevent neurosensory disturbances. Several studies have been performed to detect and measure the anterior loop length using different diagnostic methods on panoramic radiographs; cone beam computed tomography (CBCT) and CT scans of patients and cadaver.^[1-5] Studies have shown panoramic radiographs are not reliable because of high

This is an open access article distributed under the terms of the Creative Commons Attribution-NonCommercial-ShareAlike 3.0 License, which allows others to remix, tweak, and build upon the work non-commercially, as long as the author is credited and the new creations are licensed under the identical terms.

For reprints contact: reprints@medknow.com

How to cite this article: Kheir MK, Sheikhi M. Assessment of the anterior loop of mental nerve in an Iranian population using cone beam computed tomography scan. Dent Res J 2017;14:418-22.

Access this article online



Website: www.drj.ir
www.drjjournal.net
www.ncbi.nlm.nih.gov/pmc/journals/1480

rates of false positive or false negative interpretations, so CT scans and CBCT are recommended before the surgeries in interforaminal region. Among them, CBCT is preferred because of lower radiation doses.^[3,4,6] Because of lack of studies on Iranian population, the present study was conducted to assess the prevalence and length of the anterior loop of mental nerve using CBCT and to compare the differences between age, gender, and side.

MATERIALS AND METHODS

A total of 180 CBCT images, taken from the patients for diagnostic purposes in the Department of Maxillofacial Radiology at Isfahan school of dentistry from 2010 to 2015, were analyzed by two maxillofacial radiologists on an LG LED computer viewer (E2042C, Korea) using Sirona Galelio's software. The images were divided between the two maxillofacial radiologists. For inter-rater reliability, one-third of the images which had been checked by one of them were randomly chosen and checked by another one, and then Kappa and interclass correlation coefficient were calculated. All CBCT images were taken by Sirona Orthophos, GALILEOS version 1.7, (Sirona, Germany) with a flat panel detector. The adjusted scan parameters were 85 kVp and 10–42 mA, depending on the size of patients. The exposure time was 14 s, the effective exposure time was 2–6 s and the voxel size was 0.3 mm × 0.3 mm × 0.3 mm. The inclusion criterion consisted of the patients older than 18 years whose skeletal growth was completed (partial or full edentulous and dentate patients). The exclusion criterion comprised of the patients with pathologic lesions in the mandible.

CBCT projections were analyzed in different sectional planes (tangential, cross-sectional, and axial). The inferior alveolar nerve of mandible was determined by the nerve option of GALILEOS software on both sides of each projection. To measure the length of anterior loop in tangential plane, two parallel lines from the anterior point of mental foramen and anterior point of anterior loop were drawn using length measuring option on Galelio software. The distance between these two lines was measured by drawing a perpendicular line on them and was considered as the length of anterior loop [Figure 1]. Figure 2 shows anterior loop, mental foramen, and inferior alveolar nerve. Comparisons were made between genders, sides, and mean ages.

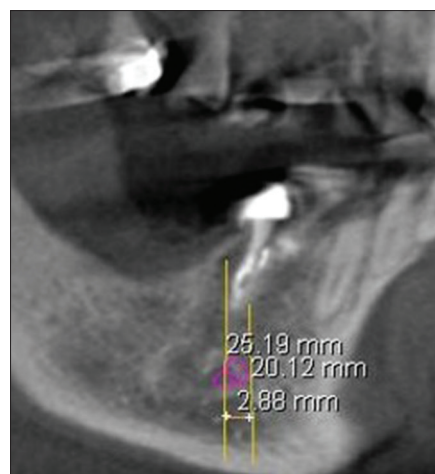


Figure 1: The length of anterior loop on tangential plane.

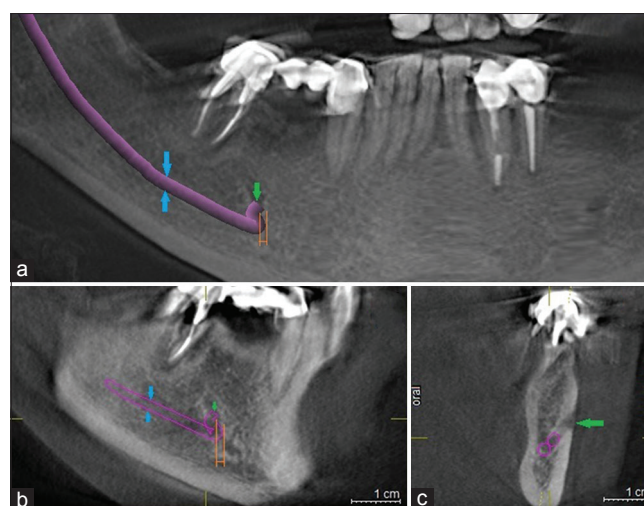


Figure 2: Green arrow: Mental foramen, blue arrows: Inferior alveolar nerve, orange lines: Anterior loop of mental nerve in (a): Panorama view, (b): Tangential view, (c): Cross-sectional view.

Statistical analysis

The data were analyzed by the statistical package for social sciences (SPSS) (version 22, SPSS Inc., Chicago, IL, USA). Descriptive statistics were applied where appropriate. McNemar's test, Chi-square test, and *t*-test were performed to compare the significance of findings regarding side, age, and gender. $P < 0.05$ was considered statistically significant.

RESULTS

From 180 CBCT images, 84 and 96 images belonged to men and women, respectively. The mean age of the patients was 48.6 years. There were 75% partial edentulous, 17.2% full edentulous, and 7.8% dentate cases in the right side and 75% partial edentulous, 16.7% full edentulous, and 8.3% dentate cases in the

left side. Mental foramen was present in both sides in all of the images.

The Presence of anterior loop

A total of 59 (32.8%) images had the anterior loop and 121 (67.2%) images had no anterior loop on both right and left sides. McNemar's test showed no statistically significant differences between the right and left sides in terms of the presence of anterior loop ($P = 0.99$). Forty two images had bilateral anterior loop.

The frequencies of the presence of anterior loop in both genders in the right and left sides are shown in Table 1. The results of Chi-square test did not show significant differences between the presence of anterior loop and gender (the right side $P = 0.64$ and the left side $P = 0.43$).

In the right side, the mean age of samples with anterior loop was 47 (standard deviation [SD] = 13.17) and that of the samples without anterior loop was 49 (SD = 14.23). The results of t -test did not show a statistically significant difference between the presence of anterior loop and age in the right side ($P = 0.45$). In the left side, the mean age of samples with anterior loop was 46 (SD = 12.44) and that of the samples without anterior loop was 49 (SD = 14.50). The results of t -test did not show a statistically significant difference between the presence of anterior loop and age in the right side ($P = 0.27$).

The results of Kappa coefficient between two observers were: Kappa = 1.00 in the right side ($P < 0.001$) and Kappa = 1.00 in the left side ($P < 0.001$).

Length of anterior loop

The mean length of anterior loop in the right side was 2.69 mm (SD = 1.56), (the minimum length = 0.44 mm and the maximum length = 7.52 mm). In the left side, the mean

length of anterior loop was 2.36 mm (SD = 1.16), (the minimum length = 0.68 mm and the maximum length = 6.19 mm). The findings of t -test did not show statistically significant differences between the mean lengths of anterior loop in both sides ($P = 0.18$).

The mean lengths of anterior loop in both genders in the right and left sides are shown in Table 1. The findings of t -test did not show statistically significant differences between the lengths of anterior loop and genders (the right side $P = 0.33$, the left side $P = 0.62$).

There were no statistically significant differences between the mean age of samples and the mean length of anterior loop (right side: $R = 0.150$, $P = 0.26$ and left side: $R = -0.146$, $P = 0.27$).

The results of interclass correlation coefficient (ICC) between two observers were: ICC = 1.00 in the right side ($P < 0.001$) and ICC = 1.00 in the left side ($P < 0.001$).

DISCUSSION

The successful placement of dental implants depends on proper diagnosis and pretreatment planning. The anterior loop is an important structure in the interforaminal area of mandible. Great care is required in surgeries of this area to prevent mental nerve injury. The anterior loop has been evaluated by different radiographic methods, including panoramic radiography, CT, and CBCT. Panoramic radiography, which is a two-dimensional conventional method, has a limited potency to detect and trace the anterior loop. Studies have shown that panoramic radiography is not sufficient for presurgical implant planning in the mental region and may need to be supplemented with other modalities such as CT for better visualization of the area.^[2,13,14] The CT and CBCT allow three-dimensional imaging without magnification and distortion. Of these, CBCT has the advantage of providing high-quality images with less radiation dose than CT.^[4,7,10]

In this study, on CBCT images of Iranian population, anterior loop was present in 32.8% of image samples. The presence of anterior loop shows a high diversity in different studies. In a study on 230 spiral CT scans in Belgium, the anterior loop of mandibular canal was visualized in 7% of the cases.^[7] A total of 34.4% of panoramic images had anterior loop in Ngeow *et al.*'s study carried out in Malaysia.^[2] From several

Table 1: The frequencies of the presence of anterior loop and the mean length of anterior loop in both genders in the right and left sides

Variables	Presence of the anterior loop percentage of total	Anterior loop length (mm)
Right side		
Male	16.1	2.89 (SD=1.62)
Female	16.7	2.50 (SD=1.49)
Left side		
Male	16.7	2.43 (SD=1.31)
Female	16.1	2.28 (SD=1.00)

SD: Standard deviation

studies shown in Table 2, it can be concluded that the prevalence of anterior loop is varying from 0% to 88% among different populations. These wide ranges of the incidence may be related to interindividual anatomical variability associated with race. It has been found that the incidence of visualization of anterior loop in the studies on cadavers and three-dimensional images is higher than that of panoramic radiographs. However, they are similar in direct visualization on cadaver and CT or CBCT.^[1,5]

In the present CBCT study, the incidence and length of anterior loop did not change with age increase, while in the study on panoramic radiographs, the incidence of anterior loop was reduced with aging because of the difficulty in visualizing the anterior loop in older patients.^[2] There was no correlation between the incidence and length of anterior loop and gender and side in this study, which was in accordance with the results of previous studies.^[2,9] Some studies showed a relationship between the length of anterior loop and age, side and race. However, they concluded that the influence of race was more than other factors.^[6,8,20,21,23]

The length of anterior loop has been reported to vary in different populations. The reported mean lengths of anterior loop in different studies are shown in

Table 2. A length range of 0.1 mm to 11 mm has been reported in different studies. These differences may be, at least partly, due to the racial influence. A safe distance anterior to the mental foramen is required when performing surgery in the mandibular premolar region. About 6 mm safe distance anterior to the mental foramen is frequently recommended, especially when the anterior loop of the mental nerve cannot be determined definitely or without the use of CBCT or CT.^[4,6,12] There are also other suggestions from 1 to 4 mm for the safe distance anterior to the mental foramen.^[1] These diverse recommendations for the safe distance reflect the length variations of anterior loop in each patient; therefore, a fixed distance anterior to the mental foramen is not safe, and the anterior loop length should be determined for each individual to avoid injury to the mental nerve.

CONCLUSION

Great care is required when placing implants in proximity to mental foramen to avoid anterior loop injury. Because of the length variations of anterior loop in each patient, a fixed distance anterior to the mental foramen is not safe, and the length of anterior loop should be determined for each individual. The

Table 2: The incidence, mean length and range of anterior loop in different studies in computed tomography, cone beam computed tomography and cadaver

Authors	Ethic/Country	Technique	Incidence (%)	Mean length (mm)	Range (mm)	Sample size n (number)
Li <i>et al.</i> ^[6]	Chinese	Spiral CT	83.1	2.09	0-5.31	68
Kaya <i>et al.</i> ^[15]	Turkey	Spiral CT	34	3.00±1.41	-	73
Sahman and Sisman ^[26]	Turkey	CBCT	28.5	Right=2.19±1 Left=2.08±0.89	-	494
Koivisto <i>et al.</i> ^[27]	USA	CBCT	10.4	-	-	106
Lu <i>et al.</i> ^[9]	USA (California)	CBCT	85.2	1.46±1.25	2.87-6.67	366 (732 hemimandibles)
Vujanovic-Eskenazi <i>et al.</i> ^[3]	Spanish	CBCT	48.8	1.59±0.93	0.4-4	82
Apostolakis and Brown ^[6]	Greece	CBCT	48	0.89	0-5.7	93
Filo <i>et al.</i> ^[18]	Switzerland	CBCT	69.73	1.16	0.3-5.6	694
Rosa <i>et al.</i> ^[19]	Brazil	CBCT	-	2.40±0.93	-	352
Chen <i>et al.</i> ^[23]	USA	CBCT	-	6.22±1.68	-	100
Chen <i>et al.</i> ^[23]	Taiwan	CBCT	-	7.61±1.81	-	100
Uchida <i>et al.</i> ^[20]	Japanese	CBCT	71	2.2±0.8	-	71 (140 hemimandibles)
Uchida <i>et al.</i> ^[21]	Japanese	Cadaver	62.7	1.5±1.4	0.0-6	38 (75 hemimandibles)
Yu <i>et al.</i> ^[5]	Korean	Cadaver	-	3.05±1.15	1.17-5.18	19 (26 hemimandibles)
Hwang <i>et al.</i> ^[24]	Korean	Cadaver	-	5±1.8	-	30 hemimandibles
Kuzmanovic <i>et al.</i> ^[16]	New Zealand (Caucasian)	Cadaver	37	1.20±0.9	0.11-3.31	22 (44 hemimandibles)
Neiva <i>et al.</i> ^[17]	Caucasian	Cadaver	88	4.13±2.04	1-11	22
Solar <i>et al.</i> ^[12]	Austria	Cadaver	60	1±1.2	0.5-5	37
Mardinger <i>et al.</i> ^[22]	Israel	Cadaver	28	1.05±0.47	0.4-2.19	46 hemimandibles
Bavitz <i>et al.</i> ^[25]	USA	Cadaver	11	0.2±0.3	0-1	47
Rosenquist ^[11]	Sweden	Cadaver	26	0.15	0-1	58

CT: Computed tomography; CBCT: Cone beam computed tomography

use of CBCT provides accurate measurements of the length of anterior loop.

Financial support and sponsorship

Nil.

Conflicts of interest

The authors of this manuscript declare that they have no conflicts of interest, real or perceived, financial or non-financial in this article.

REFERENCES

- Greenstein G, Tarnow D. The mental foramen and nerve: Clinical and anatomical factors related to dental implant placement: A literature review. *J Periodontol* 2006;77:1933-43.
- Ngeow WC, Dionysius DD, Ishak H, Nambiar P. A radiographic study on the visualization of the anterior loop in dentate subjects of different age groups. *J Oral Sci* 2009;51:231-7.
- Vujanovic-Eskenazi A, Valero-James JM, Sánchez-Garcés MA, Gay-Escoda C. A retrospective radiographic evaluation of the anterior loop of the mental nerve: Comparison between panoramic radiography and cone beam computerized tomography. *Med Oral Patol Oral Cir Bucal* 2015;20:e239-45.
- Gümüşok M, Kayadüğün A, Üçok Ö. Anterior loop of the mental nerve and its radiologic imaging: A review. *Marmara Dent J* 2013;2:81-3.
- Yu SK, Kim S, Kang SG, Kim JH, Lim KO, Hwang SI, *et al.* Morphological assessment of the anterior loop of the mandibular canal in Koreans. *Anat Cell Biol* 2015;48:75-80.
- Apostolakis D, Brown JE. The anterior loop of the inferior alveolar nerve: Prevalence, measurement of its length and a recommendation for interforaminal implant installation based on cone beam CT imaging. *Clin Oral Implants Res* 2012;23:1022-30.
- Jacobs R, Mraiwa N, vanSteenberghe D, Gijbels F, Quirynen M. Appearance, location, course, and morphology of the mandibular incisive canal: An assessment on spiral CT scan. *Dentomaxillofac Radiol* 2002;31:322-7.
- Li X, Jin ZK, Zhao H, Yang K, Duan JM, Wang WJ. The prevalence, length and position of the anterior loop of the inferior alveolar nerve in Chinese, assessed by spiral computed tomography. *Surg Radiol Anat* 2013;35:823-30.
- Lu CI, Won J, Al-Ardah A, Santana R, Rice D, Lozada J. Assessment of the anterior loop of the mental nerve using cone beam computerized tomography scan. *J Oral Implantol* 2015;41:632-9.
- Scarfe WC, Farman AG, Sukovic P. Clinical applications of cone-beam computed tomography in dental practice. *J Can Dent Assoc* 2006;72:75-80.
- Rosenquist B. Is there an anterior loop of the inferior alveolar nerve? *Int J Periodontics Restorative Dent* 1996;16:40-5.
- Solar P, Ulm CH, Frey G, Matejka M. A classification of the intra osseous paths of the mental nerve. *Int J Oral Maxillofac Implants* 1994;9:339-44.
- Arzouman MJ, Otis L, Kipnis V, Levine D. Observations of the anterior loop of the inferior alveolar canal. *Int J Oral Maxillofac Implants* 1993;8:295-300.
- do Couto-Filho CE, de Moraes PH, Alonso MB, Haiter-Neto F, Olate S, de Albergaria-Barbosa JR. Accuracy in the diagnosis of the mental nerve loop. A comparative study between panoramic radiography and cone beam computed tomography. *Int J Morphol* 2015;33:327-32.
- Kaya Y, Sencimen M, Sahin S, Okcu KM, Dogan N, Bahcecitapar M. Retrospective radiographic evaluation of the anterior loop of the mental nerve: Comparison between panoramic radiography and spiral computerized tomography. *Int J Oral Maxillofac Implants* 2008;23:919-25.
- Kuzmanovic DV, Payne AG, Kieser JA, Dias GJ. Anterior loop of the mental nerve: A morphological and radiographic study. *Clin Oral Implants Res* 2003;14:464-71.
- Neiva RF, Gapski R, Wang HL. Morphometric analysis of implant-related anatomy in Caucasian skulls. *J Periodontol* 2004;75:1061-7.
- Filo K, Schneider T, Locher MC, Kruse AL, Lübbers HT. The inferior alveolar nerve's loop at the mental foramen and its implications for surgery. *J Am Dent Assoc* 2014;145:260-9.
- Rosa MB, Sotto-Maior BS, Machado Vde C, Francischone CE. Retrospective study of the anterior loop of the inferior alveolar nerve and the incisive canal using cone beam computed tomography. *Int J Oral Maxillofac Implants* 2013;28:388-92.
- Uchida Y, Noguchi N, Goto M, Yamashita Y, Hanihara T, Takamori H, *et al.* Measurement of anterior loop length for the mandibular canal and diameter of the mandibular incisive canal to avoid nerve damage when installing endosseous implants in the interforaminal region: A second attempt introducing cone beam computed tomography. *J Oral Maxillofac Surg* 2009;67:744-50.
- Uchida Y, Yamashita Y, Goto M, Hanihara T. Measurement of anterior loop length for the mandibular canal and diameter of the mandibular incisive canal to avoid nerve damage when installing endosseous implants in the interforaminal region. *J Oral Maxillofac Surg* 2007;65:1772-9.
- Mardinger O, Chaushu G, Arensburg B, Taicher S, Kaffe I. Anterior loop of the mental canal: An anatomical-radiologic study. *Implant Dent* 2000;9:120-5.
- Chen JC, Lin LM, Geist JR, Chen JY, Chen CH, Chen YK. A retrospective comparison of the location and diameter of the inferior alveolar canal at the mental foramen and length of the anterior loop between American and Taiwanese cohorts using CBCT. *Surg Radiol Anat* 2013;35:11-8.
- Hwang K, Lee WJ, Song YB, Chung IH. Vulnerability of the inferior alveolar nerve and mental nerve during genioplasty: An anatomic study. *J Craniofac Surg* 2005;16:10-4.
- Bavitz JB, Harn SD, Hansen CA, Lang M. An anatomical study of mental neurovascular bundle-implant relationships. *Int J Oral Maxillofac Implants* 1993;8:563-7.
- Sahman H, Sisman Y. Anterior Loop of the Inferior Alveolar Canal: A Cone-Beam Computerized Tomography Study of 494 Cases. *J Oral Implantol* 2016;42:333-6.
- Koivisto T, Chiona D, Milroy LL, McClanahan SB, Ahmad M, Bowles WR. Mandibular canal location: Cone-beam computed tomography examination. *J Endod* 2016;42:1018-21.