

Original Article

Comparison of apical transportation and centering ability of Mtwo and Reciproc R25 in severely curved canals using cone-beam computed tomography

Abbas Mesgarani¹, Mahmoud Reza Hamidi², Sina Haghanifar³, Shabnam Naiemi⁴, Ali Bijani⁵

¹Department of Endodontics, Dental Faculty, Mazandaran University of Medical Science, Sari, ²Department of Endodontics, Faculty of Dentistry, Babol University of Medical Sciences, ³Department of Oral and Maxillofacial Radiology, Faculty of Dentistry, Babol University of Medical Sciences, ⁴Department of Endodontics, Faculty of Dental, Golestan University of Medical Sciences, Gorgan, ⁵MD, Social Determinants of Health Research Center, Health Research Institute, Babol University of Medical Sciences, Babol, Iran

ABSTRACT

Background: Apical transportation (AT) of the root canal moves the physiologic canal terminus to a new location on the external root surface and results in the accumulation of debris and residual microorganisms due to inadequate cleaning and shaping of the canal end. This study aimed to assess the prevalence of AT following canal preparation with Mtwo and Reciproc R25 using cone-beam computed tomographic (CBCT).

Materials and Methods: In this *in vitro* study, 40 mesiobuccal root canals of the maxillary molars with 19–22 mm length and ($>40^\circ$) taper were prepared in two groups using Mtwo and Reciproc R25 rotary systems along with irrigation with 2.5% NaOCl. CBCT scans were obtained of the canals before and after preparation under similar conditions, and the values were measured using the device software. The amount of AT was measured according to Gambill *et al.* Data were analyzed using SPSS 17 and Chi-square and *t*-tests. $P < 0.05$ was considered significant.

Results: Both systems caused some degrees of AT. No significant difference was found between the two systems in terms of the amount and direction of AT ($P > 0.05$); overall, the frequency of AT toward the mesial wall was greater than that toward the distal direction. However, this difference was not statistically significant.

Conclusion: The mean amount of AT and the ability to keep the instruments in severely curved canals were not significantly different in canals prepared by Mtwo and Reciproc rotary systems. Thus, these systems can be used in the clinical setting with the lowest risk of AT.

Key Words: Apical, transportation, cone-beam computed tomography, rotary

Received: March 2017
Accepted: September 2017

Address for correspondence:

Dr. Shabnam Naiemi,
Department of Endodontics,
Faculty of Dental,
Golestan University of
Medical Sciences, Gorgan,
Iran.
E-mail: naeimi.shabnam@
gmail.com

INTRODUCTION

Mechanical preparation of the root canal system (RCS) is among the most important steps of endodontic treatment for cleaning the canal walls and

creates a conical form to facilitate access, effective irrigation, and three-dimensional obturation of the RCS.^[1] Irrespective of the technique of cleaning

This is an open access article distributed under the terms of the Creative Commons Attribution-NonCommercial-ShareAlike 3.0 License, which allows others to remix, tweak, and build upon the work non-commercially, as long as the author is credited and the new creations are licensed under the identical terms.

For reprints contact: reprints@medknow.com

How to cite this article: Mesgarani A, Hamidi MR, Haghanifar S, Naiemi S, Bijani A. Comparison of apical transportation and centering ability of Mtwo and Reciproc R25 in severely curved canals using cone-beam computed tomography. *Dent Res J* 2018;15:57-62.

Access this article online



Website: www.drj.ir
www.drjjournal.net
www.ncbi.nlm.nih.gov/pmc/journals/1480

and shaping, this process results in the reduction of radicular dentin. Over-reduction of radicular dentin in one point compared to other points at the same distance relative to the longitudinal axis of the tooth is a procedural error called canal transportation.^[2] Apical transportation (AT) moves the physiologic canal terminus to a new location on the external root surface and results in the accumulation of debris and residual microorganisms due to inadequate cleaning and shaping of the canal end.^[3,4] Continuation of instrumentation of the root canal in the wrong path by larger files creates a teardrop shape at the apical region and results in AT and zipping of the root canal.^[5] Such canal preparation does not create a resistant form for gutta-percha compaction and results in poor condensation and overextension of gutta-percha.^[3] Advances have been made in root canal preparation techniques to overcome problems such as transportation. The main goal of endodontic treatment is to eliminate pulpal tissue, bacteria, and their products from the RCS and proper shaping of the root canal for obturation.^[1] This goal can be achieved using hand files or NiTi rotary files.

Engine driven is used to save time and prevent fatigue of dentists and patients.^[6] Rotary instruments have greater flexibility and cutting ability compared to hand instruments (SS),^[7,8] and due to their super-elastic property, they preserve the actual tapered shape of the canal during preparation and eventually decrease the risk of canal transportation.^[9-12] However, high price and risk of file separation and fracture are among the shortcomings of these systems that may result in failure of canal preparation.^[13,14] Considering these shortcomings, manufacturers have modified these systems to improve their properties and have introduced new systems to the market.

Mtwo is a new generation of rotary files. In contrast to other rotary systems, small size Mtwo files (10/04 and 25/06) reach to the working length and are used at the beginning of root canal preparation to access the apical third. Standard Mtwo rotary system includes four files with 10–25 tip sizes and 4%–6% taper. The number of grooves on the file indicates its taper. The length of these files can be 21, 25, and 31 mm. Helical angle or flute is the angle between the cutting blade of the file and dentinal wall along the file length. This angle is variable in Mtwo files and is a specific property for each file. It increases the cutting efficiency of Mtwo files with larger size and increases the mechanical strength of smaller Mtwo

files. Evidence shows that this file does not change the root anatomy. Its risk of fracture in curved canals is low and better cleans the root canal from debris compared to other rotary systems.^[15,16]

Recently, a new technique with reciprocating motion, the Reciproc system was introduced to increase the clinical service of NiTi files and their cyclic fatigue resistance compared to files with continuous motion because it is claimed that reciprocating motion decreases torsional stress created by reverse cyclic rotation of file. This system has three sizes for use based on primary canal diameter. The instrument has a variable taper along its length. At the apical 3 mm, R25, R40, and R50 have a taper of 0.08, 0.06, and 0.05, respectively. Reciproc is compatible with endomotor and performs reciprocating motion at a frequency of 10 rpm. Every three reciprocating rotations allow for 360° rotation. The cutting angle of this instrument is larger than the releasing angle, and thus, it allows for forward movement into the canal.^[17,18] Several techniques are available to assess the centering ability of instruments (maintaining the original path of the canal and preventing transportation). Sectioning of the root at different distances from the apex is conventionally used to directly observe the canal shape. However, this method cannot reveal the original canal pathway before preparation.^[19] Previously, scanning electron microscopy, radiography, photography, and computed analyses have been used to assess the efficacy and accuracy of canal preparation. However, some of these techniques are invasive, and comparison of the canal before and after instrumentation is difficult. Some other techniques have the major drawback of traumatizing the specimen. Thus, data obtained through these techniques may be misleading. Recently, some techniques have been introduced for the assessment of the teeth without traumatizing them and have been used for the comparison of canal shape pre- and post-instrumentation. Computed tomography enables three-dimensional (3D) image reconstruction of sections made of the root canal.^[20,21] Cone-beam computed tomography (CBCT) is a new imaging modality that uses a 2D sensor and cone-shaped beam instead of fan-shaped X-ray beam in conventional CT. In this technique, volumetric data of the respective areas are acquired by rotation of the beam and sensor.^[22] This technology has been used for the assessment of root canal morphology, fractures, and changes in the canal structure following preparation.^[23-26] Considering the risk of canal transportation during instrumentation,

this study aimed to assess the prevalence of AT following canal preparation with Mtwo and Reciproc R25 using CBCT.

MATERIALS AND METHODS

Forty extracted maxillary first molars were collected from the clinics of Babol city and stored in saline solution at 4°C until the experiment. Teeth with almost similar mesiobuccal (MB) root lengths (19–22 mm) and curvature of >40° were selected according to Zhang *et al.*^[27] All teeth had mature apices. MB2 canals were not included in this study. Access cavity was prepared and MB canal was localized. A #10 K-file was introduced into the canal until its tip was visible at the apex. Actual canal length was measured as such, and the working length was considered 1 mm short of the canal length (corresponding to the position of apical constriction). Specimens were mounted in gypsum blocks to simplify the work and achieve a reproducible position for taking CBCT images. Before canal preparation, CBCT images were obtained using Cranex 3D dental imaging system (Soredex, Helsinki, Finland) with a FOV of 6 × 8 and voxel size of 0.1 mm × 0.1 mm from the sections made at 1, 2, 3, 6, and 9 mm distances from the apex (indicative of 1/3 coronal, 1/3 middle, and 1/3 apical) perpendicular to the longitudinal axis of the root. The obtained images were saved in a computer for later comparison with the postpreparation images. The teeth were divided into two groups of 20 each according to the average of the canal curvature. Straight-line access was obtained and a #10 file was used for patency. RC-Prep (VDW, Sweden) and 2 ml of 2.5% NaOCl were used for canal preparation in both groups.

Group 1: Root canals were instrumented using Mtwo system (VDW, Munich, Germany) and handpiece Endo-mate-DT (Nsk-JAPAN) with speed 300 rpm and torque 2 Nm with single length technique and according to the manufacturer's instructions. Instrumentation in apical area up to file No. 25, with taper 0/06, was done. Sequence using the file was in this way (10/04, 15/05, 20/05, 25/06).

Group 2: Root canals were instrumented using Reciproc R25 system (VDW, Munich, Germany) and handpiece electric motor with contra angle 20:1, according to the manufacturer's instructions.

In each group, instrumentation was performed by one operator who prepared 5 canals during a specific period daily to apply equal force during preparation

and prevent the effect of fatigue on the results. Postinstrumentation CBCT images were then obtained under the same conditions and exported to on-demand software. To assess the amount of canal transportation, the technique described by Yin *et al.*^[28] was applied as follows:

- Y1: The least distance from the external root surface to the mesial circumference of the unprepared canal in cross sections
- X1: The least distance from the external root surface to the distal circumference of the unprepared canal in cross sections
- Y2: The least distance from the external root surface to the mesial circumference of the prepared canal in cross sections
- X2: The least distance from the external root surface to the distal circumference of the prepared canal in cross sections.

To calculate the amount of canal transportation, the following formula was used:

$$(Y1 - Y2) - (X1 - X2)$$

The obtained data were placed in the formula. If the resulting number of this formula was <0.1, indicated no transportation, while any other value indicated canal transportation. Negative values indicated canal transportation toward distal while positive values indicated canal transportation toward the mesial. To assess the centering ability using the obtained values, the following formula was used:

$$\frac{Y_1 - Y_2}{X_1 - X_2} \text{ or } \frac{X_1 - X_2}{Y_1 - Y_2}$$

The resulting value of one indicated no change in the canal path and that the file remained centered in the canal. The closer the obtained value to zero, the lower the centering ability of the instrument.

Statistical analysis:

The data were analyzed using statistical software SPSS17 (Chicago: SPSS Inc) and *t*-test and Chi-square tests; $P \leq 0.05$ was considered significant.

RESULTS

In this study, the canal displacement was examined at 1, 2, and 3 mm diameters and the ability to maintain the canal centrality was examined at 1, 2, 3, 6, and 9 mm distance from apical canals with the curvature extreme (<40°) using Mtwo and Reciproc rotary systems. The mean displacement for the mentioned diameters is listed in Table 1 and Figure 1. Based

on the statistical results, there was no significant difference between the two systems in terms of the amount and direction of displacement.

The frequency of direction of displacement is shown in Table 2. In general, the displacement to the mesial area in both systems was higher than the displacement to the distal area although it was not a statistically significant difference.

The mean ability to maintain the canal centrality is mentioned in ratio and showed at 1, 2, 3, 6, and 9 mm distance from the apical canal in Table 3. Based on the results of the statistical tests, there was no significant difference in terms of maintaining the canal centrality between the two MTwo and Reciproc rotary systems.

DISCUSSION

This study aimed to compare the centering ability of Mtwo and Reciproc, the new single file system, and the amount of canal transportation in severely curved canals prepared with these systems. The selection of severely curved canals according to Schneider *et al.* was because the iatrogenic errors such as the canal transportation more commonly occur in severely

curved canals. The master apical file in both systems was #25 because this size is safe for use in curved canals. In this study, MB canals of the maxillary molars were used because these canals usually have severe curves. Furthermore, these canals are very thin but flat at the same time. These characteristics further complicate preparation of these canals. Our study results showed that both systems caused some degrees of AT at 1, 2, 3, 6, and 9 mm distances from the apex during preparation. However, no significant difference was noted in this respect between the two systems. Moreover, in all sections and in both systems, the amount of AT was <0.1 mm. The amount of canal transportation in a report by Peters was 0.1 mm and thus within the clinically acceptable range.^[29]

Therefore, both systems were capable of keeping the file centered in the canal and met the required criteria for use in the clinical setting. Occurrence of AT depends on several factors such as the instrument design, physical properties of the alloy, and the preparation technique.^[30] Iqbal *et al.* reported that small AT with the use of preparation systems depends on the centering ability of the file in the root canal, which *per se* depends on the metal alloy property, design, sharp tip, and conical shape (taper) of the instrument.^[31]

In our study, AT toward the mesial was more frequent than toward the distal in both systems although this difference was not statistically significant. This finding was similar to the results of Junaid *et al.*^[32] They compared AT in curved canals prepared with WaveOne file in a reciprocating motion and a sequence of Twisted Files in a continuous rotating motion and found no significant difference between the two systems. However, the magnitude of transportation in the mesial direction was greater than distal transportation in both systems, which is in accord with the definition of AT (removal of canal wall structure on the outside curve in the apical half of the canal as the result of the innate tendency of the files to return to their original straight shape during canal preparation). Our results were also in accord with those of Stern and Schafer. Stern *et al.*^[33] evaluated the centering ability and shaping changes in three types of instrumentation techniques with NiTi files including ProTaper, Twisted File (rotary motion), and F2 ProTaper with reciprocating motion. They found no significant difference in the three groups in terms of the amount of transportation, centering ability, and duration of instrumentation between

Table 1: The mean amount of canal transportation (mm)

Distance from apex	Mean±SD		P
	Rotary (n=20)	Reciproc (n=20)	
1	-0.09±0.17	-0.01±0.15	0.131
2	0.04±0.19	-0.05±0.19	0.87
3	0.05±0.17	0.05±0.11	0.96

SD: Standard deviation

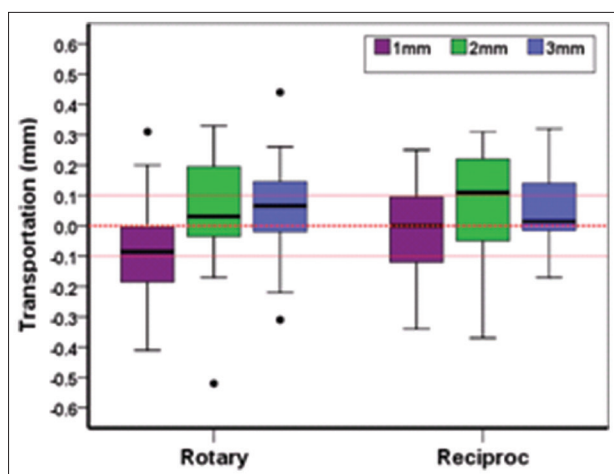


Figure 1: Distribution of the amount of displacement in the two systems at different diameters.

Table 2: The frequency of direction of displacement

Distance from the apex (mm)	System	Transportation toward distal (%)	No transportation (%)	Transportation toward mesial (%)	P
1	Rotary (n=20)	10 (5)	8 (40)	2 (10)	0.786
	Reciproc (n=20)	8 (40)	9 (45)	3 (15)	
2	Rotary (n=20)	3 (15)	11 (55)	6 (30)	0.145
	Reciproc (n=20)	4 (20)	5 (25)	11 (55)	
3	Rotary (n=20)	3 (15)	10 (50)	7 (35)	0.480
	Reciproc (n=20)	1 (5)	13 (65)	6 (30)	

Table 3: The mean centering ratio

Distance from apex (mm)	Mean±SD		P
	Rotary (n=20)	Reciproc (n=20)	
1	0.43±0.26	0.46±0.30	0.822
2	0.49±0.27	0.33±0.24	0.076
3	0.42±0.30	0.60±0.31	0.079
6	0.53±0.27	0.4018±0.28	0.162
9	0.42±0.24	0.51±0.29	0.268

SD: Standard deviation

the rotary and reciprocating motions. Schäfer and Schlingemann^[34] evaluated the shaping ability of reciprocating single file with Mtwo and ProTaper rotary instruments for preparation of severely curved canals of extracted teeth. They showed that using Mtwo and Reciproc resulted in better cleaning of the apical region compared to ProTaper and WaveOne. Using the reciprocating motion in the Reciproc system, straightening of the canal curve will be minimal, which is in accord with the results of previous studies. This is due to the intermittent rotating motion and high superelasticity of the files, which is in accord with our findings. Madani *et al.*^[35] found no significant difference in AT in different cross sections of the mesial and distal surfaces of the canal on CBCT images following preparation with Mtwo and ProTaper systems; this finding is somehow in line with our findings. In our study, no difference was found between the centering ability of Mtwo and Reciproc systems.

CT scanners due to their practicality and noninvasive nature are routinely used for the assessment of endodontic systems. In this technique, root canal morphology before preparation can be assessed without probing with small hand files; this issue can prevent changing the primary canal anatomy.^[2] This technique, in comparison with the conventional methods, has higher accuracy and does not traumatize the specimen. The results are highly reproducible, numerous images can be obtained from the canals, and comprehensive information can be achieved

about the anatomy of the RCS before, during, and after mechanical preparation.

The present study had several limitations and advantages. The strength points of our study were canal preparation by one operator (high reproducibility of results), using software calculations (high accuracy), and use of CBCT. The *in vitro* design was among the drawbacks of the study limiting the generalizability of the results to the clinical setting.

CONCLUSION

Within the limitations of this study, no difference was noted in AT and centering ability of the two systems. Thus, both systems can be used with minimal risk of procedural errors for root canal preparation. We suggest that to increase the accuracy, study conditions must be matched for all teeth. Specimens must be randomly assigned to the groups, and the curve of the roots must be considered and matched for random allocation of the canals to study groups.

Acknowledgments

The authors would like to thank the administrative and secretarial staff of the Department of Endodontics of Dental Faculty, Babol University of Medical Sciences, for their contribution to the maintenance of our patient record without which this project would have been impossible.

Financial support and sponsorship

The medical university of Babol, provided part of financial support in this research.

Conflicts of interest

The authors of this manuscript declare that they have no conflicts of interest, real or perceived, financial or nonfinancial in this article.

REFERENCES

1. Karabucak B, Gatan AJ, Hsiao C, Iqbal MK. A comparison of apical transportation and length control between EndoSequence

- and Guidance rotary instruments. *J Endod* 2010;36:123-5.
2. Hartmann MS, Barletta FB, Camargo Fontanella VR, Vanni JR. Canal transportation after root canal instrumentation: A comparative study with computed tomography. *J Endod* 2007;33:962-5.
 3. Baumgarther IB. *Ingle's Endodontics*. 3rd ed., Vol. 2, Ch. 31. Hamilton: BC Decker; 2008. p. 1123.
 4. Schafer E, Dammascke T. Development and sequelae of canal transportation. *Endod Topics* 2009;15:75-90.
 5. Torabinejad M, Walton R. *Endodontics Principles and Practice*. 3rd ed., Ch. 15. St. Louis: Saunders; 2009. p. 266.
 6. Taşdemir T, Aydemir H, Inan U, Unal O. Canal preparation with Hero 642 rotary Ni-Ti instruments compared with stainless steel hand K-file assessed using computed tomography. *Int Endod J* 2005;38:402-8.
 7. Walia HM, Brantley WA, Gerstein H. An initial investigation of the bending and torsional properties of Nitinol root canal files. *J Endod* 1988;14:346-51.
 8. Kazemi RB, Stenman E, Spångberg LS. Machining efficiency and wear resistance of nickel-titanium endodontic files. *Oral Surg Oral Med Oral Pathol Oral Radiol Endod* 1996;81:596-602.
 9. Kuhn WG, Carnes DL Jr., Clement DJ, Walker WA 3rd. Effect of tip design of nickel-titanium and stainless steel files on root canal preparation. *J Endod* 1997;23:735-8.
 10. Reddy SA, Hicks ML. Apical extrusion of debris using two hand and two rotary instrumentation techniques. *J Endod* 1998;24:180-3.
 11. Ferraz CC, Gomes NV, Gomes BP, Zaia AA, Teixeira FB, Souza-Filho FJ, *et al.* Apical extrusion of debris and irrigants using two hand and three engine-driven instrumentation techniques. *Int Endod J* 2001;34:354-8.
 12. Pettiette MT, Delano EO, Trope M. Evaluation of success rate of endodontic treatment performed by students with stainless-steel K-files and nickel-titanium hand files. *J Endod* 2001;27:124-7.
 13. Alapati SB, Brantley WA, Svec TA, Powers JM, Mitchell JC. Scanning electron microscope observations of new and used nickel-titanium rotary files. *J Endod* 2003;29:667-9.
 14. Berutti E, Negro AR, Lendini M, Pasqualini D. Influence of manual preflaring and torque on the failure rate of ProTaper rotary instruments. *J Endod* 2004;30:228-30.
 15. Honardar K. A comparison of MTWO rotary file with Kfile one negotiation of second mesiobuccal canal in maxillary first molar. *IEJ* 2008;3:29-32.
 16. Foschi F, Nucci C, Montebugnoli L, Marchionni S, Breschi L, Malagnino VA, *et al.* SEM evaluation of canal wall dentine following use of Mtwo and ProTaper NiTi rotary instruments. *Int Endod J* 2004;37:832-9.
 17. Alves FR, Rôças IN, Almeida BM, Neves MA, Zoffoli J, Siqueira JF Jr., *et al.* Quantitative molecular and culture analyses of bacterial elimination in oval-shaped root canals by a single-file instrumentation technique. *Int Endod J* 2012;45:871-7.
 18. Gavini G, Caldeira CL, Akisue E, Candeiro GT, Kawakami DA. Resistance to flexural fatigue of reciproc R25 files under continuous rotation and reciprocating movement. *J Endod* 2012;38:684-7.
 19. Javaheri HH, Javaheri GH. A comparison of three Ni-Ti rotary instruments in apical transportation. *J Endod* 2007;33:284-6.
 20. Nagaraja SH. CT evaluation of canal preparation using rotary and hand Ni-Ti instruments: An *in vitro* study. *J Conserv Dent* 2010;13:16-22.
 21. Nazari SH, Mirmotalebi F. Application of CT scan in evaluation of transportation of root canal during endodontic retreatment. *Asian J Exp Sci* 2007;21:227-32.
 22. Bianchi SD, Lojaco A. 2D and 3D Images Generated by Cone Beam Computed Tomography (CBCT) for Dentomaxillofacial Investigations. Proceedings of the 12th International Symposium and Exhibition: Computer Assisted Radiology and Surgery, 1998, Amsterdam: Elsevier; p. 792-7.
 23. Bernardes RA, Rocha EA, Duarte MA, Vivan RR, de Moraes IG, Bramante AS, *et al.* Root canal area increase promoted by the EndoSequence and ProTaper systems: Comparison by computed tomography. *J Endod* 2010;36:1179-82.
 24. Gergi R, Rjeily JA, Sader J, Naaman A. Comparison of canal transportation and centering ability of twisted files, pathfile-ProTaper system, and stainless steel hand K-files by using computed tomography. *J Endod* 2010;36:904-7.
 25. Estrela C, Bueno MR, Sousa-Neto MD, Pécora JD. Method for determination of root curvature radius using cone-beam computed tomography images. *Braz Dent J* 2008;19:114-8.
 26. Wenzel A, Haiter-Neto F, Frydenberg M, Kirkevang LL. Variable-resolution cone-beam computerized tomography with enhancement filtration compared with intraoral photostimulable phosphor radiography in detection of transverse root fractures in an *in vitro* model. *Oral Surg Oral Med Oral Pathol Oral Radiol Endod* 2009;108:939-45.
 27. Zhang R, Hu T. Letters to editor: Root canal curvature. *Int Endod J* 2010;43:616-8.
 28. Yin X, Cheung GS, Zhang C, Masuda YM, Kimura Y, Matsumoto K, *et al.* Micro-computed tomographic comparison of nickel-Titanium rotary versus traditional instruments in C-shaped root canal system. *J Endod* 2010;36:708-12.
 29. Peters OA. Current challenges and concepts in the preparation of root canal systems: A review. *J Endod* 2004;30:559-67.
 30. Peters OA, Schönenberger K, Laib A. Effects of four Ni-Ti preparation techniques on root canal geometry assessed by micro computed tomography. *Int Endod J* 2001;34:221-30.
 31. Iqbal MK, Firic S, Tulcan J, Karabucak B, Kim S. Comparison of apical transportation between ProFile and ProTaper niTi rotary instruments. *Int Endod J* 2004;37:359-64.
 32. Junaid A, Freire LG, da Silveira Bueno CE, Mello I, Cunha RS. Influence of single-file endodontics on apical transportation in curved root canals: An *ex vivo* micro-computed tomographic study. *J Endod* 2014;40:717-20.
 33. Stern S, Patel S, Foschi F, Sherriff M, Mannocci F. Changes in centring and shaping ability using three Nickel-Titanium instrumentation techniques analysed by micro-computed tomography (μ CT). *Int Endod J* 2012;45:514-23.
 34. Schäfer E, Schlingemann R. Efficiency of rotary nickel-titanium K3 instruments compared with stainless steel hand K-Flexofile. Part 2. Cleaning effectiveness and shaping ability in severely curved root canals of extracted teeth. *Int Endod J* 2003;36:208-17.
 35. Madani ZS, Haddadi A, Haghanifar S, Bijani A. Cone-beam computed tomography for evaluation of apical transportation in root canals prepared by two rotary systems. *Iran Endod J* 2014;9:109-12.