

## Case Report

### A sectional complete denture for microstomic patients

Seyyed Hamid Shams<sup>1</sup>, Seyyed Saeed Shams<sup>2</sup>, Ehsan Ghasemi<sup>3</sup>

<sup>1</sup>Prosthodontist, Private Office, Tehran, <sup>2</sup>Student Research Committee, Islamic Azad University Mashhad Branch, Mashhad, <sup>3</sup>Dental Material Research Center and Department of Prosthodontics, School of Dentistry, Isfahan University of Medical Sciences, Isfahan, Iran

Received: January 2019

Accepted: June 2019

Address for correspondence:  
Dr. Ehsan Ghasemi,  
Dental Material Research  
Center and Department of  
Prosthodontics, School of  
Dentistry, Isfahan University  
of Medical Sciences, Isfahan,  
Iran.  
E-mail: ehsann.ghasemi@  
gmail.com

#### ABSTRACT

Microstomic patients may experience a significant limitation in the mandibular opening. The prosthetic rehabilitation of microstomic patients presents difficulties at all stages, from preliminary impressions to prosthetic fabrication. This clinical report described the method of fabrication of sectional denture for patients with microstomia caused by burns. The denture was fabricated in two pieces, and patients inserted and removed the denture easily.

**Key Words:** Dental impression technique, denture, microstomia

#### INTRODUCTION

Microstomia is a term used to describe reduction in the size of oral aperture, which is either acquired or congenital.<sup>[1]</sup> The most common cause of acquired microstomia in healthy children seems to be electrical, thermal, or chemical burns. This condition may be a component of some rare genetic diseases such as Freeman–Sheldon syndrome, otocephaly, and dystrophic epidermolysis bullosa.<sup>[2]</sup> The most well-known rheumatic disease associated with microstomia is systemic sclerosis.<sup>[3]</sup> It has been reported that the limited oral opening may result from the surgical treatment of orofacial cancers, cleft lips, trauma, burns, Plummer–Vinson syndrome, or scleroderma.<sup>[4]</sup>

Microstomic patients may experience a significant limitation in mandibular opening, eccentric mandibular movements, and an overall mandibular immobility.<sup>[5,6]</sup> Several techniques have been proposed for a condition that patients find it difficult to place and remove either standard impression tray or

denture itself in and from the mouth. The prosthetic rehabilitation of microstomic patients presents difficulties at all stages, from preliminary impressions to prosthetic fabrication.<sup>[4]</sup>

McCord *et al.*<sup>[7]</sup> described a maxillary complete denture consisting of two pieces joined by a stainless steel rod with a diameter of 1 mm fitted behind the central incisors. Luebke<sup>[8]</sup> described a sectional impression procedure for edentulous patients using two plastic sectional impression trays assembled with Lego building blocks and autopolymerizing resin.

Making ideal impressions is often considered the initial difficulty in treating these patients. A recommended technique to obtain preliminary impressions for microstomia is modeling a plastic impression compound, the use of stock impression trays with heavy- and light-body silicone impression materials, and flexible impression trays with silicone putty materials. In the present study, we designed a different method for mandibular and maxillary sectional denture fabrication.<sup>[9]</sup>

This is an open access journal, and articles are distributed under the terms of the Creative Commons Attribution-NonCommercial-ShareAlike 4.0 License, which allows others to remix, tweak, and build upon the work non-commercially, as long as appropriate credit is given and the new creations are licensed under the identical terms.

**For reprints contact:** reprints@medknow.com

**How to cite this article:** Shams SH, Shams SS, Ghasemi E. A sectional complete denture for microstomic patients. *Dent Res J* 2020;17:162-6.

#### Access this article online



Website: [www.drj.ir](http://www.drj.ir)  
[www.drjjournal.net](http://www.drjjournal.net)  
[www.ncbi.nlm.nih.gov/pmc/journals/1480](http://www.ncbi.nlm.nih.gov/pmc/journals/1480)

## CASE REPORT

41 years old female with a limited mouth opening was treated in the Prosthodontics Department of Isfahan Dental School (Iran). Her chief complaint was inability to chew food due to missing teeth. Her dental history was extraction of teeth. Microstomia, in this case, seemed to have been caused by burns. Her mouth opening was measured as 25 mm. She was able to insert the mandibular denture by rotating 90°, but had a great difficulty to insert and remove the maxillary denture in spite of short flanges of the denture. Different treatment options were discussed, and the patient agreed with our treatment plan described below.

## METHODS


### Primary impression

Two stock trays were cut anteroposterior in two sections with a disk more than half in opposite regions as shown in Figure 1. We made the preliminary impression and then was poured with dental plaster.

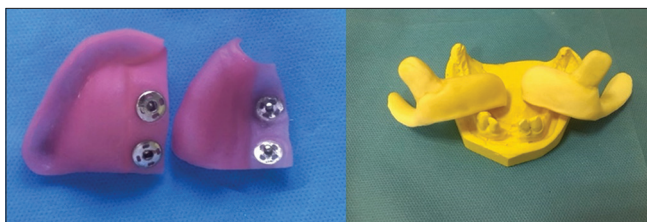
### Final impressions

Photo-polymerizing acrylic resin (Triad, Dentsply International, York, PA, USA) was used for fabrication of sectional custom tray. The tray was fabricated in two sections and had two locking segments in the maxilla (key–key ways) along the midline [Figure 2].

Each section of the tray was molded separately with a low fusing compound, the final maxillary impression was made in zinc oxide eugenol (Luralite, Kerr, Co Italy), and the final mandibular



**Figure 1:** Maxillary and mandibular stock trays.



**Figure 2:** Maxillary and mandibular sectional custom tray.

impression was made by light-body polyvinyl siloxane (Speedex, Coltene, Germany) [Figure 3].

The first section of the tray was inserted, and the excess material out of the border of the tray in the midline was cleaned. Vaseline was used to easily separate the first and second parts of the tray. Then, the other section of the tray was placed over it. After setting the final impression material, the two sections of the tray were taken out separately and connected easily to each other out of the oral cavity [Figure 3].

### Laboratory procedure

Two sections of the maxillary tray were attached, and the master cast was poured using dental stone Type III [Figure 4]. To increase the master cast accuracy in the mandible, the patient's tooth impressions were taken on both sections of the tray separately [Figure 4].

The maxillary master cast was duplicated using agar material, and the wax model was made in two sections.

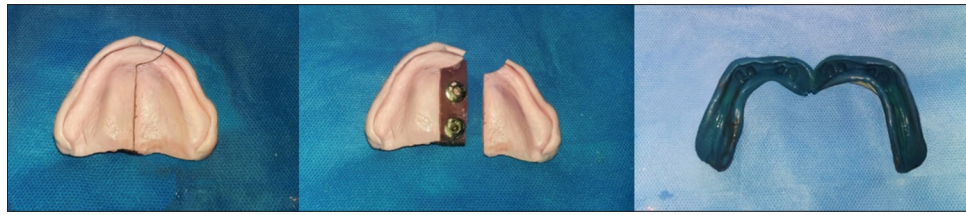
The anterior part extended to the posterior palatal rugae, and the second part extended between the anterior part and posterior palatal seal area [Figure 5]. Perpendicular to the path of insertion, we inserted four microcastable attaching balls on the anterior side of the posterior section of the maxillary framework as shown in Figure 5 (RHEIN83 Co, Roma, Italy) The survey process was done based on the corrected plan we had determined before [Figure 6]. The external and internal finishing lines should be determined carefully on the two sections of the waxy model. The mandibular waxy model was made by the same technique used for the maxilla model except that two microcasting balls were inserted into the left side and a T-bar clasp was designed for the canines. Figure 7 shows the process of substructure design, survey, and final substructure.

### Record block fabrication and jaw relation recording

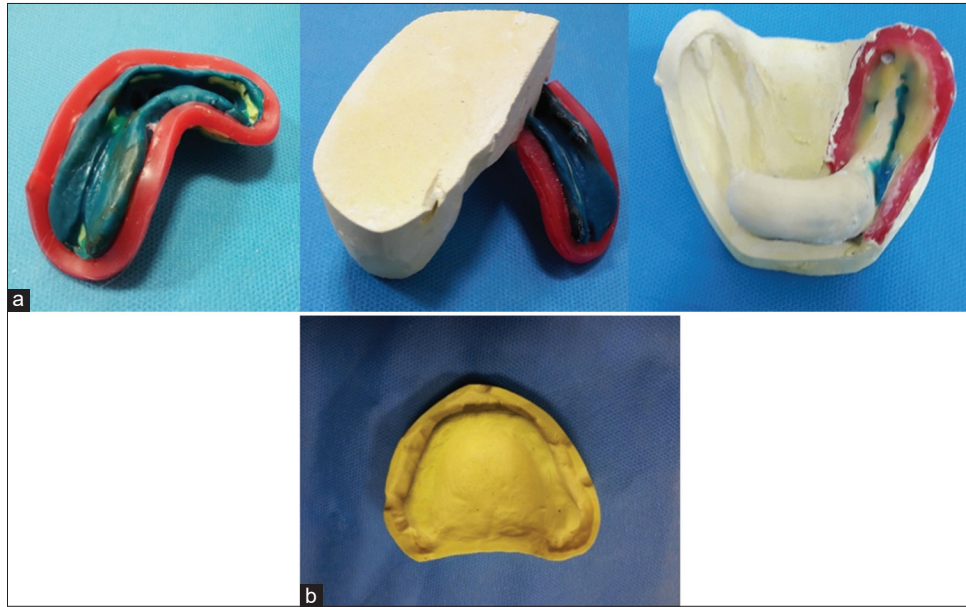
The maxillary and mandibular planes in the oral cavity and vertical dimension of occlusion were adjusted. The centric relation was also recorded. To make a key–key way, we placed a laboratory cap inside the housing attachments. If more retention was needed, we suggested to place clinical caps. After all, we mounted the casts.

### Teeth arrangement and try in

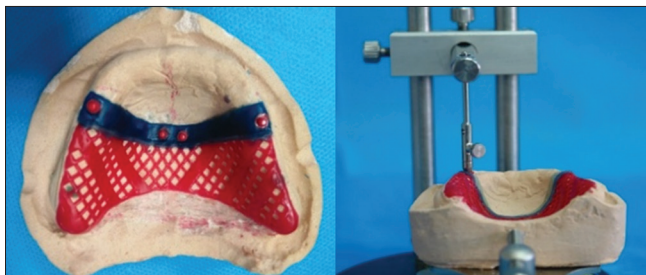
For the next step based on the base and wax recording (we have done before as mentioned), teeth



**Figure 3:** Final impressions.



**Figure 4:** (a) Beading and boxing procedure, pouring mandibular cast. (b) Final maxillary cast.



**Figure 5:** Survey process.

5 and 12 (universal numbering system) were placed on the anterior section during tooth setting and teeth 19, 20, and 21 were set on a separate section. We used anatomical teeth to achieve a balanced occlusion [Figure 8]. We also verified the central relation.

### Processing

During the first step, we placed the posterior section of the denture on the master cast and filled the anterior region using a heavy-body polyvinyl siloxane (Speedex, Coltene, Germany). Then, flasking was done [Figure 9]. The second step was to place the anterior section on the master cast, followed by

the flasking procedure. To prevent the two sections of the denture from bonding, the flasking procedure of the maxilla was done in two steps, and an aluminum foil paper was placed at the junction of the sections [Figure 9]. Mandibular flasking procedure was done in one step. At last, the finishing and polishing procedures were carried out [Figure 10].

### Denture insertion and follow-up

We adjusted the occlusion experimentally and clinically. We inserted the sectional denture in four steps: posterior maxillary part, anterior maxillary part, bigger part of the mandibular section, and finally smaller part of the mandibular denture. For future evaluation, we followed the patient and necessary corrections were done.

### DISCUSSION

The patients with microstomia usually find it difficult to insert and remove their dentures, so it seems necessary to invent a new form of denture.<sup>[10]</sup> Suzuki *et al.*<sup>[11]</sup> and Cheng *et al.*<sup>[12]</sup> constructed a sectional and collapsible denture for a partially edentulous

patient with microstomia.<sup>[11]</sup> Some authors have described the method of fabricating only collapsible dentures<sup>[13]</sup> and some have described only the sectional ones.<sup>[14]</sup> Another group of authors have fabricated sectional dentures using hinge and stud attachments for this denture design. Its advantage is the use of a custom-made hinge, which is more durable and less expensive.<sup>[15]</sup> In the dental literature, there are limited articles describing the method of making impressions for sectional dentures. Various snaps and keyways<sup>[11,14]</sup> and pins<sup>[5]</sup> have been used for the locking mechanism

of sectional impression trays. As Cheng *et al.*<sup>[12]</sup> stated, collapsible hinged mandibular complete denture is kept stable by tongue pressure in the lateral direction and resistance is provided by the ridge slopes. According to the authors, although the procedure is found to be time-consuming, the result is outstanding. The attachments used in this method provide more rigid attachment than magnets and there is no fear of loss of magnetic effects when using studs.<sup>[15]</sup>

In this clinical report, we used microcastable balls to increase retention and make it more convenient to insert and remove dentures. We also trained the patient to ensure that the dentures are inserted properly, hearing the click sound from the micro ball attachments. Another advantage is that separation in the maxillary denture, as we said in this study, did not reduce its esthetic aspect; whereas, other studies<sup>[1,2,10]</sup> may have considered esthetic criteria less acceptable. In this method, we separated the dentures in the premolar zone, which gave us more beauty as well as proper retention and stability. Ease of insertion and removal; cost-effectiveness; and provision of maximal coverage for support, retention, and stability can be regarded as the advantages of this kind of sectional denture. Increased laboratory works seem to be a limitation of this technique.

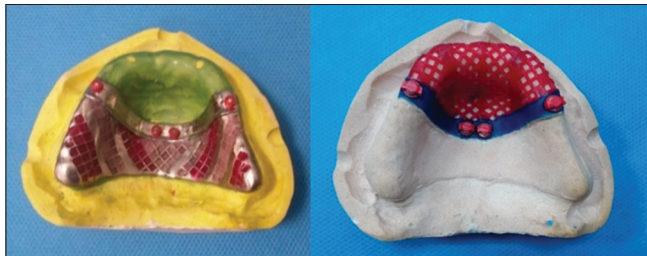

Figure 6: Waxy model.

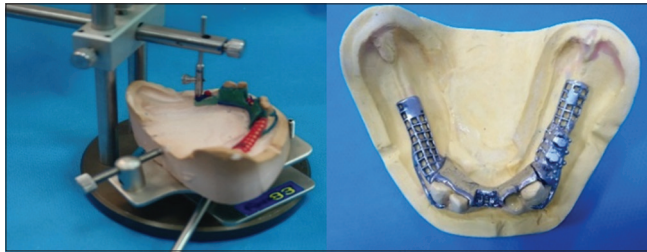


Figure 7: Process of mandibular substructure design, survey, and final mandibular substructure.

## CONCLUSION

The advantages of the sectional denture described in this clinical report are as follows:

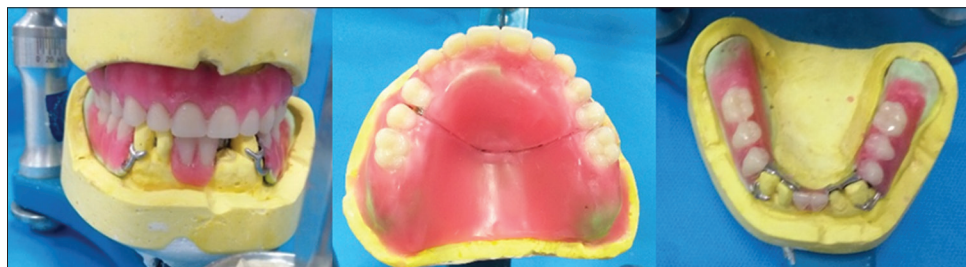
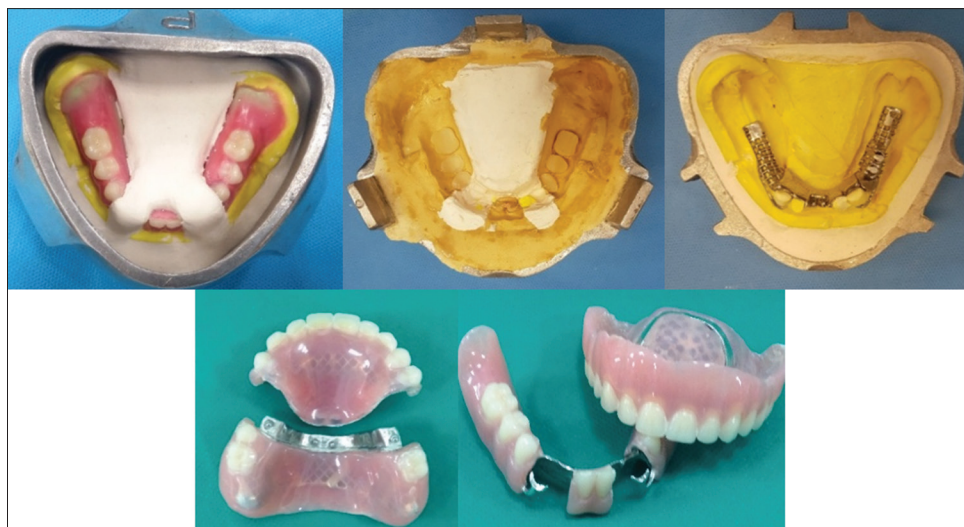
Figure 8: Teeth arrangement.



Figure 9: Maxillary processing.



**Figure 10:** Mandibular flasking procedure and finishing and polishing procedures.

- It is convenient to use due to ease of insertion and removal
- It is a practical and economical option to fabricate sectional denture
- Ball attachment incorporation ensures good retention between the two sections of the denture.

#### Financial support and sponsorship

Nil.

#### Conflicts of interest

The authors of this manuscript declare that they have no conflicts of interest, real or perceived, financial or non-financial in this article.

#### REFERENCES

1. Satpathy A, Gujjari AK. Complete denture in a microstomia patient. *J Clin Diagn Res* 2015;9:ZD16-8.
2. Kumar KA, Bhat V, Nair KC, Suresh R. Preliminary impression techniques for microstomia patients. *J Indian Prosthodont Soc* 2016;16:229-33.
3. Crincoli V, Fatone L, Fanelli M, Rotolo RP, Chialà A, Favia G, *et al.* Orofacial manifestations and temporomandibular disorders of systemic scleroderma: An observational study. *Int J Mol Sci* 2016;17. pii: E1189.
4. Nair CK, Sivagami G, Kunnekel AT, Naidu ME. Dynamic commissural splint. *Indian J Dent Res* 2008;19:165-8.
5. Cura C, Cotert HS, User A. Fabrication of a sectional impression tray and sectional complete denture for a patient with microstomia and trismus: A clinical report. *J Prosthet Dent* 2003;89:540-3.
6. Baker PS, Brandt RL, Boyajian G. Impression procedure for patients with severely limited mouth opening. *J Prosthet Dent* 2000;84:241-4.
7. McCord JF, Tyson KW, Blair IS. A sectional complete denture for a patient with microstomia. *J Prosthet Dent* 1989;61:645-7.
8. Luebke RJ. Sectional impression tray for patients with constricted oral opening. *J Prosthet Dent* 1984;52:135-7.
9. Bachhav VC, Aras MA. A simple method for fabricating custom sectional impression trays for making definitive impressions in patients with microstomia. *Eur J Dent* 2012;6:244-7.
10. Gauri M, Ramandeep D. Prosthodontic management of a completely edentulous patient with microstomia: A case report. *J Indian Prosthodont Soc* 2013;13:338-42.
11. Suzuki Y, Abe M, Hosoi T, Kurtz KS. Sectional collapsed denture for a partially edentulous patient with microstomia: A clinical report. *J Prosthet Dent* 2000;84:256-9.
12. Cheng AC, Wee AG, Morrison D, Maxymiw WG. Hinged mandibular removable complete denture for post-mandibulectomy patients. *J Prosthet Dent* 1999;82:103-6.
13. Benetti R, Zupi A, Toffanin A. Prosthetic rehabilitation for a patient with microstomia: A clinical report. *J Prosthet Dent* 2004;92:322-7.
14. al-Hadi LA. A simplified technique for prosthetic treatment of microstomia in a patient with scleroderma: A case report. *Quintessence Int* 1994;25:531-3.
15. Cheng AC, Kwok-Seng L, Wee AG, Tee-Khin N. Prosthodontic management of edentulous patient with limited oral access using implant-supported prostheses: A clinical report. *J Prosthet Dent* 2006;96:1-6.