

Original Article

Evaluation of CD24 and CD44 as cancer stem cell markers in squamous cell carcinoma and epithelial dysplasia of the oral cavity by q- RT-PCR

Majid Mirhashemi¹, Narges Ghazi^{1,2}, Nasrollah Saghravani^{1,2}, Ali Taghipour³, Farnaz Mohajertehran⁴

¹Department of Oral and Maxillofacial Pathology, School of Dentistry, Mashhad University of Medical Sciences, ²Oral and Maxillofacial Diseases Research Center, Mashhad University of Medical Sciences, ³Department of Biostatistics and Epidemiology, School of Health, Mashhad University of Medical Sciences, ⁴Dental Research Center, Mashhad University of Medical Sciences, Mashhad, Iran

ABSTRACT

Background: Squamous cell carcinoma (SCC) is the most common cancer of the oral cavity and may be preceded by dysplastic epithelial lesion. Oral SCC (OSCC) contains a rare subset of cancer cells with self-renewal ability, termed as cancer stem cells (CSCs). CD24 and CD44 as CSC markers are cell surface glycoproteins. These markers contribute to the onset, maintenance, and extension of tumor growth, as well as angiogenesis. In the present study, these two markers were simultaneously evaluated to provide a specific phenotype for carcinogenesis process in oral cavity.

Materials and Methods: In this analytical-cross-sectional study, the expression of CD24 and CD44 genes was evaluated in 45 OSCCs (20 low-grade and 25 high-grade) and 15 oral epithelial dysplasia specimens by real-time quantitative reverse transcription polymerase chain reaction. Kruskal–Wallis and Mann–Whitney U-test, Kendall, and Spearman tests were used for statistical analysis. The significance level was considered <0.05 .

Results: High expression of both markers genes was reported in two-thirds of samples. There was no significant difference between studied groups in gene expression of CD24 and CD44 whereas statistically significant association between CD24 and CD44 was observed in all three groups. This correlation was more significant in OSCC groups ($P < 0.001$).

Conclusion: High expression of CSC markers in OSCC and oral epithelial dysplasia revealed the importance of accurate examination of dysplastic lesions with high expression of these markers and the possibility of malignant transformation. Regarding a significant association of two markers, further studies are necessary to provide a specific phenotype (CD44 high CD24 high) for these lesions.

Key Words: Carcinoma, polymerase chain reaction, squamous cell

Received: March 2019

Accepted: July 2019

Address for correspondence:

Dr. Nasrollah Saghravani,
Department of Oral and
Maxillofacial Pathology,
School of Dentistry,
Mashhad University of
Medical Sciences, Mashhad,
Iran.

E-mail: saghravaniann@
mums.ac.ir

INTRODUCTION

Cancer is one of the major threats to public health, especially in developing countries. The most common oral cancer is squamous cell carcinoma (SCC), accounting for more than 90% of

the oral malignancies. Over the past few decades, despite several advances in surgery, radiotherapy, and chemotherapy, the five-year survival rate of oral

This is an open access journal, and articles are distributed under the terms of the Creative Commons Attribution-NonCommercial-ShareAlike 4.0 License, which allows others to remix, tweak, and build upon the work non-commercially, as long as appropriate credit is given and the new creations are licensed under the identical terms.

For reprints contact: reprints@medknow.com

How to cite this article: Mirhashemi M, Ghazi N, Saghravani N, Taghipour A, Mohajertehran F. Evaluation of CD24 and CD44 as cancer stem cell markers in squamous cell carcinoma and epithelial dysplasia of the oral cavity by q- RT-PCR. Dent Res J 2020;17:208-12.

Access this article online



Website: www.drj.ir
www.drjournal.net
www.ncbi.nlm.nih.gov/pmc/journals/1480

SCC (OSCC) has not been significantly improved, ranging from 50% to 55%.^[1]

Premalignant oral lesions are benign lesions with morphologically modified tissue, which has a greater than normal risk of malignant transformation.^[1] Therefore, detection of potentially malignant oral lesions is an important challenge.^[2]

OSCC contains a rare subset of cancer cells with self-renewal ability, termed as cancer stem cells (CSCs). Due to low levels of cell division, these cells are resistant to chemotherapy.^[3] Thus, investigation of CSCs markers and targeting them selectively is the focus of many cancer researches. The use of biomarkers to investigate the disease in the early stages can lead to the development of preventive therapeutic approaches to control the disease in the primary phase.^[4] CD24 and CD44 as CSC markers are cell surface glycoproteins. CD44 is a multifunctional transmembrane glycoprotein expressed in many types of cancer. This marker interferes with intercellular binding, migration, and angiogenesis of cancer cells.^[5] The standard form of CD44 (CD44s) expression has been reported in head and neck SCCs.^[6] CD24 is a single-stranded 27 amino acid protein with glycosylation at the end of O and N and is bound by an anchor of glycosylphosphatidyl inositol to the extracellular matrix and outer membrane of the cell.^[7]

In OSCC, a small subgroup of CSCs expressing CD24 and CD44 contributes to the onset, maintenance, and extension of tumor growth, as well as angiogenesis.^[8] The purpose of this study was to evaluate of CD24 and CD44 expression in oral epithelial dysplasia (pre-malignant lesion) and OSCC to determine the role of these markers in the carcinogenesis process of oral mucosa.

MATERIALS AND METHODS

In this analytical-cross-sectional study, sixty samples including 45 OSCCs (20 low-grade and 25 high-grade) and 15 oral epithelial dysplasia specimens with clinical diagnosis of leukoplakia were retrieved from the archives of Oral and Maxillofacial Pathology Department of Mashhad Dental School. To have proper sample size with definite diagnosis of dysplasia, moderate to severe dysplastic samples were selected. Grade I and II OSCC samples were defined as low-grade OSCC and were compared to the high-grade tumors (Grade III). Slides were evaluated and confirmed histologically by two pathologists

independently under a light microscope (Labomed, USA). On disagreement, final histopathological diagnosis was reached by a second reevaluation of the slides and by reevaluation of the histopathologic and operative reports. To investigate the expression of CD24 and CD44 genes in these specimens, 10 pieces of 5–10 µm of paraffin blocks were first prepared. Then, it was heated at 800 µL of xylene for 5 min. After that, 400 µl of absolute ethanol was added to it and centrifuged and its supernatant was discarded. RNA extraction was performed to do reverse-transcription technique on paraffin block tissues using the high pure RNA Paraffin Kit (Roche, Germany) according to the manufacturer's instructions. In the next step, using the Revert Aid First Strand cDNA Synthesis Kit (Thermos Scientific, Germany), 200 ng RNA from the previous step was reverse transcribed with OligodT at 65°C for 5 min in a reaction volume of 20 µl, and cDNA was made from RNA. Subsequently, the cDNA was subjected to real-time quantitative reverse transcription polymerase chain reaction (q-RT-PCR) using the SYBR green real-time PCR Master Mix Kit (Thermos Scientific, Germany) and the 7500 fast real-time PCR system (Applied Biosystems, USA).

The sequence of primers used for PCR was:

β-actin: F-5'-AGCGGGAAATCGTGCGTG-3',

R-5'-GGGTACATGGTGGTGCCG-3'

CD44: F-5'-CGGACACCATGGACAAGTTT-3',

R-5'-CCGTCCGAGAGATGCTGTAG-3'

CD24: F-5'-ACAGCCAGTCTCTTCGTGGT-3',

R-5'-CCTGTTTTTCCTTGCCACAT-3'.

The PCR condition consisted of 10 min at 95°C with hot start enzyme activation, 45 cycles of denaturation for 15 s at 95°C, annealing for 1 min at 62°C, and extension for 30 S at a temperature of 72°C. Three normal tissues from three donors were used as control samples. It should be noted that two times the PCR was performed in this study. The $\Delta\Delta\text{CT}$ method was used for gene expression and also for RT-PCR analysis by considering CD24 and CD44 as target genes and beta actin as control gene [Figures 1 and 2].

For statistical analysis, SPSS software (SPSS Inc., Chicago, IL, version 16.0 for windows) was used. Kruskal-Wallis and Mann-Whitney U-test, Kendall, and Spearman statistical tests were used for comparison between groups, within groups and also for the relationship between two markers,

respectively. The significance level was <0.05 for all statistical tests.

RESULTS

The samples were oral epithelial dysplasia (15 samples), low-grade OSCC (20 samples), and high-grade OSCC (25 samples). Statistical analysis between Grade I and Grade II OSCC did not show statistical difference. Therefore, Grade I and II OSCC samples were merged into low-grade OSCC and were compared to the high-grade tumors (Grade III).^[9] In the present study, the expression of two CSC markers – CD24 and CD44 – was studied in the three studied groups.

The expression of both genes based on cutoff point was reported as high expression and low expression.

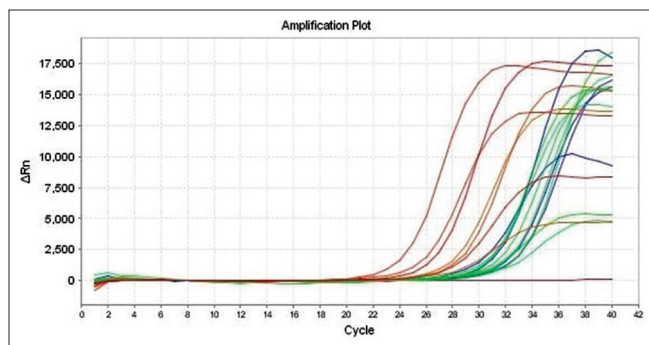


Figure 1: Amplification plot for CD24 and CD44 expression.

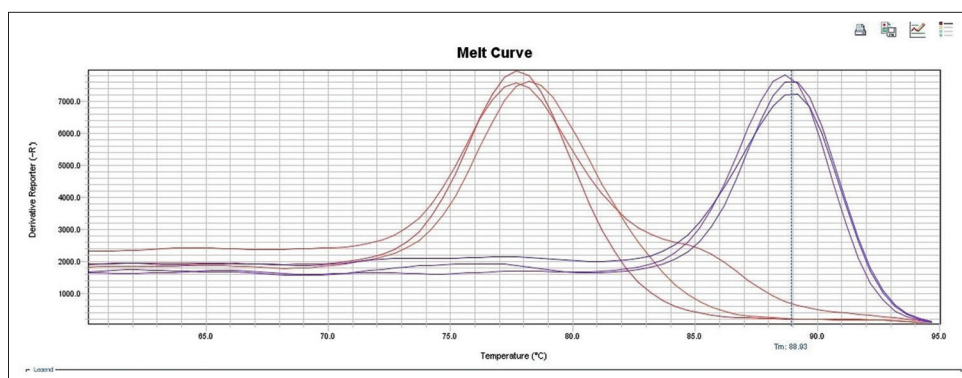


Figure 2: Melt curve for CD24 and CD44 expression.

The frequency of CD24 and CD44 gene expression is presented in Table 1. Approximately, two-thirds of both markers were reported as high expression. There was no significant difference between studied groups in gene expression of CD24 and CD44 according to Kruskal–Wallis statistical test, whereas comparison within the groups (using Kendall statistical test) showed a significant difference in the distribution of the marker below and above the cutoff point ($P < 0.001$, fold change ≥ 2).^[10]

In pairwise comparison of the groups, based on the gene expression of each marker, Mann–Whitney U-test did not find any significant relationship between the groups. Spearman’s rank correlation coefficient test was performed to assess the association between CD24 and CD44 in the studied groups. As presented in Table 2, significant correlation was observed in all three groups. This correlation was more significant in OSCC groups ($P < 0.001$).

DISCUSSION

SCC is the most common cancer of the oral cavity and may be preceded by dysplastic epithelial lesion. CSC hypothesis states that tumors like adult tissues arise from a small subpopulation of tumor cells with self-renewal ability. These cells have self-protection property and also an increased drug resistance capacity. Therefore, the limited success in available

Table 1: CD24 and CD44 expression in the studied groups

Sample	n (%)	CD24		CD44	
		Low expression, n (%)	High expression, n (%)	Low expression, n (%)	High expression, n (%)
Epithelial dysplasia	15 (25)	5 (33.3)	10 (66.7)	5 (33.3)	10 (66.7)
Low-grade SCC	20 (33.3)	7 (35)	13 (65)	7 (35)	13 (65)
High-grade SCC	25 (41.7)	5 (20)	20 (80)	11 (44)	14 (56)
Total	60 (100)	17 (28.3)	43 (71.7)	23 (38.3)	37 (61.7)

SCC: Squamous cell carcinoma

Table 2: Correlation of CD24 and CD44 in the studied groups

Sample	Correlation coefficient (r)	P
Epithelial dysplasia	0.537	0.037
Low-grade SCC	0.713	<0.001
High-grade SCC	0.682	<0.001

SCC: Squamous cell carcinoma

cancer treatment can be explained by inefficient elimination of these cells.^[3] CSCs are widely the focus of cancer researches to improve the overall survival (OS) of SCC patient.^[4] The purpose of this study was to evaluate CD24 and CD44 CSC markers in dysplastic epithelium as a premalignant lesion and OSCC. Association of CD24 and CD44 in cancer of breast, colorectal, and pancreas has been shown by previous studies. Therefore, in the present study, these two markers were simultaneously examined to provide a specific phenotype for carcinogenesis process in oral cavity.

In our previous study, the association of CD44 expression and clinicopathologic parameters of OSCC was investigated. Higher expression was reported in the OSCC with higher grade and stage, while a significant relationship between the CD44 immunoreactivity with gender, age, tumor site, and OS was not observed.^[11] However, Hema *et al.* showed that CD44s expression by tumor cells in OSCC significantly decreased with increasing grade. The highest CD44s expression was distinguished in the well-differentiated group, and the lowest expression was reported in the poorly differentiated group. Based on the results, they stated that decreasing the expression of CD44s in OSCC may result from reduced cell–cell or cell–matrix adhesion, which leads to the separation of cells. Therefore, the reduction of CD44 expression may be a marker of tumor invasion and high potential for metastasis.^[12]

In the study of de Moraes *et al.*, the expression of stem cell markers in OSCC was evaluated immunohistochemically. They reported that CD44 was positive in 30 of 52 cases (57.7%) and CD24 was expressed in 44 of 50 cases (88%). Furthermore, 5-year cancer-specific survival rates for CD44– and CD44+ groups were also 74% and 38%, respectively. Although this difference was not statistically significant, they concluded that CD44+ cells are associated with poor survival.^[13] In this present study, q-RT-PCR method was used and also dysplasia was evaluated. CD24 and CD44 were expressed in

33 (73%) and 27 (60%) OSCC cases, respectively, which is consistent with the above study with higher expression of CD24. The expression of both markers in dysplasia was also observed in 10 cases of 15 (66.6%).

In the study by Saleem *et al.*, oral tongue SCC metastatic lymph nodes exhibited higher levels of CD44/CD24 expression and faster formation of cancer cell spheres by immunohistochemistry (IHC) compared to healthy lymph nodes and noncancerous hyperplastic lesions.^[14] In our study, the high expression of both markers in the primary SCC of the oral cavity was reported.

Abdulmajeed *et al.*, evaluated various markers including CD24 and CD44 by IHC in normal tissue, dysplasia, and OSCC. The intensity of CD24 and CD44 expression in OSCC was higher than normal tissues. According to the results, they concluded that among the studied markers, CD24 is an effective marker to differentiate dysplasia and OSCC from normal tissue.^[15]

In the research by Ghuwalewala *et al.*, performed on the oral cancer cell line with q-RT-PCR method, CD44 (high) CD24 (low) was reported as a feature of stem cell-like cells. Although some authors disagree with this finding and suggest that CD44 (high) CD24 (high) is a phenotype of these cells. They also stated that CD24 had a negative effect on cell migration and epithelial-to-mesenchymal transition and concluded CD44 (high) CD24 (high) is an intermediate stem cell population between CSC (stem-like CD44 high CD24 low) and non-CSC (nonstem-like CD44 low CD24 high).^[16,17] As previously mentioned, we also evaluated dysplastic epithelium in our study. The expression of CSC markers was high in all samples (71.7% and 61.7% for CD24 and CD44, respectively). It should be noted that there was a significant association between two markers in all three groups with more significant relation in SCC groups ($P < 0.001$).

Oliveira *et al.* suggested that CD44 immunostaining and the lack of immunoexpression of CD24 and CD44 along with clinicopathological features influence the prognosis of OSCC.^[5]

Todoroki *et al.* (2016) demonstrated that CD44 v3+/CD24+ cells (OSCC cell lines OSC20 and SAS) was the highest proportion compared to other phenotypes (CD44 v3+/CD24–, CD44 v3–/CD24– and CD44 v3–/CD24+), which was 52% and 48.2% for OSC20 and SAS, respectively.^[7] In general,

the results showed that the cell population with CD44 v3+/CD24-phenotype exhibits cancer stem cell-like properties in the human OSCC cell line.^[7]

In breast cancer, CD44 (high) CD24 (low), and in pancreatic and colorectal cancer, CD44 (high) CD24 (high) has been reported by several studies.^[7,18,19] We examined the CD44 standard form (CD44s) in the present study, and in consistent with the above study, high expression of CD24 and CD44 markers was observed. Further studies seem to be necessary to confirm specific phenotype (CD44 high CD24 high) for CSCs of SCC and epithelial dysplasia of oral cavity.

CONCLUSION

In the present study, high expression of CD24 and CD44 genes in OSCC and oral epithelial dysplasia was observed. This revealed the possibility of progression to malignancy in dysplastic lesions with high expression of CSC markers. Therefore, accurate examination of epithelial dysplasia seems to be of significant importance. Regarding a significant association of two markers, further studies are necessary to provide a specific phenotype (CD44 high CD24 high) in potentially malignant oral lesions and OSCC, such as those of other organs.

Acknowledgement

This study was supported by a grant from the Vice Chancellor of Mashhad University of Medical Sciences, Iran.

Financial support and sponsorship

Nil.

Conflicts of interest

The authors of this manuscript declare that they have no conflicts of interest, real or perceived, financial or non-financial in this article.

REFERENCES

1. Neville BW, Damm DD, Allen CM, Chi AC. Oral and Maxillofacial Pathology. St. Louis, Missouri: Elsevier Health Sciences; 2016.
2. Scully C, Eisen D, Porter S, Rogers R. Dermatology of the Lips. Oxford: Isis Medical Media Ltd.; 2000.
3. Senoo M, Pinto F, Crum CP, McKeon F. P63 is essential for the proliferative potential of stem cells in stratified epithelia. *Cell* 2007;129:523-36.
4. Essers J, Theil AF, Baldeyron C, van Cappellen WA, Houtsmuller AB, Kanaar R, *et al.* Nuclear dynamics of PCNA

- in DNA replication and repair. *Mol Cell Biol* 2005;25:9350-9.
5. Oliveira LR, Castilho-Fernandes A, Oliveira-Costa JP, Soares FA, Zucoloto S, Ribeiro-Silva A. CD44+/CD133+ immunophenotype and matrix metalloproteinase-9: Influence on prognosis in early-stage oral squamous cell carcinoma. *Head Neck* 2014;36:1718-26.
6. Mack B, Gires O. CD44s and CD44v6 expression in head and neck epithelia. *PLoS One* 2008;3:e3360.
7. Todoroki K, Ogasawara S, Akiba J, Nakayama M, Naito Y, Seki N, *et al.* CD44v3+/CD24- cells possess cancer stem cell-like properties in human oral squamous cell carcinoma. *Int J Oncol* 2016;48:99-109.
8. Zimmerer RM, Ludwig N, Kampmann A, Bittermann G, Spalthoff S, Jungheim M, *et al.* CD24+ tumor-initiating cells from oral squamous cell carcinoma induce initial angiogenesis *in vivo*. *Microvasc Res* 2017;112:101-8.
9. Horn LC, Höhn AK, Hentschel B, Fischer U, Bilek K, Brambs CE. Prognostic relevance of low-grade versus high-grade FIGO IB1 squamous cell uterine cervical carcinomas. *J Cancer Res Clin Oncol* 2019;145:457-62.
10. Bhat-Nakshatri P, Appaiah H, Ballas C, Pick-Franke P, Goulet R Jr., Badve S, *et al.* SLUG/SNAI2 and tumor necrosis factor generate breast cells with CD44+/CD24- phenotype. *BMC Cancer* 2010;10:411.
11. Saghravanian N, Anvari K, Ghazi N, Memar B, Shahsavari M, Aghaee MA. Expression of p63 and CD44 in oral squamous cell carcinoma and correlation with clinicopathological parameters. *Arch Oral Biol* 2017;82:160-5.
12. Hema K, Rao K, Devi HU, Priya N, Smitha T, Sheethal H. Immunohistochemical study of CD44s expression in oral squamous cell carcinoma-its correlation with prognostic parameters. *J Oral Maxillofac Pathol* 2014;18:162-8.
13. de Moraes FP, Lourenço SV, Ianez RC, de Sousa EA, Silva MM, Damascena AS, *et al.* Expression of stem cell markers in oral cavity and oropharynx squamous cell carcinoma. *Oral Surg Oral Med Oral Pathol Oral Radiol* 2017;123:113-22.
14. Saleem S, Jamshed A, Faisal S, Hussain R, Tahseen M, Loya A, *et al.* Patterns of cancer cell sphere formation in primary cultures of human oral tongue squamous cell carcinoma and neck nodes. *Cancer Cell Int* 2014;14:542.
15. Abdulmajeed AA, Dalley AJ, Farah CS. Putative cancer stem cell marker expression in oral epithelial dysplasia and squamous cell carcinoma. *J Oral Pathol Med* 2013;42:755-60.
16. Ghuwalewala S, Ghatak D, Das P, Dey S, Sarkar S, Alam N, *et al.* CD44(high) CD24(low) molecular signature determines the cancer stem cell and EMT phenotype in oral squamous cell carcinoma. *Stem Cell Res* 2016;16:405-17.
17. Su YJ, Chang YW, Lin WH, Liang CL, Lee JL. An aberrant nuclear localization of E-cadherin is a potent inhibitor of wnt/ β -catenin-elicited promotion of the cancer stem cell phenotype. *Oncogenesis* 2015;4:e157.
18. Yeung TM, Gandhi SC, Wilding JL, Muschel R, Bodmer WF. Cancer stem cells from colorectal cancer-derived cell lines. *Proc Natl Acad Sci U S A* 2010;107:3722-7.
19. Li C, Heidt DG, Dalerba P, Burant CF, Zhang L, Adsay V, *et al.* Identification of pancreatic cancer stem cells. *Cancer Res* 2007;67:1030-7.