

Original Article

Comparison of accuracy of computed tomography scan and ultrasonography in the diagnosis of mandibular fractures

Saeed Nezafati¹, Mohamadali Ghavimi¹, Reza Javadrashid², Sina Farhadi², Vahid Dehnad¹

¹Department of Oral and Maxillofacial Surgery, Faculty of Dentistry, Tabriz University of Medical Sciences, ²Department of Radiology, School of Medicine, Tabriz University of Medical Sciences, Tabriz, Iran

ABSTRACT

Introduction: Ultrasonography (USG) allows to the examination of soft tissue and osseous tissues in the head-and-neck region. This study compared the accuracy of USG and computed tomography (CT) scan in the diagnosis of mandibular fractures.

Materials and Methods: In this prospective observational study, spiral CT scan was prescribed for the lower face and, if necessary, midface and upper face in 42 trauma patients suspected of mandibular fractures, referring to Imam Reza Hospital in Tabriz. Two radiologists evaluated the CT scans. Then, another radiologist examined all the patients with USG with a frequency of 7–12 MHz. Ultrasonographic diagnostic results were recorded and compared with the results of the CT scan examinations. The results were reported using descriptive statistical methods

Results: The specificity and sensitivity of USG were 100% and 91.1%, respectively. The USG sensitivities in the angle, condyle, condylar neck, and symphysis fractures were 100%, 91.6%, 85.7%, and 80%, respectively, and the specificity was 100% in all that anatomical regions. Among the confounding factors, the sensitivity of the USG (84.6%) was the lowest in the presence of hematoma; however, its specificity remained 100%. One case of symphysis fracture was not detected in the absence of any confounding factors in USG examination.

Conclusion: Although the sensitivity, specificity, and diagnostic accuracy of the USG were at high levels, there were some limitations, making it difficult to definitively replace USG with CT scans, especially in the case of condylar fractures and in the presence of confounding factors such as hematoma and swelling.

Key Words: Computed tomography scan, mandibular fracture, sensitivity, specificity, ultrasonography

Received: March 2019
Accepted: July 2019

Address for correspondence:
Dr. Vahid Dehnad,
Department of Oral and
Maxillofacial Surgery,
Faculty of Dentistry, Tabriz
University of Medical
Sciences, Azadi Street,
Tabriz, Iran.
E-mail: s.vahid.dehnad@gmail.com

INTRODUCTION

Maxillofacial injuries are often due to direct traumas, and since the mandible plays a major role in supplying the contour of the lower third of the face, it is more vulnerable to trauma and fracture.^[1-3]

Fractures are usually diagnosed through clinical examination and radiographic stereotypes such

as panoramic radiography. Sometimes, diagnosis by clinical examination, touch, and performance evaluation might be inaccurate and incorrect, especially in cases where the fracture line is more distal than the patient's dentition, or there is little

This is an open access journal, and articles are distributed under the terms of the Creative Commons Attribution-NonCommercial-ShareAlike 4.0 License, which allows others to remix, tweak, and build upon the work non-commercially, as long as appropriate credit is given and the new creations are licensed under the identical terms.

For reprints contact: reprints@medknow.com

How to cite this article: Nezafati S, Ghavimi M, Javadrashid R, Farhadi S, Dehnad V. Comparison of accuracy of computed tomography scan and ultrasonography in the diagnosis of mandibular fractures. *Dent Res J* 2020;17:225-30.

Access this article online



Website: www.drj.ir
www.drjjournal.net
www.ncbi.nlm.nih.gov/pmc/journals/1480

fracture displacement. In these cases, radiographic examination will be necessary.^[2,4,5]

Although simple films often provide enough information to detect maxillofacial fractures, the major disadvantages of these films are superimposition of facial structures and creation of a two-dimensional image (2D) of a 3D object. Since the introduction of the computed tomography (CT) scan in the late 1970s, these disadvantages have been resolved, and great advances have been made in the diagnosis of maxillofacial traumas, so that the facial structures in the coronal and axial planes, as well as 3D reconstruction, were provided for use in the treatment of facial traumas and congenital malformations. Hence, CT scans today are recognized as the diagnostic gold standard for facial fractures. Of course, CT scan also has some limitations and disadvantages such as failure to create a real-time image, high cost, the need for advanced equipment, inaccessibility to all treatment centers, high exposure, and artifacts due to the presence of metal objects. On the other hand, CT scan requires a patient's positioning, which is not possible in some cases, such as spinal cord injuries and patients' noncooperation. In addition, the use of CT scan is limited in pregnant women.^[4-6] Rapid advances in technology and developments in computer hardware have resulted in the introduction of ultrasonography (USG) technology, which, in addition to the examination of soft-tissue lesions, make it possible to examine the bone tissue of the head and neck.^[4,7,8] Due to the advantages of USG such as radiation removal and the creation of a real-time image, the use of this imaging technique has been considered as a substitute for CT scan and conventional radiography in the diagnosis of maxillofacial fractures.^[4,7,8]

In a systematic review, Adeyemo and Akadiri reviewed 17 papers related to the role of ultrasonographic diagnosis in maxillofacial traumas. Of the papers reviewed, only three articles evaluated mandibular fractures, with a sensitivity and specificity of about 66%–100% and 52%–100%, respectively.^[4] In a study by Weinberg *et al.*, the sensitivity and specificity of mandibular fracture diagnosis in 11 patients were 66% and 100%, respectively.^[9] In other studies, the sensitivity and specificity of USG were reported to be 88.2% and 100% for the diagnosis of zygomatic fractures,^[10] 73% and 92% for long bones,^[9] 100% and 100% for nasal bone,^[11] respectively. Although studies support the use of USG instead of CT scans in the

diagnosis of facial fractures, there are limitations that make it necessary to carry out new studies. One of these limitations is a small sample size, and the other limitation is the lack of consideration of confounding factors such as the presence of hematoma, swelling, and suturing of the traumatized region in previous studies.^[4,7]

In studies conducted on mandibular fracture, only a few areas of the mandible have been examined, and all the anatomical regions of the mandible have not been evaluated. Furthermore, in most studies, USG has been compared with simple radiography, and direct comparison with CT scan has not been performed.^[4] Therefore, the present study was designed to compare the accuracy of USG and CT scan in the diagnosis of fractures (with and without displacement) in all the anatomic regions of mandibular bone.

MATERIALS AND METHODS

This prospective observational study was conducted on trauma patients suspected of mandibular fracture referred to the Maxillofacial Surgery Clinic and Emergency Department of Imam Reza Hospital in Tabriz, Iran, from April 2017 to 2018.

Sampling

The sample size was determined at 42 samples using Adeyemo and Akadiri study,^[4] taking into account the 66% sensitivity of USG and 100% of CT scan, $\alpha = 0.05$, and a study power of 80%. The individuals were selected by convenient sampling and included in the study.

Inclusion and exclusion criteria

The inclusion criteria consisted of (1) patients aged between 18 and 60 years; (2) patients' consciousness and responsiveness; (3) one or more of the followings: asymmetry in the lower third of the face, hematoma, ecchymosis, limited jaw movement, impaired occlusion, deformity during mouth opening, pain and tenderness in the mandible area, and paresthesia of the inferior alveolar nerve; and (4) patients' trauma in the first 7 days.

Exclusion criteria consisted of (1) intubation; (2) unconsciousness of the patient; (3) Glasgow Coma Scale <15; (4) mental deterioration; and (5) instability of vital signs.

First, spiral CT scan in the coronal and axial sections of the lower face and, if necessary, the midface and upper face was administered for all the patients. These

stereotypes were evaluated by two radiologists who were unaware of the goals of the study. Diagnostic results of the CT scan were recorded and remained in a closed envelope until the end of the study. The intraclass correlation coefficient (ICC) was used to examine the interobserver reliability and intraobserver reliability, which was calculated about 98% and 100%, respectively.

Then, all the patients underwent USG examinations by a third radiologist who was not aware of the goals of the study. For this purpose, the patient was in a supine position, and a sterile gel was used at the site of examination. The radiologist used a linear probe with frequencies of 7–12 MHz (WS80A, Korea, 2015 Samsung) for ultrasonographic examination. The examination of the entire mandible was performed by a probe, and any bone loss or displacement was considered as a fracture. The ultrasonographic diagnostic results were recorded and kept in a closed envelope until the end of the study.

The ICC was used to examine the intraobserver reliability, which was calculated as 100%.

At the end of the study, the diagnostic results from CT scan and USG were recorded in a checklist and analyzed statistically.

Ethical considerations

All the stages of the study were explained to the patients, and informed consent was obtained. Companions of uneducated patients were asked to read and explain the procedures to the participants. The information of the patients participating in the study was protected based on ethical principles. This study was registered at the Medical Ethics Committee of Tabriz University of Medical Sciences under the code no. Ir.tbzmed.rdc.1397.476.

Statistical analysis

The results of the study were reported using descriptive statistical methods (mean ± standard deviation and frequency/percentage) using SPSS 17 (IBM Corp., Armonk, NY, USA). Ultrasonographic sensitivity and specificity, positive and negative predictive values, and accuracy were calculated and reported.

RESULTS

In this study, 42 patients suspected of mandibular fractures were studied, with a mean age of 30.57 ± 13.67 years (29 males [69%] and 13 females [31%]).

A complete examination of the mandible was performed by USG in <10 min; patients had no pain or discomfort during USG, except in cases of extensive hematoma [Figure 1].

The results of CT scan evaluation showed that 19 patients (45.2%) had no fractures and 23 (54.8%) had one or more mandibular fractures (a total of 34 fractures). Condyle and condylar neck with 12 cases (35.3%) and angle and body each with 7 cases (20.6%) were the most frequent fractures.

For all the 19 patients with no fractures in CT scan examinations, no fracture was also reported in USG. In Table 1, CT scan and ultrasonographic diagnostic results were compared in patients with fracture. As shown, one fracture was missed in USG in each of the condylar, body, and symphysis areas.

Table 2 compares the results of the CT scan and ultrasonographic diagnoses in terms of the confounding factors. Hematoma in fractures in 13 cases (38.2%), abrasion in 5 cases (14.7%), suturing of the fracture area in 3 cases (9%), and previous laceration in 2 cases (5.8%) were reported as confounding factors. One case of subcondylar

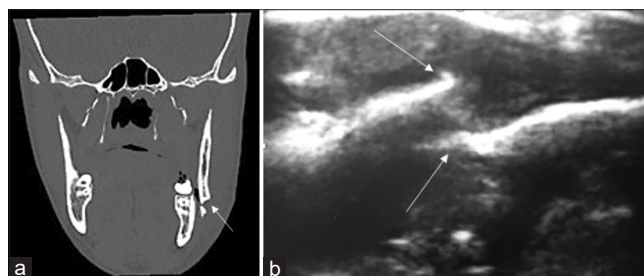


Figure 1: Computed tomography scan (a) and ultrasonography (b) images showing mandibular fracture.

Table 1: Frequency (percentage) comparisons of computed tomography scan and ultrasonographic results in different mandibular regions

Anatomic region	Frequency (%)	
	Diagnostic results of CT	Diagnostic results of USG
Condyle and condylar neck	12 (35.3)	11 (32.4)
Angle	7 (20.6)	7 (20.6)
Body	7 (20.6)	6 (17.6)
Symphysis	5 (14.7)	4 (11.7)
Ramus	1 (2.93)	1 (2.93)
Coronoid process	1 (2.93)	1 (2.93)
Alveolar bone	1 (2.93)	1 (2.93)
Undiagnosed fracture	0	3 (9)
Total	34 (100)	34 (100)

CT: Computed tomography; USG: Ultrasonography

fracture and one case of body fracture in the presence of hematoma were not detected in USG. One case of symphysis fracture was not detected in the absence of any confounding factor in USG.

Sensitivity, specificity, positive predictive value, and negative predictive value of USG are shown in Table 3.

DISCUSSION

An ultrasound is a form of energy that is caused by high-frequency mechanical vibrations, and the human ear cannot hear it. USG, introduced for the first time in World War II, is a noninvasive diagnostic procedure, does not produce ionizing radiation, has no biological risks, and has a fast and painless application.^[4,7]

In this study, like many previous studies,^[4,9] USG specificity (100%) was significantly higher than its sensitivity (91.1%). The USG sensitivity in the

angle, condyle, condylar neck, and symphysis was 100%, 91.6%, 85.7%, and 80%, respectively, and its specificity was 100% in all the anatomical regions. Among the confounding factors, the sensitivity of the USG (84.6%) was the lowest in the presence of hematoma. However, its specificity remained 100%.

Weinberg *et al.* in a study on 212 children and adolescents under 25 years of age reported that the sensitivity and specificity of USG (7.5–10 MHz) to detect mandibular fractures were 67% and 100%, respectively.^[9]

In a study by Nezafati *et al.* in 2010 on 17 patients with arch fractures with a 7.5 MHz USG, its sensitivity, specificity, and positive predictive value were 88.2%, 100%, and 100%, respectively, compared to CT scan and submentovertebral radiography.^[10]

Sreeram and Mandava in 2016 compared the diagnostic accuracy of USG and CT scan in 40 patients with

Table 2: Frequency (percentage) comparisons of computed tomography scan and ultrasonography diagnostic results in terms of the presence of confounding factors

Anatomic region	Confounding factors (%)								No confounding factor (%)	
	Suturing		Hematoma		Abrasion		Previous laceration		CT	USG
	CT	USG	CT	USG	CT	USG	CT	USG		
Condyle and condylar neck	1 (2.9)	1 (2.9)	4 (11.7)	3 (9)	2 (5.8)	2 (5.8)	1 (2.9)	1 (2.9)	5 (14.7)	5 (14.7)
Angle	1 (2.9)	1 (2.9)	1 (2.9)	1 (2.9)	2 (5.8)	2 (5.8)	1 (2.9)	1 (2.9)	3 (9)	3 (9)
Body	1 (2.9)	1 (2.9)	6 (17.6)	5 (14.7)	0	0	0	0	1 (2.9)	1 (2.9)
Symphysis	0	0	1 (2.9)	1 (2.9)	1 (2.9)	1 (2.9)	0	0	3 (9)	2 (5.8)
Ramus	0	0	0	0	0	0	0	0	1 (2.9)	1 (2.9)
Coronoid process	0	0	0	0	0	0	0	0	1 (2.9)	1 (2.9)
Alveolar bone	0	0	1 (2.9)	1 (2.9)	0	0	0	0	0	0
Undiagnosed fracture	0	0	0	2 (5.8)	0	0	0	0	0	1 (2.9)
Total	3 (9)		13 (38.2)		5 (14.7)		2 (5.8)		14 (41.1)	

CT: Computed tomography; USG: Ultrasonography

Table 3: Ultrasonographic sensitivity, specificity, positive predictive value, negative predictive value, and accuracy

Confounding factors	Sensitivity	Specificity	Positive predictive value	Negative predictive value	Accuracy
Suturing	100	100	100	100	100
Hematoma	84.6	100	100	90.4	93.7
Abrasion	100	100	100	100	100
Previous laceration	100	100	100	100	100
Presence of confounding factors	91.3	100	100	90.4	95.2
Absence of confounding factors	92.8	100	100	95	96.9
Anatomic area**					
Condyle and condylar neck	91.6	100	100	95	96.7
Angle	100	100	100	100	100
Body	85.7	100	100	95	96.1
Symphysis	80	100	100	95	95.8
Total	91.1	100	100	86.3	94.3

**Because there was only one data source in other anatomical regions, the determination of sensitivity, the specificity, and positive and negative predictive values is meaningless

different fractures in the facial bone (17 patients with mandibular fractures). The results showed that sensitivity, positive predictive value, and accuracy of USG for the diagnosis of 17 mandibular fractures were 94.1%, 95%, and 94.1%, respectively. Of the 17 patients with mandibular fracture, fractures were correctly diagnosed in 16 patients. Two fractures were undiagnosed in a total of 40 patients. One case had a high condylar fracture, and one had a pure blownout/medial wall of orbit fracture. Because there was no real negative diagnosis in this study, the specificity of the diagnostic tests was not computed.^[12] In the current study, the diagnostic accuracy of the USG was 94.3%, which is very close to the result of the above study.

Adeyemo and Akadiri in a systematic review in 2011 evaluated 17 papers for the role of ultrasonographic diagnosis in maxillofacial traumas. Of the papers reviewed, only three papers evaluated mandibular fractures, with an overall sensitivity and specificity of about 66%–100% and 52%–100%, respectively. Of course, none of these three studies used CT scan, and USG results were compared with simple radiography or diagnosis during surgery.^[4]

In the present study, the sensitivity and specificity of USG were 91.1% and 100%, respectively. In cases where the specificity of a test for fracture diagnosis is high, a positive result indicates a definite fracture (Rules IN). In cases where the sensitivity of the test for the diagnosis of fractures is high, a negative result indicates a nonfracture (Rules OUT).^[9] Therefore, based on the results of the present study, which showed that the USG had a higher specificity, it can be concluded that USG is more applied to the mandible fractures Ruling IN than Ruling OUT.

It is important to note that with a change in the prevalence of a disease, there is a change in the sensitivity and specificity of the diagnostic method of the study; in this context, as the incidence of a disease increases, the sensitivity increases, and with a decrease in the prevalence of a disease, the specificity increases.^[9,13] In the present study, the fracture rate (in other words, the prevalence of the disease) was 54.8%; in the study of Weinberg *et al.*, it was 27%,^[9] with 100% in the study by Nezafati *et al.*^[10] and 100% in the study by Sreeram and Mandava.^[12] Therefore, the differences in the sensitivities and specificities reported in various studies can be justified. Another point that can be a factor in the different reported sensitivities is the impact of the ultrasonographic operator's skill and

experience on the reported sensitivity rate. This point has been mentioned in previous studies as one of the disadvantages of USG.^[14]

The positive predictive value (part of the cases with positive test and suffering from the disease) and the negative predictive value (part of the cases with negative tests that are healthy) were 100% and 86.3%, respectively. In previous studies, only positive predictive value was reported, which was 100% in all the cases.^[9,10]

In the present study, the presence of hematoma in the area caused both pain and discomfort for the patient during USG, and incorrect diagnosis in USG of the condylar region and the body. In the present study, the sensitivity and diagnostic accuracy of USG in the presence of hematoma decreased by 84.6% and 93.7%, respectively. In contrast, the presence of laceration, suturing, and abrasion had no effect on the reduction of USG diagnostic accuracy. Similar to the results of the present study, in the study by Sreeram and Mandava, a case with high condylar fracture was not observed in USG due to superimposition of the zygomatic arch and with the condyle head located inside the articular capsule in the glenoid fossa.^[12]

Friedrich *et al.* evaluated 33 patients with condylar and mandibular ramus fractures with 7.5 MHz USG, reporting that the diagnosis of fractures, especially in the condylar region, was limited in the case of medial and lateral superimposition (curtain effect) and only the piece closer to the ultrasonographic probe was observable.^[15]

It has also been mentioned in previous studies that the presence of swelling, emphysema, and tenderness in the trauma region causes pain and discomfort to the patient and might make it difficult to observe bone and fracture, ultimately decreasing diagnostic accuracy.^[10,16] Sallam *et al.* proposed the use of an ultrasonographic device with frequencies below 7.5 MHz to overcome this problem.^[16] In the current study, the frequency of the USG device was 7–12 MHz.

In this study, the USG process did not last for more than 10 min for each patient, which was much lower than the required time for CT scan (25 min) or routine radiography (15 min). If we consider the time required to process the film, the time taken to carry out a CT scan or radiographic examination will be much longer.^[10]

Limitations and suggestions

In the present study, a radiologist with an experience of about 25 years performed all the ultrasound examinations. Previous studies have shown that the

skill and experience of radiologists directly affect diagnostic accuracy.^[16] Therefore, it is suggested that in future studies, several radiologists with different experiences should be used and their diagnostic results should be compared. It is also suggested that before the study, a training course should be held for each of the radiologists to enhance their skills and experience, and the impact of this training course on the outcome of the study should be examined.

In previous studies, another application of USG was the evaluation of the bone regeneration process because, with the help of the USG, we can clearly see how the callus is formed.^[12,14] It is suggested that in future studies, the use of USG should be considered for patients' posttreatment follow-up with the aim of examining the possibility of replacing USG with radiography for monitoring bone regeneration process. Researchers have also recommended that a higher diagnostic accuracy is required to scan the area in different planes and avoid transducer angulation when moving on the patient's body as the angulations of the transducer produce a similar appearance to the cortical bone fracture.^[14] Therefore, when examining angulated facial areas with USG such as symphysis or arches, the use of conventional converters can be challenging. It is suggested that in subsequent studies, modified transducers that match with the anatomy of the area should be used.

CONCLUSION

Although the sensitivity (91.1%), specificity (100%), and diagnostic accuracy (94.3%) of the USG were high in the current study, there are still concerns about the definitive replacement of USG with CT scan, especially in the case of condylar fracture and the presence of confounding factors such as hematoma and swelling. In cases where the use of a CT scan is limited due to reasons such as pregnancy or cervical vertebral injury, USG might be helpful. By reducing the need for patients' exposure, cost, and time, USG can be useful during follow-up period in evaluating the bone regeneration process or during surgery to determine the amount of fracture reduction.

Financial support and sponsorship

The study was self-funded by the authors and their institution.

Conflicts of interest

The authors of this manuscript declare that they have no conflicts of interest, real or perceived, financial or non-financial in this article.

REFERENCES

1. Afrooz PN, Bykowski MR, James IB, Daniali LN, Clavijo-Alvarez JA. The epidemiology of mandibular fractures in the United States, part 1: A review of 13,142 cases from the US national trauma data bank. *J Oral Maxillofac Surg* 2015;73:2361-6.
2. Morris C, Bebeau NP, Brockhoff H, Tandon R, Tiwana P. Mandibular fractures: An analysis of the epidemiology and patterns of injury in 4,143 fractures. *J Oral Maxillofac Surg* 2015;73:951.e1-12.
3. Nezafati S, Mortazavi A, Arta SA, Yazdani J, Ghanizadeh M. Treatment and complications of patients with zygomatic fractures referring to imam Reza hospital in a 2-year period. *Trauma Mon* 2018;23:e58039.
4. Adeyemo WL, Akadiri OA. A systematic review of the diagnostic role of ultrasonography in maxillofacial fractures. *Int J Oral Maxillofac Surg* 2011;40:655-61.
5. Vithani K, Patel S, Kingsmill G, Bater M, Eaton K. Incidence, aetiology, pattern and management of mandibular fractures treated at the regional maxillofacial unit, royal surrey county hospital, guildford: A 3-year retrospective study. *Br J Oral Maxillofac Surg* 2016;54:e116-7.
6. Vela JH, Wertz CI, Onstott KL, Wertz JR. Trauma imaging: A literature review. *Radiol Technol* 2017;88:263-76.
7. Evirgen Ş, Kamburoğlu K. Review on the applications of ultrasonography in dentomaxillofacial region. *World J Radiol* 2016;8:50-8.
8. Javadrashid R, Khatoonabad M, Shams N, Esmaeili F, Jabbari Khamnei H. Comparison of ultrasonography with computed tomography in the diagnosis of nasal bone fractures. *Dentomaxillofac Radiol* 2011;40:486-91.
9. Weinberg ER, Tunik MG, Tsung JW. Accuracy of clinician-performed point-of-care ultrasound for the diagnosis of fractures in children and young adults. *Injury* 2010;41:862-8.
10. Nezafati S, Javadrashid R, Rad S, Akrami S. Comparison of ultrasonography with submentovertex films and computed tomography scan in the diagnosis of zygomatic arch fractures. *Dentomaxillofac Radiol* 2010;39:11-6.
11. Lee MH, Cha JG, Hong HS, Lee JS, Park SJ, Paik SH, *et al.* Comparison of high-resolution ultrasonography and computed tomography in the diagnosis of nasal fractures. *J Ultrasound Med* 2009;28:717-23.
12. Sreeram M, Mandava R. Use of ultrasound as a scree maxillofacial fractures. *Int Med J* 2016;3:573-7.
13. Brenner H, Gefeller O. Variation of sensitivity, specificity, likelihood ratios and predictive values with disease prevalence. *Stat Med* 1997;16:981-91.
14. Moritz JD, Berthold LD, Soenksen SF, Alzen GF. Ultrasound in diagnosis of fractures in children: Unnecessary harassment or useful addition to X-ray? *Ultraschall Med* 2008;29:267-74.
15. Friedrich RE, Plambeck K, Bartel-Friedrich S, Giese M, Schmelzle R. Limitations of B-scan ultrasound for diagnosing fractures of the mandibular condyle and ramus. *Clin Oral Investig* 2001;5:11-6.
16. Sallam M, Khalifa G, Ibrahim F, Taha M. Ultrasonography vs. computed tomography in imaging of zygomatic complex fractures. *J Am Sci* 2010;6:524-33.