

Original Article

Efficacy of exenatide, ozone, and methyl prednisolone for the recovery of infraorbital nerve paresthesia after injury in rats

Mehdi Abrishami¹, Arash Golestaneh¹, Laleh Maleki², Hasan Momeni¹, Mazyar Manshaei³

¹Department of Oral and Maxillofacial Surgery, School of Dentistry, Islamic Azad University, Isfahan (Khorasgan) Branch, ²Department of Oral and Maxillofacial Pathology, Dental Research Center, Dental Research Institute, Isfahan University of Medical Sciences, ³Dental Research Center, Dental Research Institute, Isfahan University of Medical Sciences, Isfahan, Iran

ABSTRACT

Background: Infraorbital nerve injury often occurs due to zygomatic complex fracture. There is no standard protocol to restore the sensory and motor function of the nerve after injury. Some medications are used to improve nerve function. This histopathological animal study aimed to assess the neurotrophic efficacy of exenatide, ozone, and methyl prednisolone for injured infraorbital nerve. **Materials and Methods:** In this animal study, 60 rats were randomly divided into five groups ($n = 12$) of control, saline, methyl prednisolone, exenatide, and ozone. Under general anesthesia, a unilateral infraorbital incision was made, and the nerve was compressed with a hemostat for 5 s. Depending on the study group, the rats received the designated medications. All rats were sacrificed after 14 days, and the nerve recovery was evaluated by observing the slides prepared from the area under a light microscope using histological and immunohistochemical parameters. Data were analyzed using Chi-square test and Tukey's least significant difference test ($P < 0.05$).

Results: No inflammation in the peripheral tissue had a significantly higher frequency in the methyl prednisolone group ($P < 0.05$). Degeneration, intracellular inflammatory infiltrate, muscle injury, fibrosis around the nerve, granulation tissue, vascular proliferation, and infiltration of inflammatory cells around the nerve were more commonly absent in the exenatide group ($P < 0.05$).

Conclusion: Exenatide showed superior efficacy for the recovery of infraorbital nerve function after injury. Thus, it may be beneficial for postoperative care following infraorbital nerve injury.

Key Words: Exenatide, infraorbital nerve, methylprednisolone, nerve injury, ozone

Received: 23-Sep-2019
Revised: 19-Feb-2020
Accepted: 03-May-2020
Published: 24-May-2021

Address for correspondence:
Dr. Arash Golestaneh,
Department of Oral and
Maxillofacial Surgery,
School of Dentistry,
Islamic Azad University,
Isfahan (Khorasgan)
Branch, Isfahan, Iran.
E-mail: mehdiabrishami00@
gmail.com

INTRODUCTION

The zygomatic complex fracture is a common type of fracture in maxillofacial trauma patients. Infraorbital nerve injury often occurs in this type of fracture. Infraorbital nerve is a branch of the maxillary nerve that innervates the cheeks, upper lip, inferior eyelid, part of the nasal vestibule, maxillary teeth, and maxillary gingiva.^[1] Patients report neurosensory

disturbances of infraorbital nerve in 30–90% of the cases following midface trauma.^[1]

Following peripheral nerve injury, complete recovery of the nerve function cannot be achieved except by precise standard surgical interventions. Recent advances in technology and widespread use of

This is an open access journal, and articles are distributed under the terms of the Creative Commons Attribution-NonCommercial-ShareAlike 4.0 License, which allows others to remix, tweak, and build upon the work non-commercially, as long as appropriate credit is given and the new creations are licensed under the identical terms.

For reprints contact: WKHLRPMedknow_reprints@wolterskluwer.com

How to cite this article: Abrishami M, Golestaneh A, Maleki L, Momeni H, Manshaei M. Efficacy of exenatide, ozone, and methyl prednisolone for the recovery of infraorbital nerve paresthesia after injury in rats. Dent Res J 2021;18:35.

Access this article online



Website: www.drj.ir
www.drjjournal.net
www.ncbi.nlm.nih.gov/pmc/journals/1480

microscopes have enabled reattachment of the nerve ends by epineural or perineural sutures, increasing the success rate of surgical repair of the nerves.^[2]

Early fixation of fracture does not cause nerve recovery; thus, surgery does not play an important role in the prevention of neurosensory disturbances. Inappropriate fixation is not the main cause of continuous neurosensory disturbances either. A crush injury results in partial loss of nerve function with a relatively fast recovery due to postsynaptic reactions to peripheral stimuli. Mechanical compression of infraorbital nerve partially blocks its conductance.^[1]

Peripheral nerves may be injured due to mechanical (compression, tension, and crushing), thermal, chemical, and ischemic traumas. Paresthesia is a common complication of nerve injury and is defined as an unpleasant sense perceived by the patient, which is not painful.^[3] The main goal of treatment after injury is to regain the neuronal integrity and restore the nerve function and conduction.^[4]

Several peptides can affect the nerves and induce nerve tissue regeneration, which are referred to as neurotrophic factors.^[4] In contrast to the central nervous system, the peripheral nerves can regenerate after injury. Axonotmesis may occur due to a crush injury. Although the endoneurium remains intact after axonotmesis, axonal damage, and Wallerian degeneration often occur at the distal part of the injured nerve. Failure may occur due to neuronal death secondary to injury or atrophy of the organ, which may be due to the prolongation of denervation and axonal extension in an incorrect direction.^[5]

In recent years, several methods have been suggested to improve the function of infraorbital nerve after injury. However, there is no standard technique to restore the sensory and motor function of the nerve. Nerve regeneration following trauma is impaired due to oxidative stresses. Antioxidants may decrease the adverse effects of oxygen radicals on nerve regeneration. Ozone is a strong antioxidative agent with antimicrobial, antiviral, and antifungal properties. Ozone enhances tissue oxygenation and induces the release of cytokines. It is used for the treatment of chronic and diabetic ulcers.^[6] It exerts its positive effect by inhibition of infection, regulation of inflammation, and increasing the oxygen pressure at the injured site. It is also used for the treatment of infected and necrotic ulcers and tissues with poor oxygenation.^[6] Ozone can improve angiogenesis and

vascularization of the connective tissue following nerve injury. It enables more efficient delivery of oxygen and nutrients to the wound site and enhances the course of healing as such.^[6]

Glucagon-like peptide-1 (GLP1) is a polypeptide hormone composed of 30 amino acids, which is released by the endocrine cells of the small intestine. The GLP1 receptors have been detected in the central and peripheral nervous systems. It seems that GLP1 exerts its neurotropic effects through these receptors.^[4] Exendin-4 is the most suitable analog of GLP1 in nature, which is extracted from the saliva of a special type of alligator known as the Gila monster.^[7] Exenatide is a synthetic analog of Exendin-4, which is currently used intracutaneously for the treatment of Type II diabetes.^[8] Recent studies on GLP1 analogs have reported that they can improve degenerative changes of the central and peripheral nerves in diabetic rats.^[9] Another study assessed the effect of exendin-4 on regeneration of peripheral nerves in mice after sciatic nerve injury and observed positive electrophysiological, functional, and histological changes within 4 weeks following the use of Exendin-4.^[10] When exenatide is used for the treatment of peripheral nerve injury, weight loss is not considered as a side effect of this treatment.^[11]

Glucocorticoids are commonly used following maxillofacial surgical procedures because of their anti-inflammatory and anti-swelling properties. They play an important role in the recovery of nerve function after injury^[12] and can enhance nerve regeneration. However, their efficacy for this purpose should be confirmed in clinical trials. Corticosteroids have positive pharmacological advantages. When used within the first 24 h following nerve injury, they directly affect the secondary neuronal degeneration.^[12] They decrease capillary permeability and swelling around the nerve.^[12]

Methyl prednisolone is a nerve protective agent. It prevents lipid peroxidation and decreases the degenerative changes after injury.^[6] Its mechanism of action is through the prevention of lipid peroxidation and pro-inflammatory cytokines, protection of calcium homeostasis, reinstatement of regional blood circulation, and regulation of inflammation.^[6]

Considering the limited number of studies on the recovery of infraorbital nerve function after trauma and high frequency of motor vehicle accidents in Iran that cause infraorbital nerve injury, this

histopathological animal study aimed to assess the neurotrophic effects of different medications on the injured infraorbital nerve.

MATERIALS AND METHODS

This animal study evaluated 60 male Wistar Albino rats between 12 and 14 weeks weighing 300 and 360 g. The rats were recruited using convenience sampling. The sample size was calculated to be 12 in each group (a total of 60) assuming $\alpha = 0.06$, accuracy (d) = 94%, and $Z = 95\%$.

The study was approved by the Ethics Committee of Islamic Azad University, School of Dentistry, Isfahan (IR.IAU.KHUISF.REC.1397.128). The rats were kept in a calm environment with controlled temperature and humidity according to Welfare guidelines.^[13] The rats were randomly divided into five groups ($n = 12$) as follows:

- Group 1 (control group): The rats were sacrificed without any intervention and their infraorbital nerve was removed
- Group 2: After surgery and traumatization of the nerve, the rats in this group received 1 mg/kg saline for 14 days and were sacrificed afterward
- Group 3: After surgery and traumatization of the nerve, the rats in this group received daily injections of 2 mg/kg methyl prednisolone acetate (Caspian Tamin Pharmaceutical Co., Rasht, Iran) for 14 days and were then sacrificed
- Group 4: After surgery and traumatization of the nerve, the rats in this group received daily injections of 10 μ g exenatide (Astra Zeneca, Wolmington, DE, USA) for 14 days and were then sacrificed
- Group 5: After surgery and traumatization of the nerve, the rats in this group received daily injections of 20 mcg/ml ozone for 14 days and were then sacrificed.

All injections were made at the infraorbital notch. The dosage of medications was determined based on a previous study.^[5,6]

Surgical phase

All rats were generally anesthetized by intramuscular injection of 5 mg/kg of 10% ketamine (Alfasan, Woerden-Holland) and 0.02 mL/kg acepromazine maleate (Neurotranq, Alfasan, Woerden-Holland). Next, 0.3 mL of 2% lidocaine containing 1:80,000 epinephrine (Persocaine-E, Darou Pakhsh, Tehran, Iran) was injected for local anesthesia and hemostasis

at the surgical site. The surgical area was shaved and disinfected with povidone-iodine (Behvazan Co., Rasht, Iran). A unilateral infraorbital incision was made through the Whisker pad with 1 cm length. Dissection was performed to expose the infraorbital nerve. Then, the nerve was compressed by a hemostat for 5 s.

Under sterile conditions, the subcutaneous and cutaneous tissues were sutured with 5-0 vicryl (Polyglycolate Coated, Supa Co., Tehran, Iran) and 6-0 nylon (Monofilament Polyamide, Supa Co., Tehran, Iran) sutures. All surgical procedures were performed by the same surgeon. All rats received 1 mg/kg tramadol (Tramadic, 50 mg/ml, Caspian Tamin, Rasht, Iran) for pain relief and 25 mg/kg cefazolin (Ancef; Kefzol, 1 gr, Razi, Iran) intramuscularly twice a day for 5 days, postoperatively. Furthermore, all rats were fed soft foods for 1 week. All injections were performed painlessly under inhalation anesthesia.

Immunohistochemistry

CD34 (Dako, USA) immunohistochemistry (IHC) staining was used to ensure the presence of blood vessels and vascularization while CD68 (Dako, USA) IHC staining was used to ensure the presence of macrophages and the process of neurodegeneration. In axonal degeneration, due to the destruction of the myelin sheath, macrophages migrate to the area to eliminate debris. For the positive control of CD68 and CD34, the human tonsillar tissue was used. For negative control, primary antibodies were eliminated. All slides (CD68, CD34, H and E) were inspected by a pathologist under a light microscope (BX-51, Olympus, Tokyo) at $\times 40$, $\times 100$, and $\times 400$ magnifications. The slides had been coded, and the pathologist was blinded to the group allocation of slides.

Histological parameters

Histological parameters evaluated in this study included intraneural and perineural inflammatory cell infiltration, determined by the observation of dominantly chronic inflammatory cells (lymphocytes and plasma cells) at $\times 100$ and $\times 400$. In addition, the presence of abundant dense collagen fibers around the nerve was considered as perineural fibrosis. Increased vascularization around the nerve was considered as perineural vascularization ($\times 100$).

In order to assess perineural granulation tissue, the presence of numerous small blood vessels along with mainly chronic inflammatory cells (lymphocytes and

plasma cells) around the nerve cross-sections was evaluated under $\times 100$ and $\times 400$. The observation of macrophages in muscular tissue, muscle injury, and observation of inflammatory cells in the surrounding tissue suggested the diagnosis of inflammation in perineural tissue ($\times 100$ and $\times 400$). Next, the nerve cross-sections were observed under a light microscope at $\times 100$ and $\times 400$ and the results were reported as no degeneration (normal nerve cross-sections with no sign of degeneration), mild degeneration (observing degeneration, mild vacuolization, and damage to axon and its myelin sheath), and severe degeneration (presence of extensive mucoid degeneration, nerve laceration or injury to its sheath) [Figures 1-6].

Statistical analysis

Data were analyzed using SPSS version 22 (IBM, New York, USA). The groups were compared using Chi-square test. Pairwise comparisons were

performed using the Tukey's least significant difference test. The level of significance was set at 0.05.

RESULTS

Table 1 shows the frequency distribution of different histological parameters in the five groups. As shown, the absence of peripheral inflammation in methyl prednisolone group had a higher frequency than exenatide and ozone groups. The Chi-square test showed a significant difference in this regard among the five groups ($P = 0.001$). The absence of degeneration had a higher frequency in the exenatide group compared with ozone and methyl prednisolone groups. Furthermore, the frequency percentage of severe degeneration in the saline group was higher than mild degeneration, while this ratio in other groups was reverse. In other words, the percentage of mild degeneration in methyl prednisolone, exenatide, and ozone group were significantly higher than

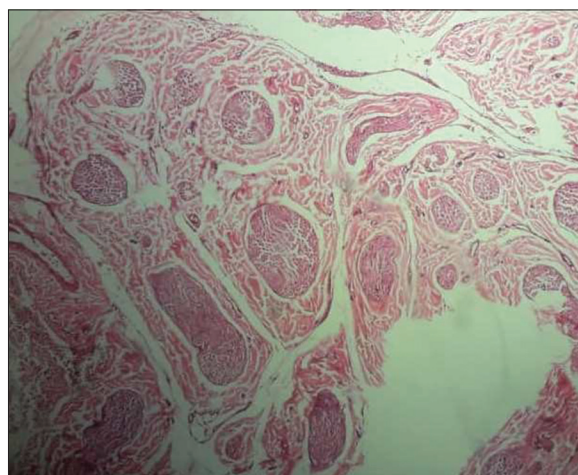


Figure 1: Normal nerve cross-section in the control group with no damage to the nerve (H and E, $\times 40$).

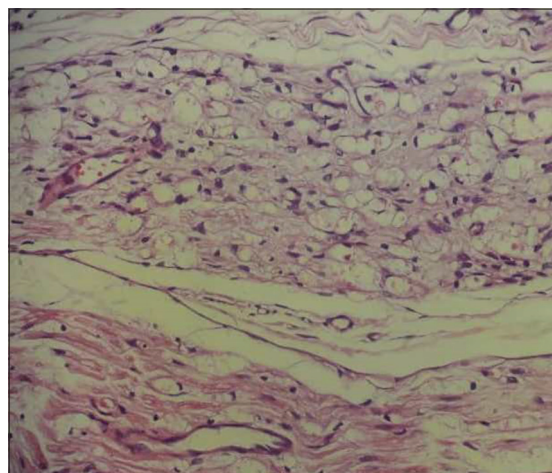


Figure 2: Mild degeneration of the nerve (H and E, $\times 400$).

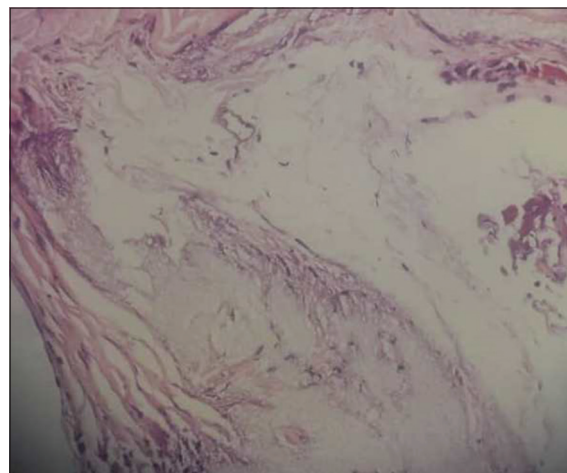


Figure 3: Moderate degeneration of the nerve (H and E, $\times 100$).

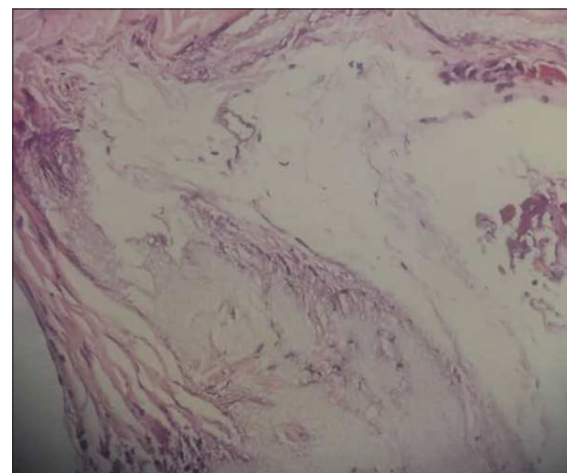


Figure 4: Severe degeneration of the nerve (H and E, $\times 100$).

the frequency percentage of severe degeneration. The Chi-square test showed that the severity of degeneration after nerve injury was significantly different among the five groups ($P < 0.001$). Intraneural infiltration was more commonly absent in methyl prednisolone and exenatide groups compared with the ozone group. The Chi-square test showed a significant difference in this respect among the five groups ($P < 0.001$). The muscular injury was more commonly absent in the methyl prednisolone group and the Chi-square test showed a significant difference in this respect among the five groups ($P < 0.001$). Fibrosis was more commonly absent in exenatide and methyl prednisolone groups and the difference

in this respect was significant among the five groups. Perineural granulation tissue in methyl prednisolone and exenatide groups was more frequently absent compared with the ozone group. The Chi-square test showed a significant difference in this respect among the five groups. Perineural vascular proliferation in methyl prednisolone and exenatide groups was more commonly absent compared with the ozone group. The difference in this respect was also significant among the five groups ($P < 0.001$). Perineural infiltration of inflammatory cells in methyl prednisolone and exenatide groups was more commonly absent compared with the ozone group. The difference in this respect was significant among the five groups.

Considering the significant differences among the five groups in all the studied variables, pairwise comparisons were carried out. The results are presented in Table 2.

Regarding the frequency of recovery of the sensory function of infraorbital nerve, significant differences were noted between the control group and all other groups ($P < 0.001$), and saline group and all other groups ($P < 0.001$). The difference in this regard was not significant between the methyl prednisolone and exenatide groups ($P = 0.805$). However, this difference was significant between methyl prednisolone and ozone ($P < 0.001$), and also between exenatide and ozone ($P < 0.001$) groups and ozone showed significantly superior efficacy compared with both methyl prednisolone and exenatide. Figure 7 shows

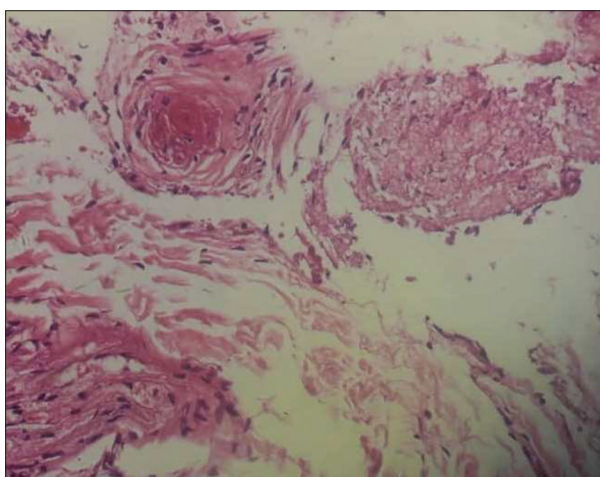


Figure 5: Fibrosis and inflammation around the nerve (H and E, $\times 400$).

Table 1: Frequency distribution of different histological parameters in the five groups

Variable	Category	Group (%)					P
		Control	Saline (dose)	Methyl prednisolone (dose)	Exenatide (dose)	Ozone (dose)	
Peripheral inflammation	Absence	14 (100)	2 (14.3)	10 (83.3)	11 (78.6)	2 (14.3)	0.001
	Presence	0 (0)	12 (85.7)	2 (16.7)	3 (21.4)	12 (86.7)	
Degeneration	No degeneration	14 (100)	0 (0)	0 (0)	3 (21.4)	0 (0)	0.001
	Mild degeneration	0 (0)	5 (37.5)	10 (83.3)	10 (71.4)	13 (92.2)	
	Severe degeneration	0 (0)	9 (64.3)	2 (16.7)	1 (7.1)	1 (7.1)	
Intraneural inflammatory infiltration	Absence	14 (100)	14 (100)	12 (100)	14 (100)	3 (21.4)	0.001
	Presence	0 (0)	0 (0)	0 (0)	0 (0)	11 (78.6)	
Muscle injury	Absence	14 (100)	13 (92.2)	12 (100)	13 (92.2)	2 (14.3)	0.001
	Presence	0 (0)	1 (7.1)	0 (0)	1 (7.1)	12 (85.7)	
Perineural fibrosis	Absence	14 (100)	14 (100)	12 (100)	14 (100)	13 (92.9)	0.001
	Presence	0 (0)	0 (0)	0 (0)	0 (0)	1 (7.1)	
Granulation tissue around the nerve	Absence	14 (100)	7 (50)	12 (100)	14 (100)	5 (35.7)	0.001
	Presence	0 (0)	7 (50)	0 (0)	0 (0)	9 (64.3)	
Perineural vascularization	Absence	14 (100)	7 (50)	12 (100)	14 (100)	5 (35.7)	0.001
	Presence	0 (0)	7 (50)	0 (0)	0 (0)	9 (64.3)	
Perineural inflammatory infiltration	Absence	14 (100)	7 (50)	12 (100)	14 (100)	5 (35.7)	0.001
	Presence	0 (0)	7 (50)	0 (0)	0 (0)	9 (64.3)	

the overall improvement of the sensory function of the infraorbital nerve after injury in the five groups.

DISCUSSION

Clinical evidence shows that after trauma, nerve fibers can be surgically repaired successfully only if

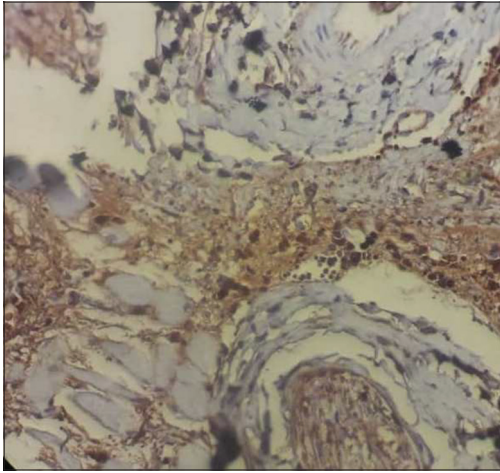


Figure 6: Confirming nerve degeneration by detection of macrophages at the site using CD68 marker (CD68, ×400).

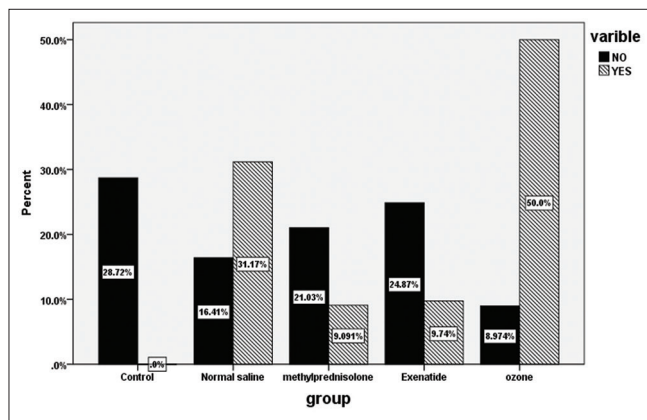


Figure 7: Overall improvement of the sensory function of infraorbital nerve after injury in the five groups.

the surgical procedure is performed immediately after trauma. Thus, a thorough understanding of different types of nerve fibers is important for the surgeon to recognize the type of trauma and estimate its prognosis and select the right surgical treatment plan for the patient.^[14]

Nerve fiber injury can be categorized into three groups of neuropraxia, axonotmesis, and neurotmesis. Although accurate diagnosis of these three categories depends on the type of nerve injury, knowledge about the pathophysiology of each type of injury is imperative to estimate the success of treatment.^[15]

In recent years, many attempts have been made for nerve regeneration after trauma.^[16] Although small injuries of the nerves may heal spontaneously, severe injuries have a slower pace of recovery and may even cause lifetime disability.^[17] Since the early fixation of zygomatic complex fractures does not cause nerve recovery, other modalities must be used to enhance the recovery of the nerve function. Previous studies used antioxidative agents and corticosteroids to improve neuronal regeneration. Considering the limited number of studies on the efficacy of ozone, methyl prednisolone and exenatide for infraorbital nerve regeneration, this study aimed to assess the effect of these medications on the recovery of infraorbital nerve paresthesia after injury. The results showed that no inflammation in the peripheral tissue had a significantly higher frequency in methyl prednisolone group. Degeneration, intracellular inflammatory infiltrate, muscle injury, fibrosis around the nerve, granulation tissue, vascular proliferation, and infiltration of inflammatory cells around the nerve were more commonly absent in the exenatide group.

Ozbay *et al.*^[18] assessed the effect of ozone therapy on the regeneration of facial nerve and stated that the group treated with ozone had a lower stimulation

Table 2: Pairwise comparisons of the groups regarding the studied variables

Variable Study groups	Histopathological findings							
	Peripheral tissue inflammation	Degeneration	Intraneural inflammatory infiltration	Muscle injury	Perineural fibrosis	Perineural granulation tissue	Perineural vascular proliferation	Perineural infiltration of inflammatory cells
Control	0 (0.0) ^{a,d}	0 (0.0) ^{a,b,c,d}	0 (0.0) ^d	0 (0.0) ^d	0 (0.0)	0 (0.0) ^{a,d}	0 (0.0) ^{a,d}	0 (0.0) ^{a,d}
Saline	12 (85.7) ^{e,f}	14 (100)	0 (0.0) ^g	1 (7.1) ^g	0 (0.0)	7 (50) ^{e,f}	7 (50) ^{e,f}	7 (50) ^{e,f}
Methyl prednisolone	2 (16.7) ^j	12 (100)	0 (0.0) ^j	0 (0.0) ^j	0 (0.0)	0 (0.0) ^j	0 (0.0) ^j	0 (0.0) ^j
Exenatide	3 (21.4) ^j	11 (78.6)	0 (0.0) ^j	1 (7.1) ^j	0 (0.0)	0 (0.0) ^j	0 (0.0) ^j	0 (0.0) ^j
Ozone	12 (85.7)	14 (100)	11 (78.6)	12 (85.7)	1 (7.1)	9 (64.3)	9 (64.3)	9 (64.3)

^a(*P*<0.05) control versus normal saline; ^b(*P*<0.05) control versus methylprednisolone is; ^c(*P*<0.05) control versus exenatide; ^d(*P*<0.05) control versus ozone; ^e(*P*<0.05) normal saline versus methylprednisolone; ^f(*P*<0.05) normal saline versus exenatide; ^g(*P*<0.05) normal saline versus ozone; ^h(*P*<0.05) methylprednisolone versus exenatide; ⁱ(*P*<0.05) methylprednisolone versus ozone; ^j(*P*<0.05) exenatide versus ozone

threshold than the saline group. In addition, superior improvement of function was noted in the ozone group. A significant difference was noted between the two groups in the degeneration of axon and myelin ultrastructure.^[18] This finding was similar to the current results. However, we compared ozone with methyl prednisolone and exenatide, and therefore, the study was more comprehensive than theirs. Kuyucu *et al.*^[4] assessed the efficacy of exenatide for injured sciatic nerve regeneration in rats. They stated that the motor and electrophysiological function of the nerve in exenatide group improved after 12 weeks. Histological studies revealed significant differences in the number of axons following treatment with exenatide.^[4] Their results were in line with ours and confirmed the role of exenatide in the improvement of nerve function. They assessed nerve recovery in functional and electrophysiological aspects while histological parameters were evaluated in our study.

Our study and that of Ozbay *et al.*^[18] and Kuyucu *et al.*^[4] were all conducted on laboratory animals, and different nerves of rats were investigated. However, Haapanen *et al.*^[1] evaluated the efficacy of dexamethasone for restoring the neurosensory function of nerve after zygomatic fracture in humans. They revealed that short-term use of high-dose dexamethasone had no positive efficacy to restore the neurosensory function of the nerve in patients after zygomatic complex fracture. Similarly, in our study, methyl prednisolone did not enhance the recovery of nerve function. Thus, it seems that corticosteroids, irrespective of their type, have no positive effect on the function of neurons. However, Ozturk *et al.*^[6] assessed the efficacy of ozone and methyl prednisolone for the recovery of compressed sciatic nerve of rats and stated that the combination of methyl prednisolone and ozone had positive effects on nerve regeneration after compression. Our results cannot be accurately compared with theirs since no group in our study received a combination of ozone and methyl prednisolone. Considering the presence of some reports regarding the positive effects of methyl prednisolone and the existing controversy in this respect, future systematic reviews and meta-analyses are required to assess the efficacy of methyl prednisolone alone and in combination with other medications for this purpose. Lieberman *et al.*^[19] assessed the effect of corticosteroids on injured facial nerve of mice. Their results regarding decelerated nerve recovery and impaired survival of neurons were

in contrast to our findings. Yamamoto *et al.*^[20] assessed the effect of exendin-4 on nerve regeneration after compression. All changes, except for atrophy of the anterior tibialis muscle, significantly improved by the use of exendin-4. The electrophysiological, morphological, and functional parameters showed a significant improvement after 4 weeks. These results revealed that exendin-4 is effective for clinical application in the treatment of peripheral nerve injuries.^[20] Their results were in agreement with ours.

Future animal studies with larger sample size and subsequent clinical trials are required to reach a final judgment regarding the efficacy of these medications for nerve recovery.

CONCLUSION

Within the limitations of this study, the results indicated that exenatide had a superior efficacy for the improvement of nerve function after injury. Thus, it seems that it can be used as a part of postoperative care in infraorbital nerve injury following zygomatic complex fracture. However, further studies, particularly clinical trials, are required to confirm the current results.

Financial support and sponsorship

Nil.

Conflicts of interest

The authors of this manuscript declare that they have no conflicts of interest, real or perceived, financial or non-financial in this article.

REFERENCES

1. Haapanen A, Thorén H, Apajalahti S, Suominen AL, Snäll J. Does dexamethasone facilitate neurosensory function regeneration after zygomatic fracture? A randomized controlled trial. *J Oral Maxillofac Surg* 2017;75:2607-12.
2. Al-Bishri A, Forsgren S, Al-Thobaiti Y, Sunzel B, Rosenquist J. Effect of betamethasone on the degree of macrophage recruitment and nerve growth factor receptor p75 immunoreaction during recovery of the sciatic nerve after injury: An experimental study in rats. *Br J Oral Maxillofac Surg* 2008;46:455-9.
3. Hupp JR, Tucker MR. *Contemporary Oral and Maxillofacial Surgery*. 6th ed. St. Louis: Elsevier; 2014.
4. Kuyucu E, Gümüş B, Erbas O, Oltulu F, Bora A. Exenatide promotes regeneration of injured rat sciatic nerve. *Neural Regen Res* 2017;12:637-43.
5. Yüce S, Cemal Gökçe E, Işkdemir A, Koç ER, Cemil DB, Gökçe A, *et al.* An experimental comparison of the effects of propolis, curcumin, and methylprednisolone on crush injuries of the sciatic nerve. *Ann Plast Surg* 2015;74:684-92.

6. Ozturk O, Tezcan AH, Adali Y, Yıldırım CH, Aksoy O, Yagmurdur H, *et al.* Effect of ozone and methylprednisolone treatment following crush type sciatic nerve injury. *Acta Cir Bras* 2016;31:730-5.
7. Göke R, Fehmann HC, Linn T, Schmidt H, Krause M, Eng J, *et al.* Exendin-4 is a high potency agonist and truncated exendin-(9-39)-amide an antagonist at the glucagon-like peptide 1-(7-36)-amide receptor of insulin-secreting beta-cells. *J Biol Chem* 1993;268:19650-5.
8. Buse JB, Henry RR, Han J, Kim DD, Fineman MS, Baron AD, *et al.* Effects of exenatide (exendin-4) on glycemic control over 30 weeks in sulfonylurea-treated patients with type 2 diabetes. *Diabetes Care* 2004;27:2628-35.
9. Chen S, Liu AR, An FM, Yao WB, Gao XD. Amelioration of neurodegenerative changes in cellular and rat models of diabetes-related Alzheimer's disease by exendin-4. *Age (Dordr)* 2012;34:1211-24.
10. Liu WJ, Jin HY, Lee KA, Xie SH, Baek HS, Park TS. Neuroprotective effect of the glucagon-like peptide-1 receptor agonist, synthetic exendin-4, in streptozotocin-induced diabetic rats. *Br J Pharmacol* 2011;164:1410-20.
11. Perry T, Holloway HW, Weerasuriya A, Mouton PR, Duffy K, Mattison JA, *et al.* Evidence of GLP-1-mediated neuroprotection in an animal model of pyridoxine-induced peripheral sensory neuropathy. *Exp Neurol* 2007;203:293-301.
12. Sereffican M, Yurttas V, Ozyalvacli G, Terzi EH, Turkoglu SA, Yildiz S, *et al.* The histopathological and electrophysiological effects of thymoquinone and methylprednisolone in a rabbit traumatic facial nerve paralysis model. *Am J Otolaryngol* 2016;37:407-15.
13. Clark JD, Gebhart GF, Gonder JC, Keeling ME, Kohn DF. Special report: The 1996 guide for the care and use of laboratory animals. *ILAR J* 1997;38:41-8.
14. Fonseca RJ. *Oral and Maxillofacial Surgery*. 3rd ed. St. Louis, Missouri: Elsevier; 2018.
15. Eser F, Aktekin LA, Bodur H, Atan C. Etiological factors of traumatic peripheral nerve injuries. *Neurol India* 2009;57:434-7.
16. Marquez Neto OR, Freitas T, Mendelovitz P, Schetchtman N, Kessler I. An initial clinical experience to improve postoperative monitoring of peripheral nerve regeneration following neurotmesis using magnetic resonance imaging at 1.5 Tesla. *J Neurosurg Sci* 2016;60:329-38.
17. Asplund M, Nilsson M, Jacobsson A, von Holst H. Incidence of traumatic peripheral nerve injuries and amputations in Sweden between 1998 and 2006. *Neuroepidemiology* 2009;32:217-28.
18. Ozbay I, Ital I, Kucur C, Akcılar R, Deger A, Aktas S, *et al.* Effects of ozone therapy on facial nerve regeneration. *Braz J Otorhinolaryngol* 2017;83:168-75.
19. Lieberman DM, Jan TA, Ahmad SO, Most SP. Effects of corticosteroids on functional recovery and neuron survival after facial nerve injury in mice. *Arch Facial Plast Surg* 2011;13:117-24.
20. Yamamoto K, Amako M, Yamamoto Y, Tsuchihara T, Nukada H, Yoshihara Y, *et al.* Therapeutic effect of exendin-4, a long-acting analogue of glucagon-like peptide-1 receptor agonist, on nerve regeneration after the crush nerve injury. *Biomed Res Int* 2013;2013:315848.