

Case Report

Retreatment of an orthognathic camouflaged case by total lower arch mesialization using temporary anchorage device

Siamak Hemmatpour¹, Golnaz Nahvi², Mehdi Oonchi³

¹Department of Orthodontics, School of Dentistry, Islamic Azad University, ²Department of Orthodontics, School of Dentistry, Shahid Beheshti University of Medical Sciences, Tehran, Iran, ³Faculty of Dentistry, University of British Columbia, Vancouver, Canada

ABSTRACT

Mandibular tooth extractions for camouflage treatments in borderline Class III patients may end up with displeasing esthetic results which may lead the patient seeking further complicated retreatments. In this case report, we presented a patient's retreatment with a combined orthodontic and orthognathic surgery treatment plan. The treatment strategy involved an innovative temporary anchorage device (TAD)-based method for total mandibular arch mesialization instead of space reopening for first lower premolar replacement with implants. In the current case report, orthognathic management of a Class III adult female is discussed. The patient had a history of an esthetically unsuccessful previous camouflaged orthodontic treatment with two lower premolar extractions. She was prepared for orthognathic surgery using an innovative custom-made sliding jig based on miniscrews for total mandibular arch mesialization with the aim of dental arch decompensation. After gaining the optimal dental arch discrepancy, the patient had orthognathic surgery (maxillary advancement and mandibular setback and advancement genioplasty). Total mandibular dental arch mesialization with the aim of dental arch discrepancy preparation was successfully conducted using TADs. By means of the innovative miniscrew-anchored sliding jig, the patient's satisfactory esthetic and occlusal results were obtained in 22 months. With innovative application of the miniscrews, more practical and reasonable alternatives are available to replace conventional and complicated treatment plans such as space reopening for implants in patients with unsuccessful previous orthodontic therapies.

Key Words: Anchorage, orthodontics, orthognathic, retreatment

Received: 12-Jul-2020
Revised: 19-Jan-2021
Accepted: 17-Mar-2021
Published: 25-Sep-2021

Address for correspondence:
Dr. Golnaz Nahvi,
Department of
Orthodontics, School of
Dentistry, Shahid Beheshti
University of Medical
Sciences, Tehran, Iran.
E-mail: golnaznahvi@gmail.
com

INTRODUCTION

Nowadays, with the patients' increasing demand for esthetic treatments, esthetic considerations surpass ideal occlusion in treatment planning. Therefore, some treatment alternatives such as camouflage treatments, especially in Class III patients, do not always satisfy patients seeking ideal facial and smile esthetics although acceptable occlusion has been accomplished.

Most of the time retreatment of a Class III camouflaged case is demanding, especially when the previous camouflage treatment plan has involved tooth extractions. Moreover, it may also complicate the feasibility of future orthognathic surgery, especially if extractions are carried out in the lower arch to compensate the negative overjet.^[1]

This is an open access journal, and articles are distributed under the terms of the Creative Commons Attribution-NonCommercial-ShareAlike 4.0 License, which allows others to remix, tweak, and build upon the work non-commercially, as long as appropriate credit is given and the new creations are licensed under the identical terms.

For reprints contact: WKHLRPMedknow_reprints@wolterskluwer.com

How to cite this article: Hemmatpour S, Nahvi G, Oonchi M. Retreatment of an orthognathic camouflaged case by total lower arch mesialization using temporary anchorage device. Dent Res J 2021;18:78.

| Access this article online | |
|---|--|
|  | <p>Website: www.drj.ir www.drjjournal.net www.ncbi.nlm.nih.gov/pmc/journals/1480</p> |

With the entrance of temporary anchorage devices (TADs) and their versatility into the field of orthodontics, clinicians have more treatment alternatives which better match treatment esthetic and occlusal goals.^[2] Thus, orthodontic treatment planning trend is changing from suboptimal esthetic to more optimal options. Furthermore, the expert clinicians are enabled to compensate previous malpractice by thoughtfully utilizing TADs.

In this case report, we presented retreatment of a Class III young adult female dissatisfied with the esthetic results of her previous camouflaged orthodontic therapy. Instead of space reopening for implant insertion in the lower first premolar extraction sites or other complicated alternatives, we decided to use an innovative method using TADs for total mandibular arch mesialization to prepare the patient for orthodontic and the following orthognathic surgery.

Therefore, a special handmade TAD-based jig specifically designed for total lower dental arch mesialization, not previously reported in the literature, is introduced and implemented in the current case report.

CASE REPORT

Diagnosis

A borderline Class III adult female at the age of 26 was referred dissatisfied with her previous camouflaged orthodontic treatment and seeking for a retreatment with more esthetic results. In her previous treatment, an orthodontic camouflaged therapy involving the extraction of two mandibular first premolars was attempted. The patient complained of unesthetic middle and lower facial thirds in the frontal and profile view because of maxillary retrognathism, mandibular prognathism, and reduced chin prominence. Furthermore, she was dissatisfied with her smile due to the unlevelled upper centrals and anterior crossbite in the right lateral incisor area. Furthermore, she complained of lingoversion inclination of the lower incisors caused by previous lower first premolar extraction and subsequent overretraction of the lower incisors.

Pretreatment face photographs showed a straight facial profile and normal vertical facial heights. The mandible was mildly prognathic, but the chin prominence was reduced. The smile arc was nonconsonant, and she revealed no gingival show

at smile. The mandibular dental midline was 1 mm off to the right related to the upper dental arch and facial midline due to the same amount of mandibular skeletal deviation to the right side.

In intraoral examination, the patient revealed Class III molar and Class I canine relationships in both right and left sides. She had anterior crossbite in the area of the left upper lateral incisor and lower lateral incisor and canine and also posterior crossbite in the upper second and lower third molars region. The patient had reduced overjet and overbite in both sides, especially in the right side, with no anterior guidance and protective occlusion. Excessive root prominence was evident in the buccal side of the lower anterior sextant of the alveolar region caused by overretraction of the anterior tooth and anterior tooth torque control loss during retraction. The initial lateral cephalometric analysis showed a skeletal Class III relationship due to the maxillary retrognathism and mandibular prognathism. Retroclination of the lower incisors was evident [Table 1]. Oral hygiene was adequate. The patient did not have pain in the temporomandibular joint. Initial panoramic radiograph demonstrated symmetric condylar shape and position bilaterally, and there was no evidence of bone or dental pathology [Figures 1-4].

Treatment objectives

The treatment goals were aimed at the improvement of the patient's esthetics, correction of the lower dental and skeletal midline deviation, correction of the nonconsonant smile arc, achieving normal overbite

Table 1: Pretreatment values of cephalometric analysis

| Cephalometric variable | Pretreatment (°) |
|------------------------|------------------|
| U1-SN | 102 |
| L1-MeGo | 75 |
| U1 to N-Pog | +3 |
| L1 to N-Pog | +1 |
| Interincisal A. | 144 |
| U1-Palatal P. | 118 |
| S-Go: N-Mex100 | 63 |
| Pal-Go-Me (Basal A) | 27 |
| SN-MeGo | 37 |
| SNA | 82 |
| SNB | 83 |
| ANB | -1 |
| SN-Pog | 84 |
| Wits | -5 |
| Upper lip to E_line | -8 |
| Lower lip to E_line | -4 |
| Nasolabial angle | 91 |

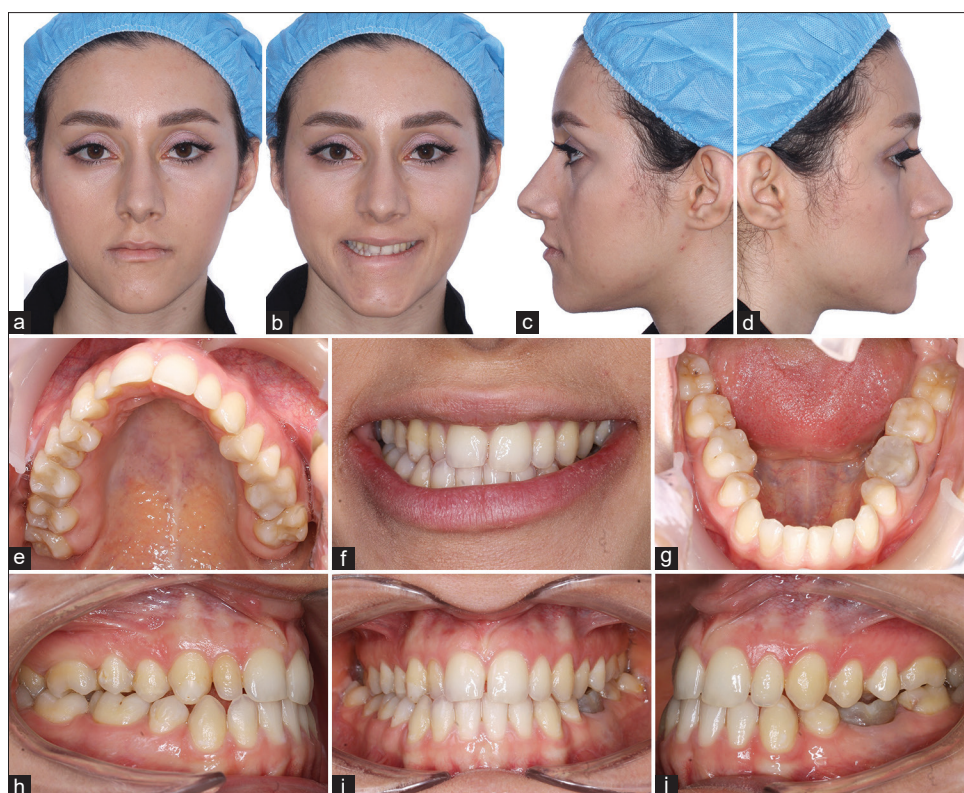


Figure 1: Initial images of the patient: Extraoral views: Frontal at rest (a), frontal at smile (b), left profile (c), right profile (d) intraoral views: Upper (e), smile close-up (f), lower (g), right (h), frontal (i), left (j).

and overjet, achieving an optimal anterior and canine guidance, crossbite correction in the anterior and posterior area, and maxillary retrognathism and mandibular prognathism and deviation and also chin nonprominence orthognathic correction.

Treatment alternatives

Due to the patient's main chief complaint which was esthetic, the only reasonable treatment alternative was orthognathic surgery to address this consideration.

Considering the history of the lower first premolar extraction, no anteroposterior discrepancy was available for orthognathic arch bases of movements. Therefore, four alternatives were ahead:

The first option was to reopen space for implant insertion in the area of the two first extracted premolars. This was discluded due to the complex and time-consuming phase of the adequate space regaining in the crowns and interradicular areas and also to eliminate the invasive phase of implant insertion and subsequent prosthesis preparation phase.

The second alternative was to create upper and lower dental arch discrepancy by two-stage mesialization of the whole lower dental arch. This option was also rejected because of the complexity and time-consuming

of the two phases needed: first stabilizing the posterior segment with miniscrews and using open coils to mesialize the anterior segment, and then, stabilizing the mesialized anterior segment by TADs and protracting the posterior dentition by closed coils. One of the drawbacks of the two-stage approach is the requirement for several times miniscrew relocation.

Furthermore, the newly remodeled bone in the area of the mesialized teeth is not suitable for miniscrew insertion in terms of stability. The newly remodeled bone is not compact enough to withstand heavy forces exerted on miniscrews for posterior segment mesialization, and the miniscrew inserted immediately in the freshly remodeled region is very susceptible to failure. Moreover, the miniscrews inserted in the interradicular area in this approach have interference with mesialization segment pathway.

The third option which was adopted for this case was en masse one-phase mesialization of the lower dentition and preparation of the patient for orthognathic surgery (maxillary advancement + mandibular setback and advancement genioplasty). For this option, we designed a special innovative handmade jig based on TADs inserted in the mandibular buccal shelf area.

The last treatment option was to extract two premolars from the upper arch and retract the anterior dentition into the residual space to create the required anteroposterior arch base discrepancy. This option was ruled out because it was time-consuming and the upper incisor relationship with regard to the upper skeletal base was normal. Therefore, the incisor inclination was acceptable, and we did not want to retrocline the upper incisors following premolar space closure phase.

Treatment progress

Before initiation of the orthodontic treatment, all dental caries were removed and restored. The patient was also referred to an endodontist to confirm the health of the existing root canal treatments on the upper right and lower left first molar teeth. The patient was referred to an oral and maxillofacial surgeon to confirm the orthognathic treatment plan and also for the potential need to extract third molars in order not to interfere with future surgical cuts. Due to the previous extraction of the lower first premolars and subsequent lower third molar mesialization, the need for third molar extraction was ruled out by the surgeon.

Fixed orthodontic treatment was initiated by placement of preadjusted MBT brackets with 0.022" slot (Master Series, American Orthodontics Ltd., Sheboygan, WI, USA) on the mandibular dental arch, crystal ceramic in the anterior and metallic brackets in the posterior teeth. Arch alignment with 0.014" superelastic nickel–titanium (NiTi) (austenitic active, preformed ovoid, superelastic archwire; 3M Unitek Corporation) wire was carried out. The leveling and aligning were done with 0.014, 0.016, 0.018, and 19 × 25 NiTi wires and followed by 19 × 25 stainless steel wire as the working archwire.

Two miniscrews (1.6 mm × 8 mm, JB, Dual Top Anchor System; Jeil Medical, Seoul, Korea) were placed on the right and left side in the distobuccal area of the buccal shelf. Before miniscrew insertion, CBCB image from the lower arch was administrated in order to confirm the most suitable place for TAD insertion and avoid any probable root intimacy [Figure 5].

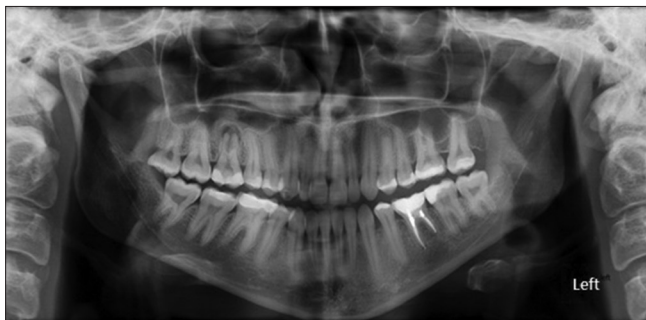


Figure 2: Initial panoramic view.

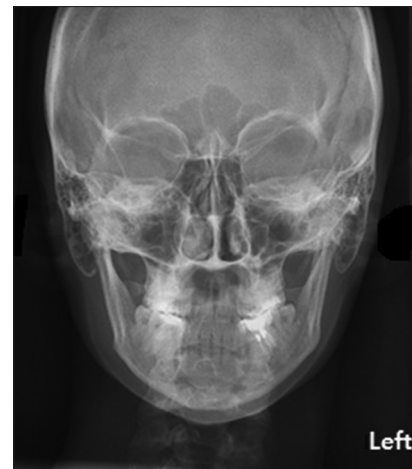

Figure 4: Initial posteroanterior cephalogram.

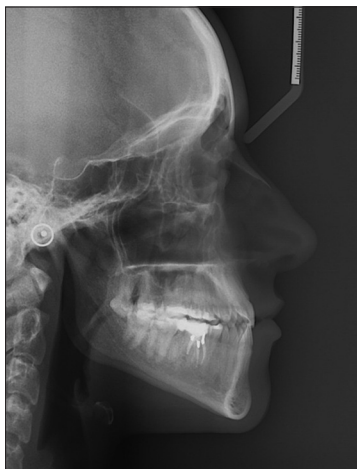

Figure 3: Initial lateral cephalogram.

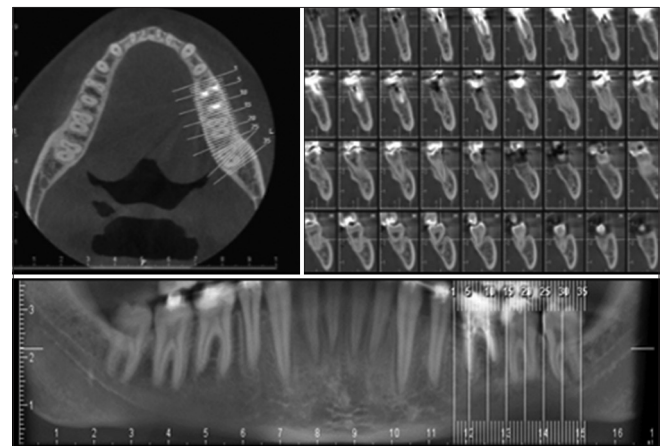


Figure 5: Cone-beam computed tomography images to determine the appropriate place for miniscrew insertion.

An innovative handmade jig was designed using a heavy (19 × 25”) stainless steel wire. The jig was attached to the miniscrews posteriorly and to the archwire anteriorly in the area between the second premolar and first molar, close to the second premolar bracket in order not to interfere with mesializing segment pathway. A stabilizing loop was considered in the jig design and bent upward and hooked on the archwire in the area between the second premolar and the first molar to inhibit upward and downward movement of the sliding jig.

Using a crimpable hook-shaped lever arm (19 × 25 stainless) crimped on the wire distal to the lower right second molar, total arch mesialization commenced first by closed elastomeric chain (Ortho Technology, USA), and then heavier forces by a 10-mm Sentalloy closed coil spring (Dentsply GAC Int., Bohemia, NY, USA) from lever arch to the jig hook. The miniscrew served as the anchorage for posterior segment mesialization by pulling force of the elastomeric chain and coil spring [Figures 6 and 7].

Because of the mesialization force exerted from the buccal side, the working archwire was frequently adjusted and constricted at the end side to neutralize the buccoversion side effect of the mesializing posterior segment. After 6 months, the upper arch was bonded and the alignment and leveling phases were conducted the same as the lower arch. Dental arch preparation was accomplished in 14 months [Figures 8 and 9].

Afterward, the patient had orthognathic surgical operation and 6 months postsurgical orthodontic treatment and elastic therapy to establish the final occlusion [Figures 10-12 and Table 2].

In retention phase, bonded lingual retainer was used for six lower anterior teeth and a Hawley removable plate was used as the retainer for the maxilla. The total duration of treatment was 22 months.

DISCUSSION

In this case report, a young adult Class III female patient unpleased with her previous camouflaged orthodontic treatment esthetic results was retreated using an innovative miniscrew-based jig. This novel total arch mesialization approach for surgical preparation yielded successful esthetic and occlusal results.

Entrance of TADs into the field of dentistry has opened new doors to treatment plan alternatives in this

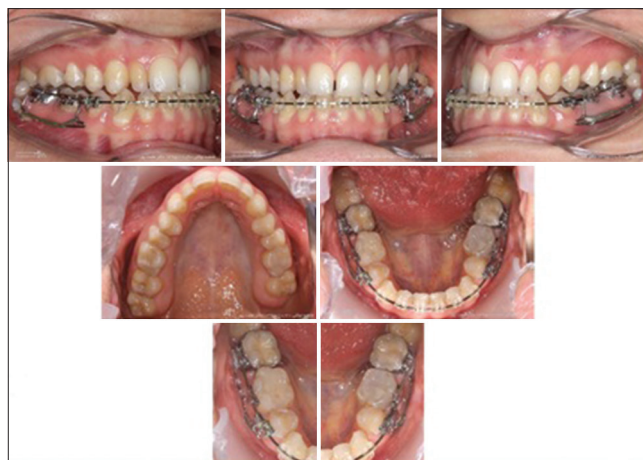

Figure 6: Intraoral views of the custom-made jig inserted for lower arch total mesialization.

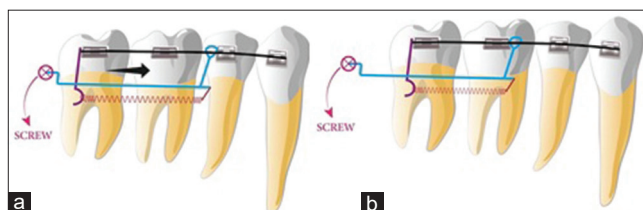


Figure 7: Schematic view of the custom-made jig for total mandibular arch mesialization. Before initiation of mesialization (a), after mesialization (b).

era.^[3-5] One of the most important decisions to ensure predictable results when using TADs is the insertion site. In this case report, buccal shelf at the level of the second molar distobuccal cusp was selected for miniscrew insertion for total arch mesialization. This site is not reported to be used for the purpose of total dental arch mesialization, although it is a routine area for distalization by TADs.^[6]

A recent study based on cone-beam computed tomography evaluated mandibular buccal shelf as a choice for miniscrew insertion. The authors concluded that the mandibular buccal shelf at the height of the second molar distobuccal cusp is the most appropriate site for miniscrew insertion in terms of different variables such as cortical bone thickness, bone width, insertion depth, and proximity to the nerve.^[7] Furthermore, the result of a study concluded that buccal shelf provides adequate bone and suitable bone quality for miniscrew insertion.^[8] These results are in line with our thought behind the miniscrew insertion site in the buccal shelf of the lower arch. The compact bone in the buccal shelf area provides adequate bone quality and quantity for miniscrew stability to withstand heavy forces for total mandibular dental arch mesialization movement.

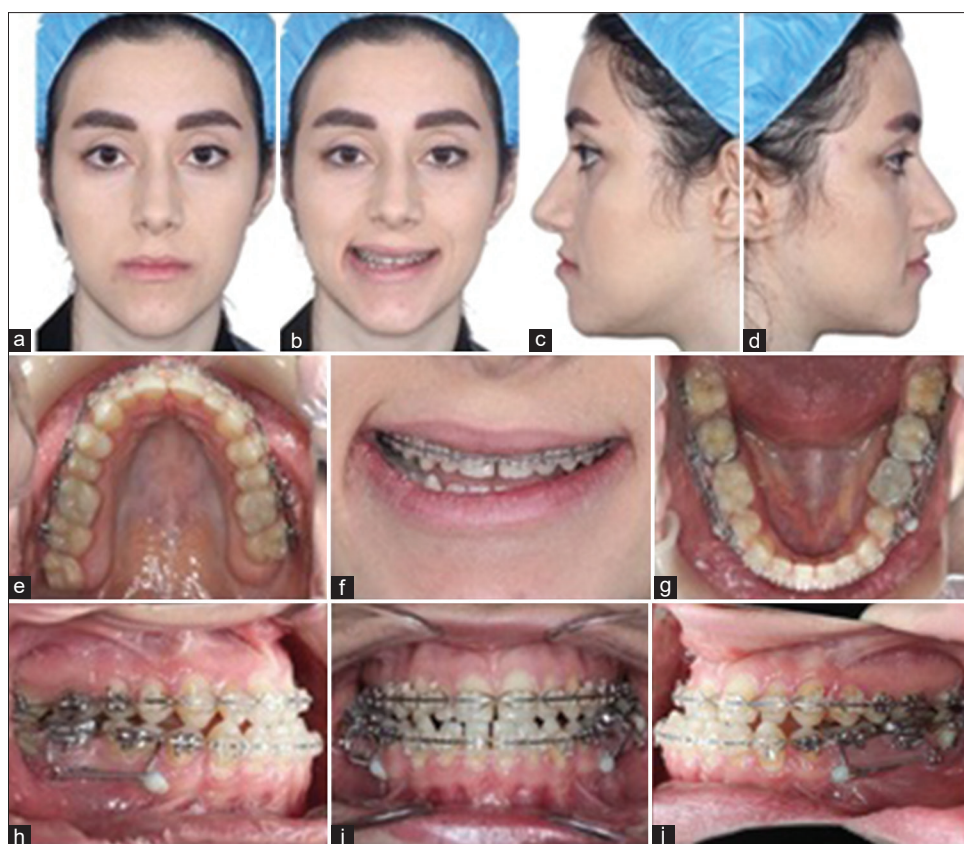

Figure 8: Images of the patient at the end of the presurgical orthodontic phase: Extraoral views: Frontal at rest (a), frontal at smile (b), left profile (c), right profile (d) intraoral views: Upper (e), smile close-up (f), lower (g), right (h), frontal (i), left (j).

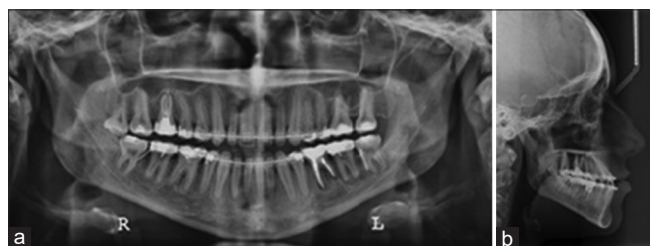

Figure 9: At the end of the presurgical orthodontic phase. Panoramic view (a), lateral cephalogram (b).

Another advantage of the buccal shelf for the purpose of total mandibular arch mesialization is to eliminate the interference with the tooth mesialization pathway. Furthermore, there is no need for miniscrew repositioning in the interradicular area with looser newly remodeled bone which makes the miniscrews more susceptible to failure.

Some researches claimed that buccal shelf as the mini-implant insertion site has a high failure rate. They declared that miniplates placed in the extra-alveolar regions such as mandibular symphysis and zygoma (malar bone) reveal lower failure rates rather than mini-implants placed in areas such as

buccal shelf.^[9] This is in contrast with our study results which showed no failure in mini-implant inserted in the mandibular buccal shelf for total mandibular dentition mesialization. In the current case, the whole mandibular dentition mesialization was conducted by only two miniscrews, one miniscrew inserted in each side of the mandibular buccal shelf.

There are a plenty of studies reporting successful dental arch distalization in both the upper and lower arches.^[6,10] Furthermore, there are studies with the mesialization of maxillary dentition using benefit system.^[11] However, no study was found in the literature regarding total dental arch mesialization in the mandible using TADs, so this case report approach is innovative with this regard.

The novel approach applied for en masse mandibular dentition mesialization in this case report revealed several advantages:

The whole mandibular dental arch was mesialized by only two miniscrews. The miniscrews were easily placed by the orthodontist himself, not by a surgeon. The miniscrew insertion is less invasive than miniplate, and there is no need for miniplate relevant

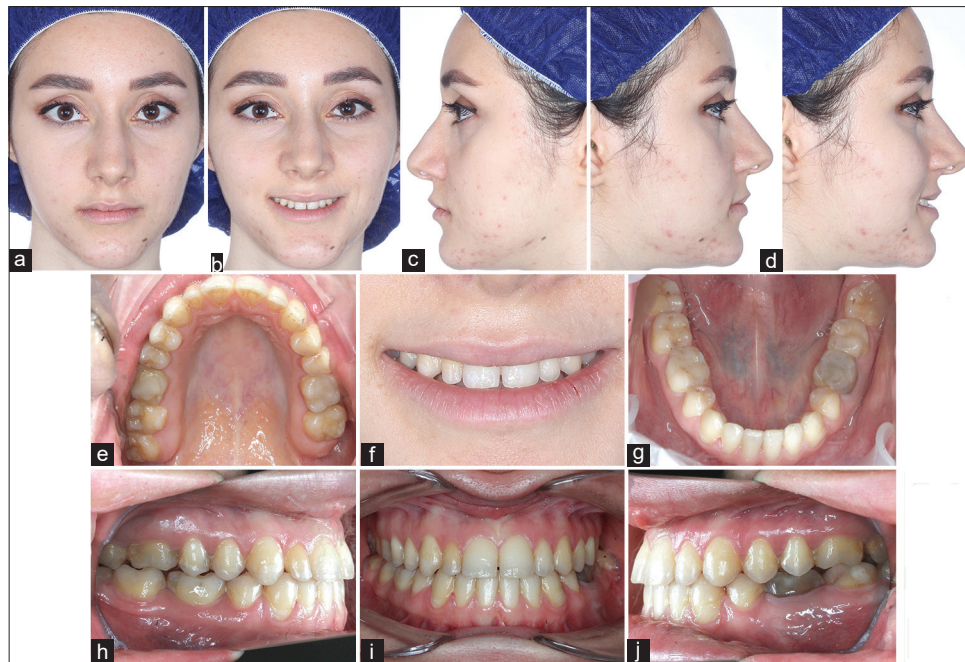


Figure 10: Final images of the patient: Extraoral views: frontal at rest (a), frontal at smile (b), left profile (c), right profile (d) intraoral views: upper (e), smile close-up (f), lower (g), right(h), frontal(i), left(j)

considerations regarding surgical flaps and sutures for miniplate insertion and the second surgical session for removal. Furthermore, the cost of the miniscrews is lower than miniplates and the patient's comfort is better in miniscrew rather than miniplate.

The proposed technique in our study has both the simplicity of use of the miniscrews and advantages of the miniplates. Miniplates have been claimed to have the advantage of being away from the dentition, therefore, eliminating root interference and make them the best choice for entire dental arch movements.^[12] Our approach eliminated the need to relocate the miniscrews throughout the mesialization phase. Thanks to the delicately designed jig, the miniscrews had no interferences with mesializing segment pathway.

In this approach, the total dentition mesialization is conducted in one single phase with more simple and predictable results rather than two-phase mesialization approach: first anterior segment mesialization and then miniscrew relocation and posterior protraction.

Furthermore, this is a time-saving approach because the total dental arch mesialization process in this approach is completed in a reasonable time span.

Easy fabrication and precise biomechanical considerations to exert force directly to the moving segment center of rotation in vertical dimension are other benefits of the special jig designed for this

newly introduced technique. Frequent adjustments of the working wire in the transverse (buccolingual) direction are conducted to counteract with the side effects caused by buccally exerted mesializing force.

Camouflage treatment in Class III borderline patients with lower first or second premolar extraction needs to be adopted so carefully because it may come up with irrecoverable side effects. At the end of the treatment, the patient may be dissatisfied with unesthetic dentofacial results though acceptable occlusion has been established.

There are some reports of successful camouflaged treatment of a Class III patient with premolars or even molar extraction protocol^[13] which ended up with acceptable results. Although, these results were less than optimal in terms of occlusal and esthetic outcomes.

Furthermore, there are some reports of total arch distalization using TADs in Class III borderline adult patients with acceptable occlusion but less than ideal, although improved esthetic results.^[14,15] In a study by Chen and Cao, the authors claimed that both miniscrews and miniplates are acceptable alternatives for total mandibular arch distalization in mild Class III patients seeking nonsurgical treatment for Class III malocclusion.^[16] Although these approaches may be useful in some patients who refuse orthognathic treatment alternatives, they may

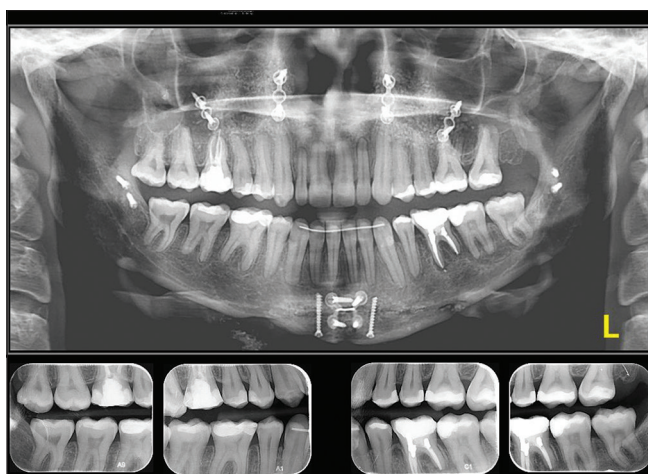

Figure 11: Final panoramic view.

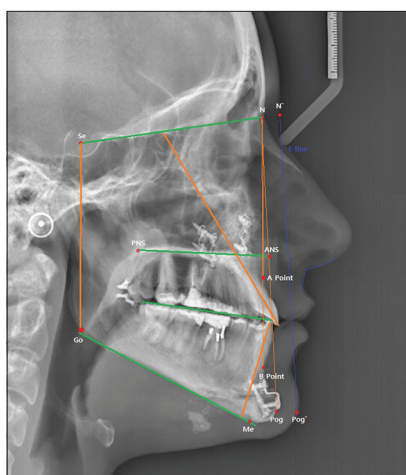


Figure 12: Final lateral cephalogram.

not be a suitable choice for patients seeking ideal dentofacial esthetics. As in the current case report, the patient had undergone a camouflaged orthodontic treatment by premolar extraction and lower dentition distalization which resulted in patient's dissatisfaction with esthetic results which led her to seek for more esthetic treatments. In this case report, we mesialized the total lower dental arch in order to compensate the previous dentition retraction and prepare the patient for orthognathic surgery which entailed the patient's esthetic satisfactions.

Furthermore, another vital consideration in Class III camouflage treatments by premolar extractions is to avoid excessive lingual inclination of the lower incisors during retraction due to the thin buccal plate which is too vulnerable to recession or even perforation. In Class III adult patients, thin alveolar bone in the lower anterior segment needs to be taken into account in treatment planning because it may

Table 2: Posttreatment values of cephalometric analysis

| Cephalometric variable | Posttreatment (°) |
|------------------------|-------------------|
| U1-SN | 107 |
| L1-MeGo | 86 |
| U1 to N-Pog | +2 |
| L1 to N-Pog | -1 |
| Interincisal A | 133 |
| U1-Palatal P | 123 |
| S-Go: N-Mex100 | 59 |
| Pal-Go-Me (Basal A) | 26 |
| SN-MeGo | 36 |
| SNA | 84 |
| SNB | 83 |
| ANB | 1 |
| SN-Pog | 87 |
| Wits | -3 |
| Upper lip to E_line | -7 |
| Lower lip to E_line | -5 |
| Nasolabial angle | 97 |

impose certain limitations on tooth movement.^[17] The results of a recent study demonstrated that moving the mandibular incisors too far forward during preoperative orthodontic treatment could lead to alveolar bone and periodontal support loss around the mandibular incisors.^[18] In the current case report by carefully mesializing the mandibular dentition, no adverse effects occurred on periodontal support and alveolar bone in the mandibular anterior region in final clinical and radiographic evaluations.

Not only esthetics but also establishment of basic occlusal parameters must be taken into consideration in camouflage treatment plans, such as any other orthodontic interventions. One of these vital occlusal considerations is to establish acceptable anterior guidance. This prevents detrimental effects on condyles and ensures a better stability after completion of orthodontic treatment in long term.^[19] In this case report, the patient's previous treatment was ended up with diminished overjet and overbite with no anterior guidance. In the final orthognathic treatment results, the anterior guidance and normal overjet and overbite were established to assure occlusal stability and prevention of any possible condylar detrimental effects and temporomandibular disorders in the future.

CONCLUSION

The novel use of miniscrew-based jig discussed in this case report to maximize anchorage for

total mandibular arch mesialization is an effective, easy-to-use, and cost-benefit approach for cases needing en masse mandibular dentition protraction. This approach is beneficial to decompensate the dental compensations (occurred naturally or iatrogenically by improper previous interventions) in cases needing orthognathic treatments.

Financial support and sponsorship

Nil.

Conflicts of interest

The authors of this manuscript declare that they have no conflicts of interest, real or perceived, financial or nonfinancial in this article.

REFERENCES

- Martino F. Retreatment of a severe skeletal Class III following iatrogenic orthodontic treatment. *EC Dent Sci* 2019;18:1291-301.
- Farret MM. Orthodontic retreatment using anchorage with miniplate to camouflage a Class III skeletal pattern. *Dent Press J Orthod* 2016;21:104-15.
- Aghdashi F, Forouzmehr A, Nahvi G, Tabrizi R, Jafarian M, Majdi S. Assessment of compression and strength of divergent screws mounted on miniplates and dynamic compression plate in fixation of mandibular body fractures: An *in vitro* study. *Br J Oral Maxillofac Surg* 2020;58:e260-4.
- Hemmatpour S, Nahvi G, Oonchi M, Karami S. An Innovative Miniscrew-Based Jig for Unilateral Total Arch Mesialization. *Biointerface Research in Applied Chemistry* 2021;11 (2): 9669-9679
- Hemmatpour S, Oonchi M, Karami S, Nahvi G. Temporary Anchorage Device as an Innovative Alternative for Unilateral Arch Mesialization in Medical Application. *Biointerface Research in Applied Chemistry* 2021;11 (2): 8825-8835
- Park JH, Bayome M, Kook YA. Distalization of maxillary and mandibular molars with TADs. In: *Temporary Anchorage Devices in Clinical Orthodontics*. 2020: 143-52.
- Elshebiny T, Palomo JM, Baumgaertel S. Anatomic assessment of the mandibular buccal shelf for miniscrew insertion in white patients. *Am J Orthod Dentofacial Orthop* 2018;153:505-11.
- Nucera R, Lo Giudice A, Bellocchio AM, Spinuzza P, Caprioglio A, Perillo L, *et al.* Bone and cortical bone thickness of mandibular buccal shelf for mini-screw insertion in adults. *Angle Orthod* 2017;87:745-51.
- Villegas C, Uribe F. A new and innovative TAD system for improved stability and versatility. In: *Temporary Anchorage Devices in Clinical Orthodontics*. Arizona, USA: Wiley-Blackwell; 2020. p. 455-65.
- Antoszevska-Smith J, Sarul M, Lyczek J, Konopka T, Kawala B. Effectiveness of orthodontic miniscrew implants in anchorage reinforcement during en-masse retraction: A systematic review and meta-analysis. *Am J Orthod Dentofacial Orthop* 2017;151:440-55.
- Wilmes B, Willmann J, Stocker B, Drescher D. The benefit system and its scope in contemporary orthodontic protocols. *APOS Trends Orthod* 2015;5:174-80.
- Tarraf NE, Darendeliler MA. Miniscrews vs. Miniplates. *Temporary Anchorage Devices in Clinical Orthodontics*. Arizona, USA:Wiley-Blackwell; 2020. p. 477-88.
- Chen K, Cao Y. Class III malocclusion treated with distalization of the mandibular dentition with miniscrew anchorage: A 2-year follow-up. *Am J Orthod Dentofacial Orthop* 2015;148:1043-53.
- Hakami Z, Chen PJ, Ahmida A, Janakiraman N, Uribe F. Miniplate-aided mandibular dentition distalization as a camouflage treatment of a Class III malocclusion in an adult. *Case Rep Dent*; 2018:3542792.
- Bhaskar V. Diagnosis and treatment considerations of orthodontic miniscrews in camouflage treatment of adult Class III malocclusions by distalization of the mandibular dentition-A review of literature. *Ann Dent Univ Malaya* 2019;26:62-8.
- Chen J, Patino JI, Chang JZ, Yao CC, Nielsen IL. A comparison of two TAD techniques (miniscrews versus miniplates) for treating class III malocclusion and the associated skeletal and dental effects. *Taiwanese Journal of Orthodontics*. 2020;31 (3):1
- Kim YS, Cha JY, Yu HS, Hwang CJ. Comparison of mandibular anterior alveolar bone thickness in different facial skeletal types. *Korean J Orthod* 2010;40:314-24.
- Oh SH, Nahm KY, Kim SH, Nelson G. Alveolar bone thickness and fenestration of incisors in untreated Korean patients with skeletal class III malocclusion: A retrospective 3-dimensional cone-beam computed tomography study. *Imaging Sci Dent* 2020;50:9-14.
- Oltramari PV, Conti AC, Navarro RD, Almeida MR, Almeida-Pedrin RR, Ferreira FP. Importance of occlusion aspects in the completion of orthodontic treatment. *Braz Dent J* 2007;18:78-82.