

## Original Article

# Evaluation of Epstein–Barr virus expression in oral squamous cell carcinomas

Saeedeh Khalesi<sup>1</sup>, Laleh Maleki<sup>2</sup>, Farzad Ghapani<sup>3</sup>

<sup>1</sup>Dental Materials Research Center, Department of Oral and Maxillofacial Pathology, Dental School, Isfahan University of Medical Sciences, <sup>2</sup>Department of Oral and Maxillofacial Pathology, Dental Research Center, Dental School, Isfahan University of Medical Science, <sup>3</sup>Department of Oral and Maxillofacial Pathology, Dental Students' Research Committee, Dental School, Isfahan University of Medical Sciences, Isfahan, Iran

## ABSTRACT

**Background:** Oral squamous cell carcinoma (OSCC) is one of the most common cancers. Epstein–Barr virus (EBV) has been related to throat-esophageal and gastric cancers. The aim of this study was to evaluate the prevalence of EBV in OSCC.

**Materials and Methods:** This descriptive-analytical cross-sectional study was performed on 48 samples recorded in the archives of the Oral Pathology Department of Isfahan Dental School with definitive diagnosis of OSCCs prepared by excisional biopsy. Samples were selected in different age groups, locations, and genders. The grade of the tumor malignancy was determined based on Annreroth's classification. The EBV expression was determined by immunohistochemical (IHC) staining. The data were entered into SPSS software and statistically analyzed by *t*-test, Chi-square, and Fisher's exact test. Significance level was considered  $P < 0.05$ .

**Results:** IHC staining for EBV was positive in 25 samples (52%). There was no significant relationship between EBV expression and mean age, gender, clinical feature, and grade of tumor differentiation ( $P > 0.05$ ). A significant difference was observed between the EBV expression and location ( $P = 0.035$ ). Furthermore, a significant difference was observed between the grade of tumor and staining intensity distribution index of EBV ( $P = 0.005$ ).

**Conclusion:** EBV expression was observed in most of the OSCCs, especially in poorly differentiated tumors. The pathogenesis of OSCCs may be related with EBV. OSCCs in buccal mucosa and floor of the mouth have more frequently of EBV expression. Future studies on the mechanisms of EBV and their role in OSCC are required with larger sample sizes.

**Key Words:** Epstein–Barr virus, oral cancer, squamous cell carcinoma

Received: 27-Jul-2021  
Revised: 18-Sep-2021  
Accepted: 12-Dec-2021  
Published: 18-Jul-2022

### Address for correspondence:

Dr. Laleh Maleki,  
Dental Research Center,  
Dental School, Isfahan  
University of Medical  
Science, Isfahan, Iran.  
E-mail: l.maleki@dnt.mui.  
ac.ir

## INTRODUCTION

Oral squamous cell carcinoma (OSCC) is one of the most common cancers and accounts for more than 90% of oral malignancies (about 94%). It is the sixth most common cancers in worldwide.<sup>[1-3]</sup> According to the studies, the age of patient is one of the factors influencing the

incidence of cancer. Alcohol and tobacco are known as risk factors for oral and oropharynx cancers. Nutritional factors such as Vitamin A and carotenoid deficiency may also play a role in oral cancers.<sup>[4]</sup> In the last two decades, the prevalence of head and neck cancers including oral and pharynx squamous cell carcinomas (SCCs) had

This is an open access journal, and articles are distributed under the terms of the Creative Commons Attribution-NonCommercial-ShareAlike 4.0 License, which allows others to remix, tweak, and build upon the work non-commercially, as long as appropriate credit is given and the new creations are licensed under the identical terms.

**For reprints contact:** WKHLRPMedknow\_reprints@wolterskluwer.com

**How to cite this article:** Khalesi S, Maleki L, Ghapani F. Evaluation of Epstein–Barr virus expression in oral squamous cell carcinomas. Dent Res J 2022;19:58.

### Access this article online



Website: [www.drj.ir](http://www.drj.ir)  
[www.drjjournal.net](http://www.drjjournal.net)  
[www.ncbi.nlm.nih.gov/pmc/journals/1480](http://www.ncbi.nlm.nih.gov/pmc/journals/1480)

increased. Prevalence increasing especially in young people without the common risk factors suggests the presence of other factors in the etiology of head and neck SCCs.<sup>[5]</sup> Other etiological factors such as genetics, diet, oncogenic viruses, and their effect on the physiological mechanism of cell proliferation control have been recommended.<sup>[6]</sup>

Epstein–Barr virus (EBV) is a type of herpes virus that affects more than 90% of the world's population.<sup>[7]</sup> According to the studies, EBV infection is one of the most important cancer-related factors such as Burkitt's lymphoma, Hodgkin's and non-Hodgkin's lymphoma, nasopharyngeal carcinoma, and dendritic cell malignancy. EBV has also been related to esophageal and gastric cancers.<sup>[8,9]</sup> In addition, a significant association between epithelial and lymphatic cancers such as cancers of the abdomen, lungs, and uterus has been identified with this virus.<sup>[9-11]</sup> In recent years, the hypothesis of a role of EBV which is an oncogenic virus in the development of OSCC has been proposed.<sup>[12]</sup> In the head and neck, EBV infection and genetic alterations of the virus in epithelial cells can cause the development, progression, and invasion of nasopharyngeal carcinoma. Latency-associated proteins, latent membrane protein 1 (LMP-1) and LMP-2 proteins, and EBV nuclear antigens have been identified, including LMP-1 protein as an oncogene protein.<sup>[7]</sup> EBV infection has an important role in delaying cell differentiation.<sup>[13,14]</sup>

In She *et al.*'s study, EBV infection had a direct relationship with increasing risk of OSCC.<sup>[15]</sup> Furthermore, in Kikuchi *et al.*'s study the expression of the latent esophageal variceal bleeding genes in the normal epithelium, inflamed gingiva, dysplastic epithelium, and OSCC has been observed.<sup>[16]</sup> Despite the studies on the association of SCCs and EBV, the role of tumorigenesis of EBV in oral epithelial cells is still unclear, therefore more studies in this field are necessary. Due to the high prevalence of SCCs in Iran and its unfavorable prognosis in the most patients and also the lack of studies on EBV in OSCC, the aim of this study was to investigate the EBV expression in OSCCs registered in the Department of Oral Pathology of Isfahan Dental School.

## MATERIALS AND METHODS

### Patients and tissue selection

This cross-sectional study was approved in research and ethics committee of Isfahan (NO: 399247), the samples

of 48 patients with a definitive diagnosis of OSCC in the archives of the Department of Oral and Maxillofacial Pathology, Dental School at Isfahan University of Medical Sciences were retrieved. Specimens with definitive diagnosis of OSCC, which were prepared by excisional biopsy and had complete information and tissue block suitable for immunohistochemical (IHC) staining, were included in the study. Demographic information including age, gender, location of lesion, and clinical feature were extracted from the files and recorded in the data collection form. The H and E stained slides of all samples were reviewed by two oral pathologists to confirm the diagnosis and check the quality of samples. Furthermore, the grade of malignancy of the tumor was determined based on the Anneroth *et al.* classification.<sup>[17]</sup>

### Immunohistochemical staining

For the detection of EBV expression by IHC staining, 3–4 µm sections were cut from the paraffin-embedded tissues. The tissue sections were deparaffinized with xylene and rehydrated with graded ethanol. For antigen retrieval, the sections were heated in a microwave oven at 96°C for 15 min in citrate buffer (0.01 M citrate buffer, pH 6.0), and then cooled at room temperature for 20 min. Endogenous peroxidase activity was blocked by incubation with 3% H<sub>2</sub>O<sub>2</sub> in methanol for 20 min and the sections were washed with phosphate-buffered saline. Slides were treated with Ficin and incubated with the monoclonal mouse EBV antibody (Cell Marque clone Epstein-Barr Virus (MRQ-47) Rabbit Monoclonal Antibody) at 1:100 dilution overnight at 2°C–8°C. The slides were then incubated with a biotinylated anti-rabbit secondary antibody (1:100 dilution) for 30 min at room temperature. The slides were parmounted with coverslip and bound antibody was detected for EBV. The tissue sections were considered positive by brown color cytoplasmic or/and nuclear staining of the tumor cells. EBV-infected Hodgkin's lymphoma was included as a positive control.

### Assessment of immunohistochemical staining

To analyze IHC staining, all slides were examined by two oral pathologists blindly with light microscopy (Olympus BX41TF, Tokyo, Japan), and cells were counted at ×400 magnification in 10 randomly selected fields. Tissue samples with cytoplasmic and nuclear brown staining of tumor cells were considered positive. The epithelial cells were evaluated using the semi-quantitative scale: 0 (negative: without immunostained cells), +1 (<25% immunostained), +2 (25%–50%), and +3 (>50%).

Furthermore, staining intensity was evaluated on the following scores: 0 (without immunostained cells), +1 (very low staining), +2 (low), +3 (moderate), and +4 (high). Staining intensity distribution (SID) score was calculated by multiplying the distribution by staining intensity.<sup>[18]</sup>

### Statistical analysis

The data obtained from clinical, histopathological, and IHC studies were analyzed by the Statistical Package for the Social Sciences, version 24.0 (SPSS Inc., Chicago, IL, USA) using *t*-test, Chi-square, and Fisher's exact test. The significance level was considered  $P < 0.05$ .

## RESULTS

In this study, of 48 OSCCs were 23 (48%) negative samples and 25 (52%) positive samples in IHC staining for EBV virus. The mean age of the samples with a negative result was  $65.52 \pm 14.09$  and the mean age of the positive samples was  $61.28 \pm 17.53$ . According to *t*-test, the mean age of the samples did not show a significant difference-based expression of EBV ( $P = 0.098$ ).

Furthermore, Chi-square test show that no significant relationship was observed between EBV expression and gender in OSCCs ( $P=0.263$ ) (Table1).

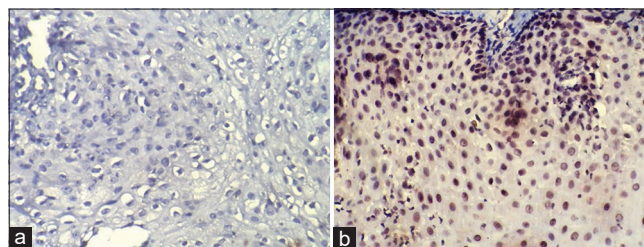
81.8% of buccal mucosa samples and 83.3% of oral floor OSCCs had EBV expression. Based on Fisher's exact test, a significant relationship was observed between the EBV expression and location of OSCCs ( $P = 0.035$ ). Furthermore, according to Fisher's exact test, no significant relationship was observed between the EBV expression and the clinical presentation ( $P = 0.772$ ).

Positive staining has been reported in 100% of poorly differentiated OSCCs. Based on Fisher's exact test, a significant difference was not observed between EBV expression and the grading of OSCCs ( $P = 0.38$ ). The lowest SID index for EBV observed in well-differentiated OSCCs, while SID index has not different significantly between Moderate and poorly differentiated tumors [Figure 1]. According to Kruskal-Wallis test, the SID index in different grading of tumor was significantly different ( $P = 0.005$ ). Mann-Whitney statistical test showed the significant difference between well and moderately differentiated tumors based on SID index ( $P = 0.007$ ), and between well and poorly

differentiated tumors ( $P = 0.024$ ). However, the difference between moderate and poorly differentiated tumors was not significant ( $P = 0.814$ ) [Table 2].

## DISCUSSION

According to the studies, viruses play a very important role in causing many malignant lesions of the head



**Figure 1:** (a) Negative result for Epstein-Barr virus, (b) Epstein-Barr virus expression in Oral squamous cell carcinoma (Immunohistochemical staining, x400).

**Table 1: Frequency of Epstein-Barr virus expression in oral squamous cell carcinomas based on study variables**

EBV	Negative, n (%)	Positive, n (%)	Total, n (%)	P
Gender				
Male	13 (41.9)	18 (58.1)	31 (100)	0.263
Female	10 (58.8)	7 (41.2)	17 (100)	
Location				
Tongue	9 (56.2)	7 (43.8)	16 (100)	0.035
Alveolar ridge	6 (75)	2 (25)	8 (100)	
Palate	5 (71.4)	2 (28.6)	7 (100)	
Buccal mucosa	2 (18.2)	9 (81.8)	11 (100)	
Floor of mouth	1 (16.7)	5 (81.3)	6 (100)	
Clinical feature				
Ulcer	10 (55.5)	8 (44.5)	18 (100)	0.772
Exophytic lesion	12 (46.2)	14 (53.8)	26 (100)	
White lesion	1 (33.3)	2 (66.7)	3 (100)	
Red lesion	0	1 (100)	1 (100)	
Histopathological grading				
Well differentiated	20 (51.3)	19 (48.7)	39 (100)	0.38
Moderate differentiated	3 (50)	3 (50)	6 (100)	
Poorly differentiated	0	3 (100)	3 (100)	

EBV: Epstein-Barr virus

**Table 2: Mean±standard deviation of staining intensity distribution index for Epstein-Barr virus expression in oral squamous cell carcinomas**

Grading of tumor	n	Mean±SD	Minimal	Maximum	P
Well differentiated	19	4.36±2.4	2	9	0.005
Moderate differentiated	3	10±1.73	9	12	
Poorly differentiated	3	10±3.46	6	12	
Total	25	5.72±3.4	2	12	

SD: Standard deviation



and neck, especially nasopharyngeal carcinoma,<sup>[19]</sup> but the pathogenic role of EBV in oral cancers is still unclear. In the present study, 52% of the samples showed a positive result for EBV in IHC staining. In the studies of Saravani *et al.* 16.7%,<sup>[20]</sup> Shamma *et al.* 81.8%,<sup>[19]</sup> Acharya *et al.* 45.05%,<sup>[21]</sup> Yen *et al.* 82.5%,<sup>[22]</sup> Kikuchi *et al.*<sup>[16]</sup> Kis *et al.* 73.8%,<sup>[23]</sup> Began 40%,<sup>[24]</sup> Sand *et al.* 9.9%,<sup>[25]</sup> Broccolo *et al.* 72.7%,<sup>[26]</sup> Saleem *et al.* 22.6%,<sup>[12]</sup> Polz-Gruszka *et al.* 1/26%,<sup>[27]</sup> and Rahman *et al.* 59.67%<sup>[14]</sup> of the OSCCs were reported positive. The results of these studies indicate the important role of EBV in OSCC.<sup>[19]</sup> However, in many studies, the prevalence of EBV has been reported to be higher than in our study, which can be attributed to various diagnostic techniques of the virus including polymerase chain reaction (PCR), Nested PCR, Real-time-quantitative PCR, IHC, *in situ* hybridization in these studies.<sup>[15]</sup> Furthermore, this difference in results can be related to geographical areas and characteristics of people.<sup>[20]</sup> For example, a significant association between EBV and OSCC has been observed in Europe and the United States, which may be related to individuals' genetics, socioeconomic status, and lifestyle in these areas.<sup>[28]</sup> According to She *et al.*, EBV infection is directly related to an increased risk of OSCC.<sup>[15]</sup> In the Jaloluli's study the incidence of EBV was seen in 55% of the samples from eight different countries.<sup>[29]</sup> In EBV-associated malignancies, viral proteins have been identified that are involved in regulating proliferation, immune response, and cellular apoptosis.<sup>[30]</sup> The most of the studies were stated that EBV DNA, mRNA, and EBV proteins are expressed in most of the OSCCs.<sup>[15]</sup>

In the present study, the mean age of samples with a negative result of EBV ( $65.52 \pm 14.09$ ) was higher than positive samples ( $61.28 \pm 17.53$ ), but there was no statistically significant difference between the mean age and EBV expression that consistent with the studies of Saleem *et al.*,<sup>[12]</sup> Sand *et al.*,<sup>[25]</sup> She *et al.*,<sup>[15]</sup> Shamma *et al.*<sup>[19]</sup> and Saravani *et al.*<sup>[20]</sup> In Yen *et al.*'s study, the mean age of the negative cases was significantly higher than the positive cases.<sup>[22]</sup> In the Polz-Gruszka *et al.*'s study, most of the samples in the age group of 50–59 years had the EBV genome.<sup>[27]</sup> The virus enters saliva, squamous epithelium, lymphoid organs, and B cells and can remain latent in the human body. The virus can reactivate without causing symptoms and can be detected in the saliva of infected people.<sup>[31]</sup>

In the present study, most of OSCCs in men (58.1%) had EBV expression, but most of the female samples (58.8%) had not EBV expression, although there was no statistically significant difference between gender and EBV expression, which is consistent with the study of Saravani *et al.*<sup>[20]</sup> In the Saleem *et al.*'s study, 97% of cases with EBV expression are men and only 3% are females.<sup>[12]</sup> In the Shamma *et al.*'s study, a significant relationship was reported between gender and the incidence of EBV, which in this study also showed a higher expression of EBV in men.<sup>[19]</sup> One of the reasons for these results is related to the risk factors in men associated with OSCC. Various studies have examined the role of alcohol consumption and various forms of tobacco and its relationship with EBV in OSCCs. In the Acharya *et al.*'s study, Betel quid chewing was associated with EBV, but alcohol and smoking were not associated with the virus.<sup>[21]</sup> The study of Saleem *et al.*,<sup>[12]</sup> Polz-Gruszka *et al.*,<sup>[27]</sup> and Drop *et al.*<sup>[31]</sup> also reported an EBV association with oral cancer in tobacco users.

In the present study, a significant relationship was found between the EBV expression and location of the lesion. OSCCs in buccal mucosa and floor of the mouth have more frequently of EBV expression, which is consistent with the Saleem *et al.*<sup>[12]</sup> and Deng *et al.*<sup>[7]</sup> studies. In Mao and Smith study, the tongue was the main location for EBV expression.<sup>[32]</sup> In addition, in Yen *et al.*<sup>[22]</sup> and Shamma *et al.*<sup>[19]</sup> study, no relationship was observed between the location of the lesion and EBV expression. In some OSCC studies, tonsils and the base of the tongue have been associated with a higher incidence of EBV. One of the reasons for the result may be the expression of a specific C3D receptor on the surface of the keratinized squamous epithelium of the buccal mucosa. This receptor has been evaluated in previous studies of nasopharyngeal carcinoma and its role in virus binding has been demonstrated.<sup>[12,13]</sup>

In the present study, the most exophytic lesions had EBV expression, although the relationship between the EBV expression and the clinical appearance of the lesion did not show a statistically significant difference. In Yen *et al.*'s study, a higher EBV expression was reported significantly in samples with exophytic appearance and ulcer lesions. The lesions with invading deeper tissues also showed a higher expression of EBV.<sup>[22]</sup>

In the present study, there was no significant difference between the grading of tumor malignancy and EBV expression, although SID index increased significantly with increasing tumor malignancy, which is consistent with the Saleem *et al.*'s<sup>[12]</sup> and Broccolo *et al.*'s<sup>[26]</sup> studies. In some studies, a significant relationship has been found between EBV expression and histological types of nasopharyngeal carcinoma.<sup>[12,33]</sup> In Broccolo *et al.*'s study,<sup>[26]</sup> EBV expression was higher in nonkeratinized SCC than in keratinized SCC. The Polz-Gruszka *et al.*'s study<sup>[27]</sup> also showed the more EBV expression in invasive types of oral tumors. Although the presence of EBV was not influential in the prognosis of OSCC in Deng *et al.*<sup>[7]</sup> study, but in Shamma *et al.*<sup>[19]</sup> study, the EBV expression was significantly higher in less differentiation tumors and the tumors with lymph node metastasis than well and moderate differentiation tumors. Thus, EBV infection delays epithelial cell differentiation and increases epithelial cells.<sup>[31]</sup>

Restrictions in choosing more sample size and low number of OSCC with moderate and poorly differentiation of OSCC were the current research limitations.

## CONCLUSION

EBV expression was observed in the most of OSCCs and especially in poorly differentiated tumors. The pathogenesis of OSCC may be related with EBV. OSCCs in buccal mucosa and floor of the mouth have more frequently EBV expression. Future studies on the mechanisms of EBV and their role in OSCC are required with larger sample sizes.

## Financial support and sponsorship

Nil.

## Conflicts of interest

There are no conflicts of interest.

## REFERENCES

- Chimenos-Küstner E, Marques-Soares MS, Schemel-Suárez M. Aetiopathology and prevention of oropharyngeal cancer. *Semergen* 2019;45:497-503.
- Chegini S, Mitsimponas K, Shakib K. A review of recent advances in histopathological assessment of head and neck squamous cell carcinoma. *J Oral Pathol Med* 2020;49:9-13.
- Scully C, Bagan J. Oral squamous cell carcinoma overview. *Oral Oncol* 2009;45:301-8.
- Jiang S, Dong Y. Human papillomavirus and oral squamous cell carcinoma: A review of HPV-positive oral squamous cell carcinoma and possible strategies for future. *Curr Probl Cancer* 2017;41:323-7.
- Chaturvedi AK, Engels EA, Anderson WF, Gillison ML. Incidence trends for human papillomavirus-related and -unrelated oral squamous cell carcinomas in the United States. *J Clin Oncol* 2008;26:612-9.
- Nemes JA, Deli L, Nemes Z, Márton IJ. Expression of p16(INK4A), p53, and Rb proteins are independent from the presence of human papillomavirus genes in oral squamous cell carcinoma. *Oral Surg Oral Med Oral Pathol Oral Radiol Endod* 2006;102:344-52.
- Deng Z, Uehara T, Maeda H, Hasegawa M, Matayoshi S, Kiyuna A, *et al.* Epstein-Barr virus and human papillomavirus infections and genotype distribution in head and neck cancers. *PLoS One* 2014;9:e113702.
- Vasef MA, Ubaidat MA, Khalidi HS, Almasri NM, Al-Abbadi M, Annab HZ. Association between Epstein-Barr virus and classic Hodgkin lymphoma in Jordan: A comparative study with Epstein-Barr virus-associated Hodgkin lymphoma in North America. *South Med J* 2004;97:273-7.
- Jemal A, Bray F, Center MM, Ferlay J, Ward E, Forman D. Global cancer statistics. *CA Cancer J Clin* 2011;61:69-90.
- Parkin DM, Bray F, Ferlay J, Pisani P. Global cancer statistics, 2002. *CA Cancer J Clin* 2005;55:74-108.
- Siegel R, Ma J, Zou Z, Jemal A. Cancer statistics, 2014. *CA Cancer J Clin* 2014;64:9-29.
- Saleem MW, Baig FA, Hadi NI. A novel comparison of Epstein-Barr virus with broad histological spectrum of oral squamous cell carcinoma. *Pak J Med Sci* 2019;35:1192-8.
- Guidry JT, Birdwell CE, Scott RS. Epstein-Barr virus in the pathogenesis of oral cancers. *Oral Dis* 2018;24:497-508.
- Rahman R, Poomsawat S, Juengsomjit R, Buajeeb W. Overexpression of Epstein-Barr virus-encoded latent membrane protein-1 (LMP-1) in oral squamous cell carcinoma. *BMC Oral Health* 2019;19:142.
- She Y, Nong X, Zhang M, Wang M. Epstein-Barr virus infection and oral squamous cell carcinoma risk: A meta-analysis. *PLoS One* 2017;12:e0186860.
- Kikuchi K, Inoue H, Miyazaki Y, Ide F, Kojima M, Kusama K. Epstein-Barr virus (EBV)-associated epithelial and non-epithelial lesions of the oral cavity. *Jpn Dent Sci Rev* 2017;53:95-109.
- Anneroth G, Batsakis J, Luna M. Review of the literature and a recommended system of malignancy grading in oral squamous cell carcinomas. *Scand J Dent Res* 1987;95:229-49.
- Flórez-Moreno GA, Henao-Ruiz M, Santa-Sáenz DM, Castañeda-Peláez DA, Tobón-Arroyave SI. Cytomorphometric and immunohistochemical comparison between central and peripheral giant cell lesions of the jaws. *Oral Surg Oral Med Oral Pathol Oral Radiol Endod* 2008;105:625-32.
- Shamma AA, Zyada MM, Wagner M, Awad SS, Osman MM, Abdelazeem AA. The significance of Epstein Barr Virus (EBV) & DNA Topoisomerase II alpha (DNA-Topo II alpha) immunoreactivity in normal oral mucosa, oral epithelial dysplasia (OED) and oral squamous cell carcinoma (OSCC). *Diagn Pathol* 2008;3:45.
- Saravani S, Miri-Moghaddam E, Sanadgol N, Kadeh H, Nazeri MR. Human herpesvirus-6 and Epstein-Barr virus

- infections at different histopathological grades of oral squamous cell carcinomas. *Int J Prev Med* 2014;5:1231-8.
21. Acharya S, Ekalaksananan T, Vatanasapt P, Loyha K, Phusingha P, Promthet S, *et al.* Association of Epstein-Barr virus infection with oral squamous cell carcinoma in a case-control study. *J Oral Pathol Med* 2015;44:252-7.
  22. Yen CY, Lu MC, Tzeng CC, Huang JY, Chang HW, Chen RS, *et al.* Detection of EBV infection and gene expression in oral cancer from patients in Taiwan by microarray analysis. *J Biomed Biotechnol* 2009;2009:904589.
  23. Kis A, Fehér E, Gáll T, Tar I, Boda R, Tóth ED, *et al.* Epstein-Barr virus prevalence in oral squamous cell cancer and in potentially malignant oral disorders in an eastern Hungarian population. *Eur J Oral Sci* 2009;117:536-40.
  24. Bagan JV, Jiménez Y, Murillo J, Poveda R, Díaz JM, Gavaldá C, *et al.* Epstein-Barr virus in oral proliferative verrucous leukoplakia and squamous cell carcinoma: A preliminary study. *Med Oral Patol Oral Cir Bucal* 2008;13:E110-3.
  25. Sand LP, Jalouli J, Larsson PA, Hirsch JM. Prevalence of Epstein-Barr virus in oral squamous cell carcinoma, oral lichen planus, and normal oral mucosa. *Oral Surg Oral Med Oral Pathol Oral Radiol Endod* 2002;93:586-92.
  26. Broccolo F, Ciccarese G, Rossi A, Anselmi L, Drago F, Toniolo A. Human papillomavirus (HPV) and Epstein-Barr virus (EBV) in keratinizing versus non-keratinizing squamous cell carcinoma of the oropharynx. *Infect Agent Cancer* 2018;13:32.
  27. Polz-Gruszka D, Morshed K, Jarzyński A, Polz-Dacewicz M. Prevalence of polyoma BK virus (BKPyV), Epstein-Barr virus (EBV) and Human papilloma virus (HPV) in oropharyngeal cancer. *Pol J Microbiol* 2015;64:323-8.
  28. Adeyemi BF, Olusanya AA, Lawoyin JO. Oral squamous cell carcinoma, socioeconomic status and history of exposure to alcohol and tobacco. *J Natl Med Assoc* 2011;103:498-502.
  29. Jalouli J, Jalouli MM, Sapkota D, Ibrahim SO, Larsson PA, Sand L. Human papilloma virus, herpes simplex virus and Epstein Barr virus in oral squamous cell carcinoma from eight different countries. *Anticancer Res* 2012;32:571-80.
  30. Mesri EA, Feitelson MA, Munger K. Human viral oncogenesis: A cancer hallmarks analysis. *Cell Host Microbe* 2014;15:266-82.
  31. Drop B, Strycharz-Dudziak M, Kliszczewska E, Polz-Dacewicz M. Coinfection with Epstein-Barr virus (EBV), Human papilloma virus (HPV) and polyoma BK virus (BKPyV) in laryngeal, oropharyngeal and oral cavity cancer. *Int J Mol Sci* 2017;18:2752.
  32. Mao EJ, Smith CJ. Detection of Epstein-Barr virus (EBV) DNA by the polymerase chain reaction (PCR) in oral smears from healthy individuals and patients with squamous cell carcinoma. *J Oral Pathol Med* 1993;22:12-7.
  33. Raab-Traub N, Flynn K, Pearson G, Huang A, Levine P, Lanier A, *et al.* The differentiated form of nasopharyngeal carcinoma contains Epstein-Barr virus DNA. *Int J Cancer* 1987;39:25-9.