

## Case Report

# Long-term results of immediate implantation in mandibular posterior teeth with early loading: A retrospective case series

Nader Ayubianmarkazi<sup>1</sup>, Douglas Deporter<sup>2</sup>, Maziar Ebrahimi Dastgurdi<sup>3</sup>, Nasrin Akhondi<sup>4</sup>, Mohammad Ketabi<sup>2,5</sup>

<sup>1</sup>Department of Periodontics, Faculty of Dentistry, Tehran Medical Sciences, Islamic Azad University, Tehran, Iran, <sup>2</sup>Department of Periodontology, Faculty of Dentistry, University of Toronto, Canada, <sup>3</sup>Private Practitioner (Endodontist), Toronto, Canada, <sup>4</sup>Department of Mathematics, South Tehran Branch, Islamic Azad University, Tehran, Iran, <sup>5</sup>Department of Periodontics, School of Dentistry, Islamic Azad University, Isfahan, Iran

## ABSTRACT

When immediate molar implants first were proposed, submerged initial healing and delayed loading were the norm. It is now recognized that some early loading of a nonocclusal nature can stimulate faster osseointegration, although full occlusal loading is still delayed for 3 or more months. Here, we test the hypothesis that earlier occlusal loading of mandibular premolar and molar immediate implants may be possible. In this retrospective case series study, 18 mandibular molar and nine mandibular premolar teeth were atraumatically extracted and immediate implants placed 1–2 mm apical to buccal and lingual crestal bone. Periimplant gaps received particular allograft covered with acellular dermal matrix barrier. Healing abutments were placed through puncture points in the membranes to help in stabilizing the latter and to permit nonsubmerged site healing. At 6–8 weeks, each implant was evaluated for stability using the Periotest® device and restored if the Periotest® (PTV) value seen was negative. Data were analyzed by t test and MannWhitney U at a significance level of  $P < 0.05$ . Retrospective assessment of all 27 implants after 5 years' period of follow up showed all implants to have survived. Overall mean crestal bone loss was determined to be  $-0.25 \pm 0.54$  mm. Individual mean bone levels for mesial and distal surfaces were  $-0.24 \pm 0.77$  mm and  $-0.26 \pm 0.72$  mm, respectively ( $P = 0.78$ ). A statistically significant difference in bone loss between genders was detected. Overall mean probing depth was  $2.09 \pm 0.57$  mm. Based on the widely used Albrektsson criteria, the overall survival and success rate was 100%. Immediate implants placed into mandibular premolar and molar extraction sockets and allowed nonsubmerged healing may be ready for restoration at earlier times than previously thought possible.

**Key Words:** Dental implantation, immediate dental implant loading, single tooth dental implant

Received: 22-Jul-2021  
Revised: 05-Dec-2021  
Accepted: 26-Feb-2022  
Published: 16-Aug-2022

Address for correspondence:  
Dr. Mohammad Ketabi,  
Department of Periodontics,  
School of Dentistry,  
Islamic Azad University,  
Arghavanieh, Isfahan, Iran.  
E-mail: ketabimohammad@  
yahoo.com

## INTRODUCTION

The original and well-tested principles of implant placement in healed extraction sites (“delayed implant placement”) continue to be used, and certainly molar replacement with single implants using this approach has shown predictably

successful long-term results, particularly in mandible and when natural teeth are present on either side of the implant.<sup>[1-5]</sup> More recently, however, the trend has been to place molar implants immediately after tooth extraction as this reduces

This is an open access journal, and articles are distributed under the terms of the Creative Commons Attribution-NonCommercial-ShareAlike 4.0 License, which allows others to remix, tweak, and build upon the work non-commercially, as long as appropriate credit is given and the new creations are licensed under the identical terms.

**For reprints contact:** WKHLRPMedknow\_reprints@wolterskluwer.com

**How to cite this article:** Ayubianmarkazi N, Deporter D, Dastgurdi ME, Akhondi N, Ketabi M. Long-term results of immediate implantation in mandibular posterior teeth with early loading: A retrospective case series. Dent Res J 2022;19:66.

Access this article online



Website: [www.drj.ir](http://www.drj.ir)  
[www.drjjournal.net](http://www.drjjournal.net)  
[www.ncbi.nlm.nih.gov/pmc/journals/1480](http://www.ncbi.nlm.nih.gov/pmc/journals/1480)

treatment time and morbidity with increased patient acceptance.

The procedures needed for successful immediate molar implant (IMI) placement are definitely technique-sensitive and difficult to perform, especially by practitioners who attempt them infrequently.<sup>[6]</sup> A detailed working knowledge of mandibular anatomy is crucial to avoid failures and serious complications such as inferior alveolar nerve injury or lingual bone plate perforation at sites with unrecognized mandibular undercuts. From a restorative perspective, the inter-radicular septum of bone (IRS) represents the ideal position for immediate mandibular molar implant placement,<sup>[7,8]</sup> and its volume and height should be assessed preoperatively using cone-beam computed tomographic radiographic scan.<sup>[9]</sup> These records will allow the practitioner to determine the suitability of the IRS, the locations of the inferior alveolar and mental nerves, the buccolingual alveolar ridge width at the site, the width and length of IRS to canal, the presence of apical pathology, and the vertical bone height available recognizing that a buffer zone of 2 mm from the planned implant apex to the mandibular canal must be maintained to avoid nerve damage.<sup>[10,11]</sup>

Originally when IMIs were proposed, clinicians took the precautions of submerged initial healing and delayed loading. However, with time and experience the preferred approach became to allow nonsubmerged healing followed by delayed loading. More recently, however, it has been recognized that some early loading of a nonocclusal nature can be beneficial for IMIs and achieved by adding a stock or customized healing abutment immediately after implant placement. This limited loading was found to actually stimulate faster osseointegration.<sup>[12,13]</sup> In general, however, true occlusal loading is still delayed for 3 or more months postimplantation. We were intrigued to know whether mandibular IMIs could be fully loaded earlier than this and report here our findings with early loading of mandibular premolar and molar immediate implants placed using one-step, trans-mucosal healing.

## MATERIALS AND METHODS

For conducting this retrospective case series study, protocols were prepared and performed according to the 1975 Declaration of Helsinki as renewed in 2013.

### Patient selection

The data presented were collected from 18 patients (8 females and 10 males) with a mean age of 53.5 years who had received 27 (18 mandibular molars and 9 mandibular premolars) immediate implants. Criteria for selecting patients were as follows: (1) good general health; (2) recommendation of mandibular premolar and/or molar extractions due to root fracture, nontreatable caries, endodontic treatment failure or residual root retention; (3) for molar sites, a minimum of 5 mm width of IRS, as determined by means of periapical and cone beam computed tomographic (CBCT) radiographs; (4) and a minimum distance of 5 mm from the apices of the condemned tooth to mandibular canal to guarantee adequate primary stability of implants without violating the mandibular neurovascular canal. Criteria for excluding patients were history of (1) head and neck irradiation; (2) myocardial infarction in the previous year; (3) uncontrolled diabetes; (4) periodontitis, and (5) a smoking habit.

### Surgical procedure

All surgeries were performed by a single surgeon (NA). On the day of surgery, a prophylactic antibiotic (amoxicillin, 1 g) was prescribed for all patients an hour before surgery. Adequate local anesthesia (4% Articaine, 1:100,000 epinephrine) to achieve an inferior alveolar nerve block was administered. Before molar extraction, teeth were decoronated and sectioned to allow mesial and distal roots to be removed atraumatically. After verifying adequate an (IRS) width ( $\geq 5$  mm mesio-distally) at each molar site, osteotomies were initiated using either a small diameter round bur or a fine, sharp-pointed initial penetration bur positioned at the mesio-distal center of the IRS but slightly towards the lingual in order to compensate for any uncontrollable buccal drifting of subsequent burs.<sup>[14]</sup> Implants placed were either Xive<sup>®</sup>, (DENTSPLY International) or Axiom<sup>®</sup> (Antogyr, France). All implants were placed 1–2 mm apical to the buccal and lingual bone crest. Afterwards, remaining mesial and distal socket gaps were grafted (Tutodent<sup>®</sup> or Cerabon<sup>®</sup>, Tutogen Medical GmbH) and covered with acellular dermal matrix allograft membranes (SureDerm<sup>®</sup>, Hans Biomed Co. Ltd). Implants were placed according to the one-stage approach with healing abutments of appropriate size used to secure the membranes. Flaps were secured utilizing 4-0 Vicryl. Sutures, and patients prescribed amoxicillin 500 mg to be taken

three times daily (for 7 days), analgesics for use as required (ibuprofen, 200 mg; caffeine, 40 mg; and acetaminophen, 325 mg, Alvahi Pharmaceutical Co.) and 0.12% chlorhexidine mouth rinse for twice daily use.

All patients were evaluated 2 weeks after surgery and asked to continue using the chlorhexidine mouthwash and to avoid brushing over the implant area for another 3 weeks. After a healing period of 6–8 weeks, osseointegration was verified radiographically and with the Periotest® Device as recommended by the manufacturer (Siemens AG). Periotest values (PTV) were recorded twice and mean values recorded. Implants were loaded if PTV was negative at 6–8 weeks.

### Radiographic and clinical evaluation

The standard criteria of Albrektsson *et al.*<sup>[15]</sup> were used to evaluate the success, i.e., absence of mobility, pain, radiolucency, and  $\leq 1$  mm at 1 year and  $\leq 0.2$  mm/year bone loss thereafter. Peri-implant probing depths at mesial, distal, buccal, and lingual surfaces were measured using a William's periodontal probe. An implant was considered as having failed if it displayed mobility or excessive marginal bone loss as seen in periapical radiographs obtained using a My Ray Digital Imaging X-ray sensor™ and an X-Pod Wireless Digital System (Cefla SC Dental Group, Italy). The distances between the first bone-implant contact, which is the most coronal point of bone to implant contact and implant shoulder on the mesial and distal aspects of all implants were measured. The linear measurements were calibrated to the actual implant lengths using the X-Pod system. A molar sample case is shown in Figure 1a-i.

### Statistical analysis

Statistical measures (mean, standard deviation, minimum, maximum, and range) were calculated for quantitative variables, and distribution normality assumptions for them were assessed by Kolmogorov–Smirnov test ( $P > 0.05$ ). For comparing quantitative variables between groups of genders the independent sample *t*-test [when normality was held ( $P > 0.05$ )] or MannWhiney *U*-test (when normality was not held [ $P > 0.05$ ]) was used. For comparing bone loss between the mesial and distal surfaces paired sample *t*-test was used. The level of statistical significance was established at  $P > 0.05$ . Furthermore, 95% CI (confidence interval) for the mean of quantitative variables were calculated. All statistical analyses

were done by SPSS v15.0 (SPSS Inc, Chicago, IL) [Figure 1a-i].

## RESULTS

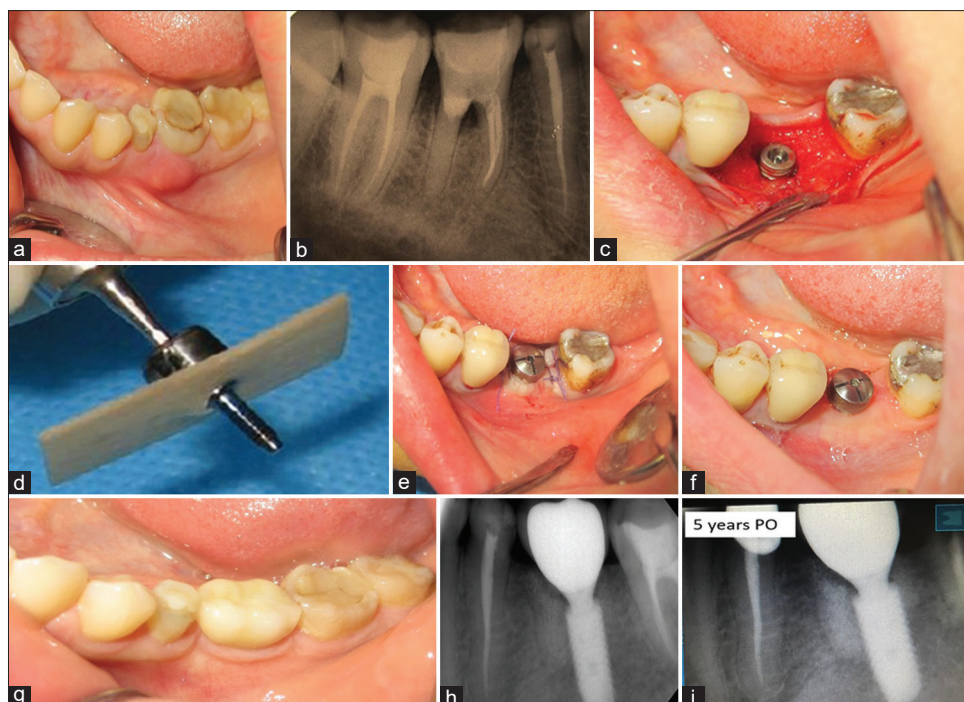
Healing was uneventful for all patients except for one who had a buccal wound dehiscence in the 1 week. For that patient, topical chlorhexidine gel application was prescribed twice daily and the patient followed weekly until complete soft tissue healing occurred. Twenty-one implants were restored with single crowns, whereas nine implants placed in four patients were splinted.

The mean age of the patient was 53.5 years. The mean loading onset was 7.5 weeks after surgery. No implant has been lost to date yielding a cumulative survival rate of 100% 5 years postsurgical. Mean bone levels for each implant were calculated by summing up the bone gain and bone loss at the mesial and distal surfaces of each implant which gave an overall mean of  $-0.25 \pm 0.54$  mm. Individual mean bone levels for mesial and distal surfaces were  $-0.24 \pm 0.77$  mm and  $-0.26 \pm 0.72$  mm, respectively ( $P = 0.78$ ) [Table 1]. A statistically significant difference in bone loss between genders was detected with less bone loss in females. Overall mean probing depth was  $2.09 \pm 0.57$  mm [Table 2].

## DISCUSSION

Systematic literature reviews of outcomes following immediate mandibular molar implant (IMI) placement have suggested this treatment modality to be viable and predictable.<sup>[16-19]</sup> Nevertheless, the approach is a challenging one requiring considerable skill and experience.<sup>[6]</sup> When IMIs were first attempted, investigators cautiously loaded them only after a healing interval of 4 or more months,<sup>[20]</sup> but recently, more aggressive approaches have been attempted. The most recent has been to load IMIs immediately following placement seeing this as a way to dramatically reduce overall treatment times. However, this can come with significant risks of early implant failure.<sup>[21]</sup>

Implants placed in healed extraction sites have been tested for performance with early loading, i.e., after 4–8 weeks site healing. For example, Nicolau *et al.*<sup>[22]</sup> recently reported 10-year results of a multicenter randomized controlled trial of implants placed in healed posterior jaw sites comparing



**Figure 1:** (a) This first molar presented with buccal swelling indicative of furcal infection, (b) The preoperative radiograph showed a partial endodontic treatment with significant inter-radicular bone loss, (c) Following minimally invasive extraction a 4.5/10 mm Axiom implant immediately placed in the inter-radicular septum and gaps grafted with particulate allograft, (d) An acellular dermal collagen membrane was skewered with the threaded portion of an appropriately-sized healing abutment before connecting the latter to the implant, (e) The soft tissues were stabilized with vicryl sutures, (f) Excellent soft-tissue healing with minimal alveolar ridge remodeling was observed at 6 weeks at which time restoration was begun, (g) The implant was restored with its definite restoration 6 weeks postoperative, (h) This periapical radiograph shows the radiographic status of the restored implant after 6 months loading showing excellent bone preservation, (i) This periapical radiograph shows the radiographic status of the restored implant after 5 years loading showing excellent bone preservation.

**Table 1: Means for mesial, distal surfaces, and combined bone loss (mm)**

Bone loss (mm)	Mean±SD			95% CI		
	Female	Male	Total	Female	Male	Total
Mesial	0.16±0.92 <sup>a</sup>	-0.57±0.44 <sup>b</sup>	-0.24±0.77	-0.6-0.93	-0.88--0.25	-0.62-0.14
Distal	0.13±0.91 <sup>a</sup>	-0.59±0.29 <sup>b</sup>	-0.26±0.72	-0.63-0.89	-0.8--0.37	-0.63-0.09
Total	0.15±0.91	-0.58±0.31	-0.25±0.73	-0.61-0.91	-0.80--0.35	-0.6-0.1

Lower cases show significant differences. CI: Confidence interval; SD: Standard deviation

**Table 2: Mean pocket probing depths per surface (mm)**

Pocket depth (mm)	Mean±SD			95% CI		
	Female	Male	Total	Female	Male	Total
Buccal	1.88±0.83	2.1±0.73	2.00±0.76	1.18-2.58	1.57-2.63	1.62-2.38
Lingual	1.75±0.88	2.3±0.82	2.06±0.87	1.01-2.49	1.71-2.89	1.62-2.49
Mesial	2.0±0.75	2.0±0.66	2.00±0.68	1.37-2.63	1.52-2.48	1.66-2.34
Distal	2.25±0.46	2.4±0.69	2.33±0.59	1.86-2.64	1.9-2.9	2.04-2.63
Total	1.96±0.38	2.2±0.55	2.09±0.57	1.45-2.48	1.8-2.59	1.63-2.35

CI: Confidence interval; SD: Standard deviation

immediate with early loading. Implant survival at 10 years was 98.2% and 97.1% for immediate and early loading. Mean crestal bone losses up to 10 years showed no significant difference ( $-1.25 \pm 0.99$  mm

vs.  $-0.89 \pm 1.11$  mm for immediate/early loading. However, between implant placement and 10 years, there was a significant difference ( $-2.00 \pm 1.19$  mm vs.  $-1.37 \pm 1.06$  mm;  $P = 0.02$ ) suggesting that early

loading performed better. However, the immediately loaded implants had been placed significantly deeper than the those given early loading and when this was considered in the analyses, no significant difference between the two groups could be seen after 10 years. Most recently, Levine *et al.*<sup>[23]</sup> reported that moderately rough implants placed in healed sites with initial torque values of  $\geq 35$  Ncm could be loaded even as early as 3–4 weeks.

We have recently published 5-year results for immediate maxillary molar implants placed with simultaneous trans-crestal sinus floor elevation followed by early loading.<sup>[24]</sup> Mean crestal bone loss after 5 years in function was  $-0.054 \pm 0.56$  mm (range  $-0.86$ – $+0.90$  mm). Survival rates and success rates<sup>[15]</sup> were 100% and 95.5%, respectively. Similar outcomes were seen in the present report using the same protocol of early loading with immediate implants placed into mandibular molar and premolar extraction sockets. Occlusal loading at 6–8 weeks resulted in 5-year survival and success rates both at 100%. The unusually small amounts of bone loss seen ( $-0.24 \pm 0.77$  mm and  $-0.26 \pm 0.72$  mm for mesial/distal surfaces respectively) may be explained by several factors. First, all implants were placed using flap-less surgery, eliminating interruption of periosteal blood supply.<sup>[25]</sup> Second, ideal implant positioning was achieved with placement slightly toward the lingual, thereby ensuring remaining buccal gaps to minimize buccal bone loss.

Deporter *et al.*<sup>[26]</sup> recently presented a classification of gaps based on location about the implant periphery. Seven gap types were proposed and Type I (buccal gap) was considered favorable which, the implant has been placed slightly palatally leaving a horizontal buccal gap between the implant and its socket wall.

All implants were submerged sub-crestal compensating for the effects of early remodeling<sup>[27]</sup> and incorporated a platform switching feature helping to minimize later crestal loss.<sup>[28]</sup> Implants in the present study also were exposed to immediate nonocclusal loading through their exposed healing abutments. Regarding this last factor, in a recent literature review and meta-analysis,<sup>[29]</sup> investigators concluded that immediate nonocclusal loading led to less bone loss at 1 year compared to immediate occlusal loading or conventional delayed loading. This outcome might seem counter-intuitive except that some level

of controlled implant loading during healing can be beneficial by stimulating bone formation.<sup>[30,31]</sup>

## CONCLUSION

Provided that flap-less surgery and atraumatic extraction has been accomplished, immediate implants placed at mandibular premolar and molar sites appear to be ready for early loading after shorter healing intervals than previously thought.

## Financial support and sponsorship

Nil.

## Conflicts of interest

The authors of this manuscript declare that they have no conflicts of interest, real or perceived, financial or non-financial in this article.

## REFERENCES

- Grant BT, Pancko FX, Kraut RA. Outcomes of placing short dental implants in the posterior mandible: A retrospective study of 124 cases. *J Oral Maxillofac Surg* 2009;67:713-7.
- Levin L, Laviv A, Schwartz-Arad D. Long-term success of implants replacing a single molar. *J Periodontol* 2006;77:1528-32.
- Polizzi G, Rangert B, Lekholm U, Gualini F, Lindström H. Brånemark System Wide Platform implants for single molar replacement: Clinical evaluation of prospective and retrospective materials. *Clin Implant Dent Relat Res* 2000;2:61-9.
- Tolstunov L. Implant zones of the jaws: Implant location and related success rate. *J Oral Implantol* 2007;33:211-20.
- Crespi R, Cappare P, Crespi G, Gastaldi G, Gherlone EF. Delayed implants outcome in maxillary molar region. *Clin Implant Dent Relat Res* 2017;19:261-7.
- Dawson A, Chen S. *The SAC Classification in Implant Dentistry*. Berlin: Quintessence; 2009.
- Fugazzotto PA. Implant placement at the time of mandibular molar extraction: Description of technique and preliminary results of 341 cases. *J Periodontol* 2008;79:737-47.
- El Haddad E, Lauritano D, Carinci F. Interradicular septum as guide for pilot drill in postextractive implantology: A technical note. *J Contemp Dent Pract* 2015;16:81-4.
- Froum S, Casanova L, Byrne S, Cho SC. Risk assessment before extraction for immediate implant placement in the posterior mandible: A computerized tomographic scan study. *J Periodontol* 2011;82:395-402.
- Demircan S. Prosthetically driven immediate implant placement at lower molar area; an anatomical study. *Eur Oral Res* 2020;54:25-30.
- Padhye NM, Shirsekar VU, Bhatavdekar NB. Three-dimensional alveolar bone assessment of mandibular first molars with implications for immediate implant placement. *Int J Periodontics Restorative Dent* 2020;40:e163-7.
- Chavarri-Prado D, Brizuela-Velasco A, Álvarez-Arenal Á, Dieguez-Pereira M, Pérez-Pevida E, Viteri-Agustín I, *et al.* The

- bone buttress theory: The effect of the mechanical loading of bone on the osseointegration of dental implants. *Biology (Basel)* 2020;10:12.
13. Vandamme K, Naert I, Geris L, Vander Sloten J, Puers R, Duyck J. The effect of micro-motion on the tissue response around immediately loaded roughened titanium implants in the rabbit. *Eur J Oral Sci* 2007;115:21-9.
  14. Hayacibara RM, Gonçalves CS, Garcez-Filho J, Magro-Filho O, Esper H, Hayacibara MF. The success rate of immediate implant placement of mandibular molars: A clinical and radiographic retrospective evaluation between 2 and 8 years. *Clin Oral Implants Res* 2013;24:806-11.
  15. Albrektsson T, Zarb G, Worthington P, Eriksson AR. The long-term efficacy of currently used dental implants: A review and proposed criteria of success. *Int J Oral Maxillofac Implants* 1986;1:11-25.
  16. Atieh MA, Alsabeeha NH, Duncan WJ, de Silva RK, Cullinan MP, Schwass D, *et al.* Immediate single implant restorations in mandibular molar extraction sockets: A controlled clinical trial. *Clin Oral Implants Res* 2013;24:484-96.
  17. Ketabi M, Deporter D, Atenafu EG. A systematic review of outcomes following immediate molar implant placement based on recently published studies. *Clin Implant Dent Relat Res* 2016;18:1084-94.
  18. Moy PK, Nishimura GH, Pozzi A, Danda AK. Single implants in dorsal areas – A systematic review. *Eur J Oral Implantol* 2016;9 Suppl 1:S163-72.
  19. Ragucci GM, Elnayef B, Criado-Cámara E, Del Amo FS, Hernández-Alfaro F. Immediate implant placement in molar extraction sockets: A systematic review and meta-analysis. *Int J Implant Dent* 2020;6:40.
  20. Urban T, Kostopoulos L, Wenzel A. Immediate implant placement in molar regions: A 12-month prospective, randomized follow-up study. *Clin Oral Implants Res* 2012;23:1389-97.
  21. Bettach R, Taschieri S, Mortellaro C, Del Fabbro M. Immediate implant placement into fresh extraction sites using single-drilling bur and two loading procedures: Follow-up results. *J Craniofac Surg* 2018;29:2135-42.
  22. Nicolau P, Guerra F, Reis R, Krafft T, Benz K, Jackowski J. 10-year outcomes with immediate and early loaded implants with a chemically modified SLA surface. *Quintessence Int* 2019;50:114-24.
  23. Levine RA, Katwal D, Lai PC, Bruce J, Scarfe WC, Bornstein MM. Early loading of posterior nonsubmerged titanium implants with a modified sandblasted and acid-etched surface: A prospective case series with up to 149 months of follow-up. *Int J Periodontics Restorative Dent* 2021;41:51-9.
  24. Ayobian M, Akhondi N, Montazeri M. Long-term results of immediate implantation in the maxillary molar area with simultaneous sinus floor elevation by the crestal approach and early loading protocol: A retrospective case series follow up study. *J Adv Periodontal Implant Dent* 2018;10:68-76.
  25. Barone A, Toti P, Piattelli A, Iezzi G, Derchi G, Covani U. Extraction socket healing in humans after ridge preservation techniques: Comparison between flapless and flapped procedures in a randomized clinical trial. *J Periodontol* 2014;85:14-23.
  26. Deporter D, Khoshkhounejad AA, Khoshkhounejad N, Ketabi M. A new classification of peri implant gaps based on gap location (A case series of 210 immediate implants). *Dent Res J (Isfahan)* 2021;18:29.
  27. Lee CT, Chiu TS, Chuang SK, Tarnow D, Stoupe J. Alterations of the bone dimension following immediate implant placement into extraction socket: Systematic review and meta-analysis. *J Clin Periodontol* 2014;41:914-26.
  28. Oskarsson M, Otsuki M, Welander M, Abrahamsson I. Peri-implant tissue healing at implants with different designs and placement protocols: An experimental study in dogs. *Clin Oral Implants Res* 2018;29:873-80.
  29. Sommer M, Zimmermann J, Grize L, Stübinger S. Marginal bone loss one year after implantation: A systematic review of different loading protocols. *Int J Oral Maxillofac Surg* 2020;49:121-34.
  30. Barndt P, Zhang H, Liu F. Immediate loading: From biology to biomechanics. Report of the Committee on Research in fixed Prosthodontics of the American Academy of fixed Prosthodontics. *J Prosthet Dent* 2015;113:96-107.
  31. Wazen RM, Currey JA, Guo H, Brunski JB, Helms JA, Nanci A. Micromotion-induced strain fields influence early stages of repair at bone-implant interfaces. *Acta Biomater* 2013;9:6663-74.