

Comparison of Conventional and Standardized Bone Densitometry around Implants in Periapical Radiographs during a Three Months Period

Asieh Zamani Naser¹, Shahab Etemadi², Mansour Rismanchian³, Mahnaz Sheikhi¹,
Mohammadbagher Tavakoli⁴

ABSTRACT

Background: Comparing continuous films taken at different timescales is a way to study the alveolar bone changes around the implant over time. One of the important concerns in quantitative analysis of the alveolar bone changes over the time is to reduce variations in the X-ray imaging geometry and image density.

Methods: Using a modified XCP film holder together with the bite recording material, parallel periapical radiographs were taken from the implants placements of 16 patients in four steps. Densities of radiographs were measured in a conventional way using the video densitometry device. The same films were also scanned; sequential radiographic density of each patient was homogenised and the density was measured. Density changes obtained in both methods were compared. The data were evaluated using ANOVA, paired t-test and Pearson correlation ($\alpha = 0.05$).

Results: In the conventional method of densitometry, the average densities were as follows: before operation 1.0044, after one week 0.9600, after one month 0.9469 and after three months 0.9398. Also, in the standard method of densitometry, the average densities were as follows: before operation 111.7013, after one week 113.4225, after one month 119.4075 and after three months 131.1162. Average density in conventional densitometry were not significantly different in various time stages ($P = 0.395$). But, the standard densitometry method showed a significant difference ($P = 0.001$).

Conclusion: The average density obtained at different stages in the standard densitometry showed a gradual increase in the bone density in the entire process. Standardising the patient's consecutive radiographic images is essential for quantitative measurements over the time.

Keywords: Densitometry, Dental implants, Radiography.

Received: May 2010

Accepted: October 2010

Dent Res J 2011; 8(1): 33-38

Introduction

Increasing the number of dental implants in edentulous patients is accompanied by the need for careful evaluation of the tissues around the implants.^{1,2} Quality and quantity of the bone are two important and effective factors on stabilising the level connection of the implant and bone.³⁻⁸ In fact, enough bone volume and density are the key factors to successful implant treatment.^{9,10}

Most studies are concentrated on bone volume reconstruction, while only limited studies have con-

sidered bone density improvement in the implants area.^{11,12}

There are several methods to measure bone density, but use of some equipment is practically impossible.¹³ Routine radiography is used as a practical, reliable and non-invasive technique to evaluate the bone around the dental implants.^{14,15} Conventional intraoral radiography is mostly used to assess the bone in the implant's placement.¹⁶ This method is relatively low sensitive, but has overall high accu-

* This paper derived from a thesis and a research project No. 388580 in Isfahan University of Medical Sciences.

¹ Associate Professor, Department of Radiology and Torabinejad Dental Research Center, School of Dentistry, Isfahan University of Medical Sciences, Isfahan, Iran.

² Assistant Professor, Department of Radiology, Khorasgan Branch, Islamic Azad University, Isfahan, Iran.

³ Associate Professor, Department of Prosthodontics and Torabinejad Dental Research Center, School of Dentistry, Isfahan University of Medical Sciences, Isfahan, Iran.

⁴ Associate Professor, Department of Health Physic, Isfahan University of Medical Sciences, Isfahan, Iran.

Correspondence to: Asieh Zamani Naser, Email: Zamaninaser@dnt.mui.ac.ir

racy in detecting spongy bone lesions around implants; in other words, the bone lesions around the implants must reach a certain size to be detected, otherwise won't be evident.² On the other hand, various studies confirmed that the computer-assessed measurements of the bone around the implant on the intraoral digital images have complete accuracy and certainty.¹⁷

Assessing the bone quantity and quality during the treatment plan or the healing period is usually done by consecutive radiography.¹ Bone evaluation in every area before implant treatment is very important.¹⁸ One way to assess the changes in alveolar bone around the implant and tooth is to compare consecutive films taken at different stages of time.^{19,20} One of the important concerns in quantitative analysis of the alveolar bone changes over the time is to reduce variations in the X-ray imaging parameters or geometry and film density caused by exposure, processing conditions.²¹⁻²⁶ Irradiation geometry of consecutive films should be capable of reconstruction, otherwise they will not comply together and as a result the clinician may make a mistake.²⁷

In 2006, Bittar-Cortez and colleagues¹ did not find any significant difference in the bone density comparing two methods of hard tissue density changes around the implants in digital and conventional radiographies and subtraction digital images.

In this study, similar consecutive conventional periapical radiographs were taken from implant patients and the bone density around the implants were measured by ordinary densitometer (film densitometry) and once again after scanning and standardising, the optical density film was measured by computer software. Then, the two methods were compared.

Materials and Methods

In this prospective experimental-laboratory study, 16 healthy, non-smoker patients with good oral hygiene that were referred to Radiology Department of Isfahan Dental School in academic year 2009-2010 were selected. They needed periapical radiography for implant placement.

In order to prepare parallel radiographies, the XCP film holder (Rinn Co., USA) was used. XCP system does not provide repeatable or standard density. By adding a step wedge as a reference, density variations caused by exposure and processing conditions will be amendable. Aluminium step wedge is made of several steps with different thickness that

provide different density on radiographs as a reference, the atomic number of aluminium is similar to the effective atomic number of bone.²⁹ By making the similar density of step wedge with computer software on consecutive radiographs similar density is provided on the background of all films and we can measure the difference in density around the implant during bone healing. For using the density-standardizing aluminium step wedge by XCP film holder a metallic device was made from aluminium and it was placed on XCP film holder between its metallic arm and plastic film holder. This device consist of a density-standardizing aluminium step wedge on an aluminium base plate and a upper plate of aluminium with some guide slots created on its surface for further establishment of bite register material and this plate is connected to the base plate by two lateral walls and the empty space between upper and base plates prevent superimposition of the dentition over step wedge image when the patient bite on the impression bite register material. In this way constant radiographic geometry and standard densitometry of radiographs was possible (Figure 1). Also, to provide the same geometric condition for consecutive radiography, impression material is required to be able to repeat the film's position in the patient's mouth constantly.



Figure 1. XCP with built-wedge steps.

To record the bite, putty speedex (Coltene Co., Switzerland) was used, which was bitten by the patient to record a simple, versatile and retentive bite register. To control the infection, the whole system was placed in disposable plastic bag; also, bite register material was kept sterilised to be used for the same patient for next visit.

Using modified XCP and the standardised device together with the bite register material, parallel peri-

apical radiographs were taken from the selected patients in 4 stages: before operation, one week after implant placement, one month and three months later.

For all patients intraoral radiography was provided by Planmeca Intra unit (Planmeca Co., Finland), using appropriate exposure factors suitable for the patient. Exposures were considered identically for each patient at different times to create similar exposures for each patient at different time stages. All radiographs were prepared according to their dentist prescription. Periapical film No. 2 Dentus (Agfa Co., Belgium) with E-speed was used.

All exposed films were processed under standard conditions of the time and temperature by automatic processor HOPE Dental-max (Hoop Co.; USA) with processing solution (champion England).

Density of all films was ordinary measured by film densitometer RMI (X-Rite Co., America) with diameter holes at 1 mm by 5 mm. For standardization of density, the same films were scanned using Az-tek III scanner in a transparency state, with 600 dpi resolution without any changes in brightness and contrast and were saved in TIFF format. using CS Adobe Photoshop software consecutive radiographic density of each patient was matched according to the step wedge image, and then, the average density was measured by Digora for windows software in areas of 30×30 pixels. In both conventional and standard methods, average density in 5 areas around the im-

plant was measured: an apical region, two mesial and two distal regions. Then, the overall average density of the five areas was obtained for each radiograph. In both methods, the average density in consecutive radiographs of each patient was calculated. Next, the density differences obtained in both methods were compared. Finally, the data obtained were evaluated using SPSS software and ANOVA, paired t-test and Pearson correlation.

Results

Both conventional and standard densitometry was done on all 64 images obtained. 128 images were examined in total. Densitometry of each image was done in five areas and the overall average of the five measurement was considered for comparison.

The total density values at different time stages in conventional and standard methods are presented in Figures 2 and 3.

There were no significant differences in average density in different time stages in conventional densitometry ($P = 0.395$). But, the average density in standard densitometry showed a significant difference in different time stages ($P = 0.001$).

There were significant differences in standard densitometry between the densities at all stages: ($P < 0.05$).

At different stages of conventional and standard densitometry, the relationship between the two methods was not significant: ($P > 0.05$).

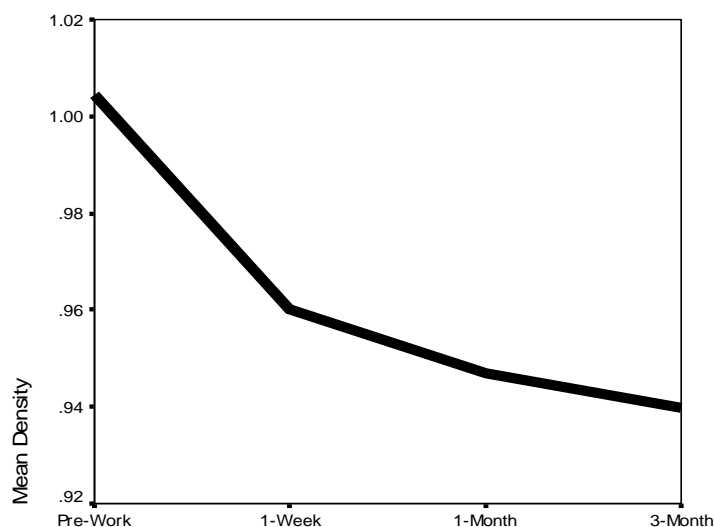


Figure 2. Average optical density in various time stages of conventional densitometry.

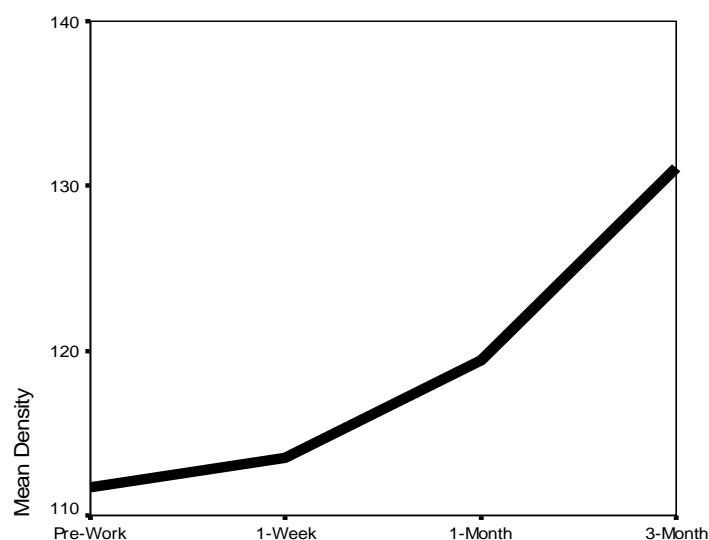


Figure 3. Average optical density in various time stages of standard densitometry.

Discussion

In the conventional densitometry that was done using the film densitometer device, the numbers are presented in a range between zero to four which is the logarithm of the input to output light intensity. Increasing this number is proportional to increasing the darkness of the film; therefore, this number is reduced by increased bone density (increased film brightness). Average density obtained at different time stages in the conventional densitometry showed a gradual reduction that could indicate increasing bone density around the implants but this difference was not reliable and statistically significant.

In the standard densitometry that was digitally done using computer software, the numbers are presented in a range from zero to 255 which increases in proportion to the increase in image brightness (increased bone density). Average density obtained at different time stages in this technique showed a gradual increase in bone density in the entire process which of course showed a statistically significant difference.

In addition, no significant relationship was found between the average densitometry values in different time stages of the conventional and standard densitometry. Therefore, the patient's ordinary consecutive film densitometry is not practical to examine the bone density changes over time. Although it was tried in this study to remove confounding fac-

tors as much as possible so that the exposure factors were fixed for each patient at different stages and in addition the same film and radiography system was used, small changes in the processing conditions had the ability to influence the image density and could affect the quantitative measurements over time.

Consequently, standardizing the patient's consecutive radiographic images is essential for quantitative measurements over time.

In Kavadella and colleagues² study in 2006, both conventional and digital image were responsive and even the overall accuracy of the conventional images were higher than the digital radiographs, which was probably due to being cross-sectional study that was not affected by the changing factors in image density over the time.

Although there were not the perspicuous expected changes in bone radiographic images before six months, in the radiographs taken a week after the implant placement, a slightly increased density was observed. Among other steps, this increase was the least, meaning from 111.70 to 113.47 which was the equivalent to 1.58% of increased density. Maximum density increase was between steps 3 and 4 namely between one month and three months after the implant placement from 119.41 to 131.12 which was the equivalent to 9.80% increased density.

Also, in Gulsahi and colleagues²⁸ study in 2007, the bone density increased six months after the implant placement. In this study, the technique of

standardising patient's consecutive radiographs was used.

In Bittar-Cortez and colleagues¹ study in 2006, a significant density difference was not achieved between bone density in one week and six months after the implant placement which could be the result of not standardizing the patient's consecutive radiographic image density; because practically, densitometry or subtraction of the images with different background density is not possible and brings up the wrong results.

Southard and colleagues¹⁴ proved the validity of the step wedge to measure bone density over time. Using this correction geometric and densitometric tool, they achieved substantial improvement in validity of the alveolar bone radiographic density measurements over time and like our study, they concluded that in the absence of such standardization, some of the radiographic bone density differences can't be easily detected due to small variations in exposure or X-ray film processing.

All these measurements were done before applying any force to implants, so it can be concluded that the implant placement could stimulate the bone-building process, in a way that from the beginning and even before applying any force to implant, the bone density starts to increase. Therefore, implants can have a positive role in maintaining the edentulous ridge and increasing its strength; probably, with the same mechanism that can maintain root ridges to protect the remaining ridge from resorption.

Conclusion

Standardised densitometry is more reliable than conventional densitometry for bone density measurement around implant in periapical radiography.

Acknowledgement

This article was prepared based on a thesis and a research project (# 388580) approved by the Medical Ethics and Research Office at the Isfahan University of Medical Sciences.

References

1. Bittar-Cortez JA, Passeri LA, Boscolo FN, Haiter-Neto F. Comparison of hard tissue density changes around implants assessed in digitized conventional radiographs and subtraction images. *Clin Oral Implants Res* 2006; 17(5): 560-4.
2. Kavadella A, Karayiannis A, Nicopoulou-Karayianni K. Detectability of experimental peri-implant cancellous bone lesions using conventional and direct digital radiography. *Aust Dent J* 2006; 51(2): 180-6.
3. Esposito M, Hirsch JM, Lekholm U, Thomsen P. Biological factors contributing to failures of osseointegrated oral implants. (I). Success criteria and epidemiology. *Eur J Oral Sci* 1998; 106(1): 527-51.
4. Friberg B, Jemt T, Lekholm U. Early failures in 4,641 consecutively placed Branemark dental implants: a study from stage 1 surgery to the connection of completed prostheses. *Int J Oral Maxillofac Implants* 1991; 6(2): 142-6.
5. Herrmann I, Lekholm U, Holm S, Kultje C. Evaluation of patient and implant characteristics as potential prognostic factors for oral implant failures. *Int J Oral Maxillofac Implants* 2005; 20(2): 220-30.
6. Jaffin RA, Berman CL. The excessive loss of Branemark fixtures in type IV bone: a 5-year analysis. *J Periodontol* 1991; 62(1): 2-4.
7. Jemt T, Lekholm U. Implant treatment in edentulous maxillae: a 5-year follow-up report on patients with different degrees of jaw resorption. *Int J Oral Maxillofac Implants* 1995; 10(3): 303-11.
8. Shahlaie M, Gantes B, Schulz E, Riggs M, Crigger M. Bone density assessments of dental implant sites: 1. Quantitative computed tomography. *Int J Oral Maxillofac Implants* 2003; 18(2): 224-31.
9. Martinez H, Davarpanah M, Missika P, Celletti R, Lazzara R. Optimal implant stabilization in low density bone. *Clin Oral Implants Res* 2001; 12(5): 423-32.
10. Jaffin RA, Berman CL. The excessive loss of Branemark fixtures in type IV bone: a 5-year analysis. *J Periodontol* 1991; 62(1): 2-4.
11. Buchter A, Kleinheinz J, Wiesmann HP, Kersken J, Nienkemper M, Weyhrother H, et al. Biological and biomechanical evaluation of bone remodelling and implant stability after using an osteotome technique. *Clin Oral Implants Res* 2005; 16(1): 1-8.
12. Nkenke E, Kloss F, Wiltfang J, Schultze-Mosgau S, Radespiel-Troger M, Loos K, et al. Histomorphometric and fluorescence microscopic analysis of bone remodelling after installation of implants using an osteotome technique. *Clin Oral Implants Res* 2002; 13(6): 595-602.
13. Jonasson G, Bankvall G, Kiliaridis S. Estimation of skeletal bone mineral density by means of the trabecular pattern of the alveolar bone, its interdental thickness, and the bone mass of the mandible. *Oral Surg Oral Med Oral Pathol Oral Radiol Endod* 2001; 92(3): 346-52.
14. Southard TE, Wunderle DM, Southard KA, Jakobsen JR. Geometric and densitometric standardization of intraoral radiography through use of a modified XCP system. *Oral Surg Oral Med Oral Pathol Oral Radiol Endod* 1999; 87(2): 253-7.

15. Frederiksen NL. Diagnostic imaging in dental implantology. *Oral Surg Oral Med Oral Pathol Oral Radiol Endod* 1995; 80(5): 540-54.
16. Nair MK, Ludlow JB, Tyndall DA, Platin E, Denton G. Periodontitis detection efficacy of film and digital images. *Oral Surg Oral Med Oral Pathol Oral Radiol Endod* 1998; 85(5): 608-12.
17. Wyatt CC, Bryant SR, Avivi-Arber L, Chaytor DV, Zarb GA. A computer-assisted measurement technique to assess bone proximal to oral implants on intraoral radiographs. *Clin Oral Implants Res* 2001; 12(3): 225-9.
18. de Oliveira RC, Leles CR, Normanha LM, Lindh C, Ribeiro-Rotta RF. Assessments of trabecular bone density at implant sites on CT images. *Oral Surg Oral Med Oral Pathol Oral Radiol Endod* 2008; 105(2): 231-8.
19. Hausmann E, Allen K, Carpio L, Christersson LA, Clerehugh V. Computerized methodology for detection of alveolar crestal bone loss from serial intraoral radiographs. *J Periodontol* 1992; 63(8): 657-62.
20. Nummikoski PV, Steffensen B, Hamilton K, Dove SB. Clinical validation of a new subtraction radiography technique for periodontal bone loss detection. *J Periodontol* 2000; 71(4): 598-605.
21. Lurie AG, Greenberg RJ, Kornman KS. Subtraction radiology demonstrates crestal bone loss in experimentally induced marginal periodontitis. *Oral Surg Oral Med Oral Pathol* 1983; 55(5): 537-41.
22. Payot P, Haroutunian B, Pochon Y, Herr P, Bickel M, Cimasoni G. Densitometric analysis of lower molar interradicular areas in superposable radiographs. *J Clin Periodontol* 1987; 14(1): 1-7.
23. Graf JM, Mounir A, Payot P, Cimasoni G. A simple paralleling instrument for superimposing radiographs of the molar regions. *Oral Surg Oral Med Oral Pathol* 1988; 66(4): 502-6.
24. Duckworth JE, Judy PF, Goodson JM, Socransky SS. A method for the geometric and densitometric standardization of intraoral radiographs. *J Periodontol* 1983; 54(7): 435-40.
25. Shrout MK, Hildebolt CF, Vannier MW. Alignment errors in bitewing radiographs using uncoupled positioning devices. *Dentomaxillofac Radiol* 1993; 22(1): 33-7.
26. Jeffcoat MK. Radiographic methods for the detection of progressive alveolar bone loss. *J Periodontol* 1992; 63(4 Suppl): 367-72.
27. Misch CE. *Contemporary implant dentistry*. 3rd ed. Louis: Mosby Elsevier; 2008.
28. Gulsahi A, Paksoy CS, Yazicioglu N, Arpak N, Kucuk NO, Terzioglu H. Assessment of bone density differences between conventional and bone-condensing techniques using dual energy x-ray absorptiometry and radiography. *Oral Surg Oral Med Oral Pathol Oral Radiol Endod* 2007; 104(5): 692-8.