

Case Report

Bilateral bifid mandibular canal

Mahnaz Sheikhi¹, Hamid Badrian¹, Sajad Ghorbanizadeh²

¹Torabinejad Research Center, Department of Oral and Maxillofacial Radiology, ²Dental Implant Research Center, School of Dentistry, Isfahan University of Medical Sciences, Isfahan, Iran

Received: April 2012
Accepted: July 2012

Address for correspondence:
Dr. Sajad Ghorbanizadeh,
Torabinejad Research Center
and Oral and Maxillofacial
Radiology Department,
School of Dentistry, Isfahan
University of Medical
Sciences, Isfahan, Iran.
E-mail:
sajadghorbanizadeh@gmail.
com

ABSTRACT

One of the normal interesting variations that we may encounter in the mandible is bifid mandibular canal. This condition can lead to difficulties when performing mandibular anesthesia or during extraction of lower third molar, placement of implants, and surgery in the mandible. Therefore diagnosis of this variation is sometimes very important and necessary.

Key Words: Bifid mandibular canal, cone beam computed tomography, inferior alveolar nerve, local anesthesia

INTRODUCTION

Histological studies have shown that the inferior alveolar nerve typically courses through the mandible as one major trunk with branches extending to apices of the teeth. However, there are multiple smaller branches of the inferior alveolar nerve (IAN) running roughly parallel to the major trunk. Occasionally these branches are large enough that they have a secondary mandibular canal. Such bifid canals are seen on panoramic and cone beam computed tomography (CBCT) images.^[1] Patients with bifid canals are at greater risk of inadequate anesthesia or difficulties with jaw surgery.^[2] Even trifid mandibular canal has been reported.^[3]

The major importance of location and configuration of mandibular canal variations is in the lower jaw surgeries, such as extraction of an impacted third molar, dental implant treatment, and sagittal split

ramus osteotomy.^[4] But the most common problem with this situation is inadequate anesthesia.^[5] There are many causes of failure of IAN blocks, including poor technique, anatomical variations, the presence of an acute infection, inability to enter the needle to the appropriate site or a reduced pain threshold.^[6]

This case study focuses on one example of an anatomical variation: Bifid mandibular canal (BMC). When we reviewed the literature regarding BMC, we encountered only a few case reports that had two mental foramina. The following case report describes a patient with bilateral BMCs with two mental foramina by using CBCT.

CASE REPORT

A 47-year-old man was referred to his clinicians with persistent dull pain, 1 year after retrograde root canal treatment of tooth#24. A CBCT radiograph was prescribed by his endodontic. Bifid mandibular canal with different patterns were located in each side of the jaw. While two mandibular canals with two distinct mandibular nerves ended to two different mental foramina in the left side [Figure 1], in the right side the conjunction of two different mandibular canals ended to an isolated mental foramen [Figure 2].

Access this article online



Website: www.drj.ir

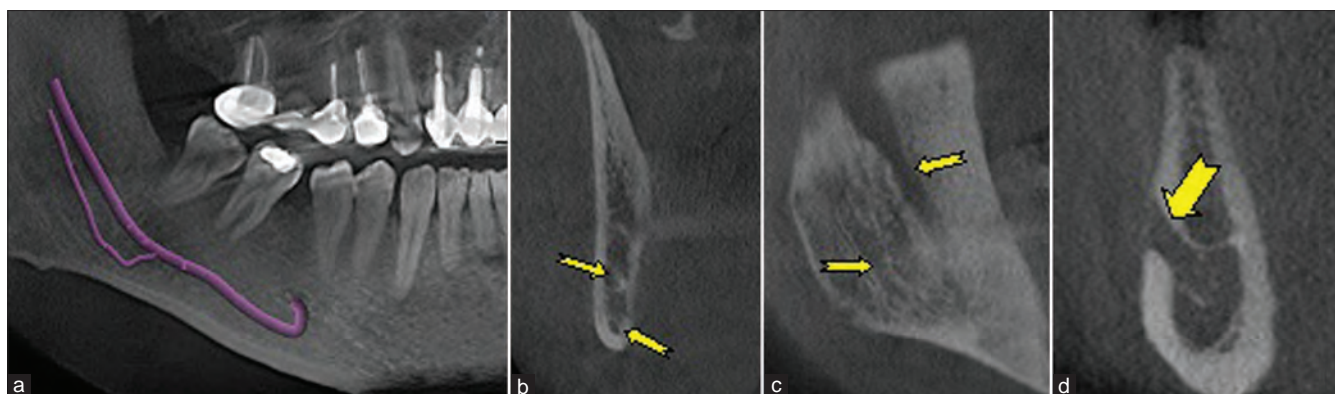


Figure 1: CBCT images of right mandibular canal, a: panoramic view, b: coronal view, c: sagittal-oblique view, d: cross-sectional view. In the right side, the mandibular canal ended to two mandibular foramens and only one mental foramen

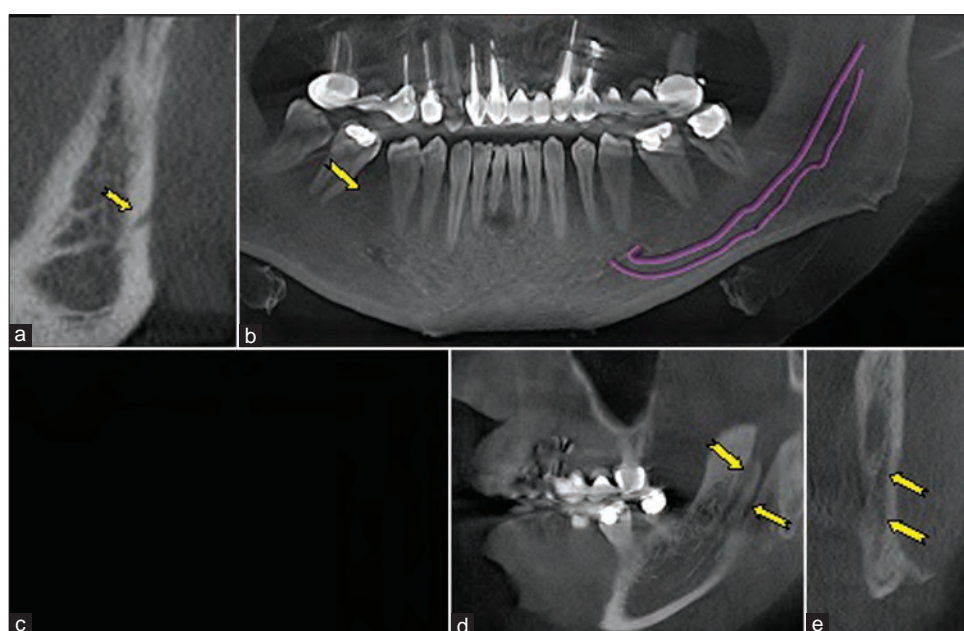


Figure 2: CBCT images of left mandibular canal, a, b: cross-sectional image, c: panoramic view, d: lateral sagittal, e: coronal view. In the left side, two mandibular canals including two mandibular nerves opened to two mental foramens

DISCUSSION

There are numerous reports for prevalence of bifid mandibular canal. The occurrence of bifid mandibular canal has been reported to be 0.35% by Sanchis *et al.*,^[7] 0.8% by Grover,^[8] 0.9% by Nortje *et al.*,^[9] and 0.95% by Langlais *et al.*^[10] Klinge *et al.* reported that mandibular canal of specimen cadavers is not visible in 36.1% of panoramic radiographs.^[11] Also, Lindh *et al.* reported that the mandibular canal of specimen cadavers is clearly visible in almost 25% of panoramic radiographs.^[12] Thus it was considered that there was a limitation in the observation of the mandibular canal by means of panoramic radiography. Nowadays by the

accurate new diagnostic equipments such as CBCT, this statistics may increase.^[1] Lee *et al.* reported four cases of BMC by using CBCT images that only two of them can be detected by panoramic radiography.^[13] CBCT has enabled dentists to visualize the anatomy of the mandibular canal and ramified canals better than past.^[14-16] According to these finding and our observation, we suggest that CBCT is more useful than conventional radiography such as panoramic images in detection of BMC.

IAN has been classified according to anatomical location and configurations. Nortjé *et al.* reported that there were three main variants of mandibular canal

division.^[9] Langlais *et al.* classified variations to four different patterns. The first included BMCs extending to the area surrounding the third molar or to the tooth itself; the second included BMCs arising from the same foramen but forming two separate canals which rejoined to form a single canal anteriorly; the third type included a combination of the first two types; and the last type included two radiographically separate canals with separate origins that eventually fused into a single canal anteriorly.^[10] The present case might be appropriate for type IV classification by Langlais. Nevertheless, the fact that, as opposed to the upper canals, the duplicate canals on the left side extended into different mental foramen allows us to consider this case as a new division. It is believed that one of the reasons that previous studies could not identify this type was using conventional radiographies and subsequently failing in detection narrow second mental foramen.

When should bifid canal be suspected? How should dental approaches be considered to efficient anesthesia?

The most common and first complication of bifid canal may appear in performing mandibular nerve block.^[5,17] Inadequate anesthesia may happen in bifid mandibular canal. The responsible nerve maybe long buccal or accessory IAN.^[18] Conventionally, anesthesia of the ipsilateral lip, chin, and teeth is indicative of an effective IANB. If a patient experiences only soft tissue anesthesia around the injection site, but not of the ipsilateral lip or chin, then a problem with local anesthesia technique is likely to be the cause of the failure. However, if there is soft tissue anesthesia of the lips and chin but not the teeth, one should consider anatomical variation.^[19]

When dentists encounter this situation, if their problem is only inadequate anesthesia they should use another technique for local anesthesia. But if the surgical process must be done in this region, the anatomical variation of IAN must be evaluated with diagnostic images. The best diagnostic imaging modality is CBCT that has considerable benefits, such as low dose, appropriate cost, and well visual quality.

CONCLUSION

Bifid mandibular canal may exist in each patient. To manage this anatomic variation, dentists should

choose appropriate images and local anesthesia technique.

ACKNOWLEDGEMENT

We would like to express our sincere acknowledgement in the support and help of the implant Research Center of Isfahan Dental School (Isfahan, Iran).

REFERENCES

1. Dalili Z, Mahjoub P, Sigaroudi AK. Comparison between cone beam computed tomography and panoramic radiography in the assessment of the relationship between the mandibular canal and impacted class C mandibular third molars. *Dent Res J* 2011;8:203.
2. White SC, Pharoah MJ. *Oral Radiology: Principles and Interpretation*. Mosby: Elsevier; 2009.
3. Auluck A, Ahsan A, Pai K, Shetty C. Anatomical variations in developing mandibular nerve canal: A report of three cases. *Neuroanatomy* 2005;4:28-30.
4. Naitoh M, Hiraiwa Y, Aimiya H, Gotoh M, Ariji Y, Izumi M, *et al.* Bifid mandibular canal in Japanese. *Implant Dent* 2007;16:24.
5. Lew K, Townsend G. Failure to obtain adequate anaesthesia associated with a bifid mandibular canal: A case report. *Aust Dent J* 2006;51:86-90.
6. Meechan JG, Robb ND, Seymour RA. *Pain and anxiety control for the conscious dental patient*: Oxford, England: Oxford University Press; 1998.
7. Sanchis J, Soler F. Bifid mandibular canal. *J Oral Maxillofac Surg* 2003;61:422-4.
8. Grover P, Lorton L. Bifid mandibular nerve as a possible cause of inadequate anesthesia in the mandible. *J Oral Maxillofac Surg* 1983;41:177-9.
9. Nortje C, Farman A, Grotepass F. Variations in the normal anatomy of the inferior dental (mandibular) canal: A retrospective study of panoramic radiographs from 3612 routine dental patients. *British Journal of Oral Surgery* 1977;15:55-63.
10. Langlais R, Broadus R, Glass B. Bifid mandibular canals in panoramic radiographs. *J Am Dent Assoc* 1985;110:923-6.
11. Klinge B, Petersson A, Maly P. Location of the mandibular canal: Comparison of macroscopic findings, conventional radiography, and computed tomography. *Int J Oral Maxillofac Implants* 1989;4:327.
12. Lindh C, Petersson A, Klinge B. Visualisation of the mandibular canal by different radiographic techniques. *Clin Oral Implants Res* 1992;3:90-7.
13. Lee JS, Yoon SJ, Kang BC. Mandibular canal branches supplying the mandibular third molar observed on cone beam computed tomographic images: Reports of four cases. *Radiology* 2009;39:209-12.
14. Naitoh M, Hiraiwa Y, Aimiya H, Ariji E. Observation of bifid mandibular canal using cone-beam computerized tomography. *Int J Oral Maxillofac Implants* 2009;24:155.
15. Claeys V, Wackens G. Bifid mandibular canal: Literature review and case report. *Dentomaxillofac Radiol* 2005;34:55.

16. Rouas P, Nancy J, Bar D. Identification of double mandibular canals: Literature review and three case reports with CT scans and cone beam CT. *Dentomaxillofac Radiol* 2007;36:34.
17. Haghighat A, Kaviani N, Panahi R. Hemodynamic effects of 2% lidocaine with 1: 80000 epinephrine in inferior alveolar nerve block. *Dent Res J* 2008;3:4-7.
18. Loizeaux A, Devos B. Inferior alveolar nerve anomaly. *J Hawaii Dent Assoc* 1981;12:10.
19. Malamed SF. *Handbook of local anaesthesia*. St Louis: Mosby; 2004. p. 208-9.

How to cite this article: Sheikhi M, Badrian H, Ghorbanizadeh S. Bilateral bifid mandibular canal. *Dent Res J* 2012;9:S132-5.

Source of Support: Nil., **Conflict of Interest:** The authors declare no conflicts of interest, real or perceived, financial or nonfinancial..