

Original Article

Analysis of linear measurement accuracy obtained by cone beam computed tomography (CBCT-NewTom VG)

Mahkameh Moshfeghi¹, Mohammad Amin Tavakoli¹, EhsanTavakoli Hosseini², Ali Tavakoli Hosseini³, Iman Tavakoli Hosseini⁴

¹Department of Oral and Maxillofacial Radiology, Shahid Beheshti University of Medical Sciences, ⁴Department of Oral and Maxillofacial Surgery, Tehran University of Medical Sciences, Tehran, ²Departments of Oral and Maxillofacial Radiology, ³Oral Pathology, Shahid Sadoghi University of Medical Sciences, Yazd, Iran

ABSTRACT

Background: One of the major uses of cone beam computed tomography (CBCT) is presurgical implant planning. Linear measurement is used for the determination of the quantity of alveolar bone (height and width). Linear measurements are used in orthodontic analysis and definition of jaw tumor size. The objective of this study is to evaluate the accuracy of the linear measurement of CBCT (Newtom VG) in the axial and coronal planes, with two different voxel sizes.

Materials and Methods: In this accuracy diagnostic study, 22 anatomic landmarks in four dry human skulls were marked by gutta-percha. Fifteen linear measurements were obtained using a digital caliper. These were considered to be the gold standard (real measurement). The skulls were scanned by CBCT (Newtom VG) at two settings: (a) Voxel size 0.3 mm (b) voxel size 0.15 mm High Resolution (HR). The radiographic distance measurements were made in the axial and coronal sections by three observers. The radiographic measurements were repeated two weeks later for evaluation of intraobserver reliability. SPSS software version 17 was used for data analysis. The level of significance was considered to be 5% ($P \leq 0.05$).

Results: The mean differences of real and radiographic measurements were -0.10 ± 0.99 mm in the axial sections, -0.27 ± 1.07 mm in the coronal sections, $+0.14 \pm 1.44$ mm in the axial (HR) sections, and 0.02 ± 1.4 mm in the coronal (HR) sections. The intraclass correlation (ICC) for CBCT measurements in the axial sections was 0.9944, coronal sections 0.9941, axial (HR) sections 0.9935, and coronal (HR) sections 0.9937. The statistical analysis showed high interobserver and intraobserver reliability ($P \leq 0.05$).

Conclusion: CBCT (Newtom VG) is highly accurate and reproducible in linear measurements in the axial and coronal image planes and in different areas of the maxillofacial region. According to the findings of the present study, a CBCT scan with a larger voxel size (0.3 mm in comparison to 0.15 mm) is recommended when the purpose of the CBCT scan is to measure linear distances. This will result in lower patient radiation dose and faster scan time.

Key Words: Cone-beam computed tomography, implant, measurement, skull

Received: May 2012

Accepted: August 2012

Address for correspondence:

Dr. Ehsan Tavakoli Hosseini,
Shahid Sadoghi University of
Medical Sciences,
Yazd, Iran.

E-mail: ehsantavakolihosseini@gmail.com

INTRODUCTION

The introduction of cone beam computed tomography

(CBCT) dedicated to maxillofacial imaging introduces an innovation in maxillofacial imaging. Due to rapid volumetric image acquisition (as low as 18 seconds) from a single low radiation dose scan of the patient and the low mA, the effective dose with the CBCT technique is significantly lower than that achieved with other CT imaging methods. CBCT provides multiple planar images of both jaws by a single rotational scan.^[1-4]

Applications of CBCT in maxillofacial imaging are

Access this article online



Website: www.drj.ir

increasing. Currently CBCT is commonly used for a variety of purposes in dentomaxillofacial imaging, implantology, periodontics, temporomandibular joint (TMJ) pathology, airway analysis, bone pathology, and endodontics.^[5-9]

Cone Beam Computed Tomography can provide submillimeter spatial resolution for images of the craniofacial complex, with scanning time comparable to panoramic radiography. The cone-beam technique uses rotational scanning of an X-ray source, reciprocating an X-ray detector around the patient head. CT/CBCT images are displayed as a matrix of individual blocks called voxels (volume element). CBCT can perform imaging of maxillofacial structures with different voxel sizes. The voxel size in CBCT may be as low as 0.125 mm, smaller than that achieved with conventional CT units. Smaller voxel size provides better image resolution and requires higher radiation dose. The voxel in CBCT is isotropic (uniform in all directions). Isotropic voxels in CBCT enable maintenance of the image quality in all three orthogonal planes (axial, sagittal, and coronal). Several CBCT systems are commercially available.^[10-12] CBCT software provide tools to measure distances, angles, zoom, invert the gray scale, adjust contrast, and gamma changes.^[13] One of the major uses of CBCT is presurgical implant planning. Linear measurement is used often in presurgical implant planning for determination of the exact amount of alveolar bone (height and width) and consequently size of the dental implants. Also linear measurements are used in orthodontic analysis and definition of jaw tumor size. Studies show that 94% of the CBCT measurements have been accurate, within 1 mm.^[14-16] The objective of this study is to evaluate the accuracy of the linear measurement of CBCT (Newtom VG) in axial and coronal planes with two voxel sizes: 0.15 mm and 0.3 mm.

MATERIALS AND METHODS

Four dry skulls, which were not identified by gender, age, or ethnicity, were used in this study. Fifteen linear distances were used for linear measurement accuracy between 22 anatomic landmarks [Table 1]. The landmarks were marked by 2 mm diameter round gutta-percha fixed to the skull, using heat. The linear distances were selected horizontally to account for linear measurements in the axial and coronal sections. The gold standard for each linear measurement was obtained by physical measurement, using a digital caliper (Mitutoyo Corp. Kawasaki, Japan) with the

accuracy of 0.01 mm. The physical measurements were repeated twice by an observer. The mean was considered as the gold standard or real measurement.

The radiographic scans were obtained using CBCT Newtom VG (Quantitative Radiology, Verona, Italy). The skull was then centered and fixed in the CBCT system. The skulls were positioned according to the recommendations of the CBCT manufacturer. The midline laser beam of the CBCT system was adjusted to the midsagittal plane of the skull. The horizontal laser beam was parallel to the Frankfort line of the skull. Each skull was scanned twice:

1. Full scan: Voxel size 0.3 mm (5.56 mAs, 110 kVp) and an 18-second scan time.
2. High resolution scan: Voxel size 0.15 mm (8.3 mAs, 110 kVp) and a 36-second scan time.

The raw data were reconstructed using the CBCT software (QRNNT V 2.21 Quantitative Radiology). Image reconstructions were made in the axial and coronal image planes. Radiographic measurements were made by three trained observers, with no knowledge of the real measurements, in the axial and coronal image planes using a measuring tool of the NNT software [Figure 1]. The images were viewed in a dimly lit room, on a 19-inch LG flatron monitor (LG, Seoul, Korea), with a screen resolution of 1440 × 900 pixels and a 32-bit depth color. Observers were free to choose the tools of the CBCT software, including brightness, contrast, and gamma changes, with no time limitation. In total, 120 radiographic measurements were performed by each observer. The radiographic measurements were repeated two weeks later for evaluation of intraobserver reliability. The radiographic measurements were recorded in

Table 1: Anatomical landmarks used as references for measurements

Mental foramen right (R) to mental foramen left (L)
Mandibular foramen (R) to mandibular foramen (L)
Lateral pterygoid plate (R) to lateral pterygoid plate (L)
Medial pterygoid plate (R) to medial pterygoid plate (L)
Medial and lateral pterygoid plate (R)
Medial and lateral pterygoid plate (L)
Occipital condyle (R) to occipital condyle (L)
Greater palatine foramen (R) to greater palatine foramen (L)
Infraorbital foramen (R) to infraorbital foramen (L)
Foramen oval (R) to foramen oval (L)
Foramen lacerum (R) to foramen lacerum (L)
Posterior clinoid process (R) to posterior clinoid process (L)
Anterior clinoid process (R) to anterior clinoid process (L)
Anterior and posterior clinoid process (R)
Anterior and posterior clinoid process (L)

comparison with the real measurements, with a negative number indicating underestimation and a positive number indicating overestimation.

Statistical analysis

The SPSS software version 17 was used for data analysis. The mean of all radiographic measurements for each image sequence was calculated. The intraclass correlation coefficient was used to determine the accuracy of the radiographic measurements and also interobserver and intraobserver reliability. The level of significance was considered to be 5% ($P \leq 0.05$).

RESULTS

The mean difference and standard deviation of the radiographic measurements of each image plane from the gold standard are summarized in Table 2.

The mean of all the radiographic measurements was smaller than that of the real measurements, except for the axial high resolution. The mean difference of the radiographic measurements from that of the real measurements ranged from -0.2781 to 0.1418, and the standard deviation ranged from 0.991 to 1.441. No statistically significant difference was found between the radiographic measurements and real measurements (P value > 0.05).

The ICC of each image plane comparing the radiographic measurements and real measurements in the first reading is given in Figure 2. The ICC ranged from 0.9935 to 0.9944, showing that the radiographic measurements were accurate (P value > 0.05). Regarding the statistical analysis, no statistically significant difference was seen for both interobserver and intraobserver reliability. The ICC for interobserver reliability varied from 0.9991 to 0.9996 and for intraobserver reliability it varied from 0.9849 to 0.9998 [Tables 3 and 4]. The ICC for each individual landmark is given in Table 5. The ICC for each individual landmark ranged from 0.7407 to 0.9996, showing no statistically significant difference between the radiographic measurements and real measurements in each landmark (P value > 0.05). The plotting of radiographic measurements against the gold standard is given in Figure 3.

DISCUSSION

CBCT provides a valuable tool for evaluating craniofacial region. Effective radiation dose from a

scan of maxillofacial volume is significantly lower than medical CT and is in the range of conventional dental radiographies.^[14] The CBCT software provides some useful tools for clinical practice, such as, tools to measure distances and angles, to zoom, invert the gray

Table 2: Mean difference and standard deviation of radiographic and real measurements

Reconstruction plane	Mean diff* (mm)	SD diff* (mm)
Axial	-0.1076	0.991
Coronal	-0.2781	1.079
Axial H*	0.1418	1.441
Coronal H*	-0.0223	1.402

H*: High resolution, Diff*: Difference

Table 3: Interobserver correlation for first reading

Image plane	ICC
Axial	*0.9996
Coronal	*0.9995
Axial H	*0.9991
Coronal H	*0.9992

ICC: Intraclass correlation

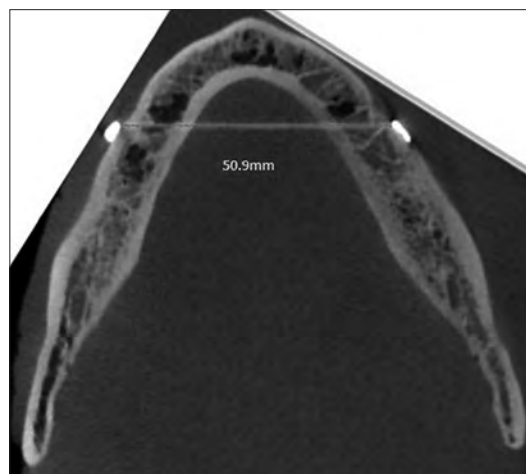


Figure 1: Linear measurement between right and left mental foramen obtained by CBCT in axial plane

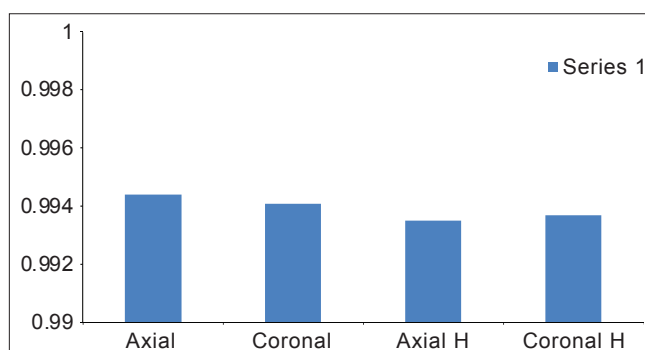


Figure 2: Intraclass correlation coefficient for first reading

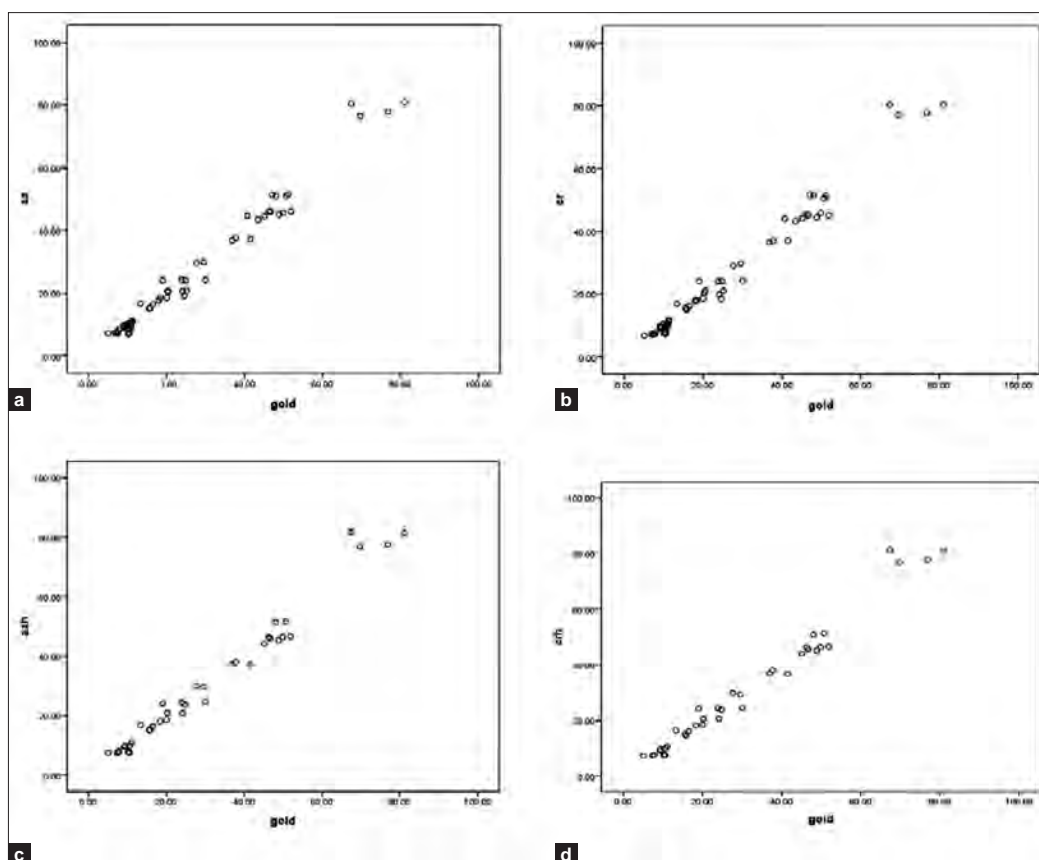


Figure 3: Scatter plot of radiographic measurements versus real measurements (gold standard): (a) Axial, (b) Coronal, (c) Axial H, (d) Coronal H

Table 4: Intraobserver reliability

Observer	Axial	Coronal	Axial H	Coronal H
Observer 1	0.9997	0.9998	0.9858	0.9854
Observer 2	0.9996	0.9997	0.9855	0.9849
Observer 3	0.9996	0.9998	0.9951	0.9861

Table 5: The intraclass correlation for each individual landmark

Anatomic landmark	Axial	Coronal	Axial H	Coronal H
1	0.9971	0.9985	0.9976	0.9987
2	0.9951	0.9946	0.9958	0.9969
3	0.9987	0.9990	0.9975	0.9971
4	0.9971	0.9969	0.9978	0.9981
5	0.8580	0.8241	0.8812	0.9015
6	0.9791	0.9828	0.9714	0.9806
7	0.9655	0.9719	0.9751	0.9809
8	0.9991	0.9995	0.9994	0.9996
9	0.7508	0.7347	0.7653	0.7844
10	0.9718	0.9815	0.9663	0.9783
11	0.9813	0.9977	0.9927	0.9981
12	0.7518	0.7407	0.7516	0.7808
13	0.9931	0.9927	0.9948	0.9951
14	0.9881	0.9825	0.9699	0.9782
15	0.9785	0.9730	0.9850	0.9881

scale, adjust the contrast, and gamma changes.^[13-15] One of the major uses of CBCT is presurgical implant planning. The linear measurement of distances is often used in presurgical implant planning for the determination of the exact amount of alveolar bone (height and width) and consequently the size of the dental implants. Also, linear measurements are used in orthodontic analysis and in the definition of jaw tumor size. The image data is acquired from a single 360 rotation scan around the patient.^[17] Image reconstruction provides multiplanar images. The purpose of this study was to analyze the accuracy of linear measurements made in images obtained by CBCT in different image planes and different areas of the field of view (FOV), in different voxel sizes.

In this study, anatomic landmarks were chosen in different areas of the skull, to check the accuracy of CBCT linear measurements in different areas of FOV. An analysis of the measurements showed that the CBCT measurements were highly accurate and reproducible. The mean differences between the radiographic measurements and real measurements varied from - 0.2781 mm for the coronal

images (voxel size 0.3 mm) to 0.1418 mm for the axial high resolution images (voxel size 0.15 mm). The mean of differences was less than 0.5 mm in all measured image planes. This showed that CBCT provided a valuable measuring tool in different areas of FOV.

The linear measurement accuracy of CBCT was tested in various units. Fatemitabar *et al.* evaluated the accuracy of CBCT (planmeca), and found the mean differences varying from 0.37 mm to 0.58 mm for CBCT, and from 0.37 mm to 0.72 mm for a 64-channel CT (Siemens).^[12] Pinsky *et al.* found that CBCT (i-CAT) could be an accurate diagnostic tool for small osseous defects. They found mean differences varying from - 0.01 mm to 0.27 mm for width and height accuracy.^[13] Stratemann *et al.* also found high accuracy in the CBCT images for linear distances compared to the real measurements. The error was small for two evaluated CBCT systems varying from to 0.07 mm \pm 0.41 mm for NewTom 9000 and 0.00 \pm 0.22 mm for CB Hitachi MercuRay.^[14]

Lascala *et al.*, in a similarly designed study in which distances between 13 sites on human dry skull were measured using NewTom 9000 (Quantitative Radiology, Verona, Italy), found that the CBCT images underestimated the real distances between the skull sites, however, the differences between the CBCT and real measurements were only statistically significant for measurements of the skull base. In our study, the CBCT measurements were slightly underestimated (but not statistically significant) and the mean differences were negative, except for measurements in axial high resolution.^[16]

Interobserver reliability varied from 0.9991 to 0.9996. Intraobserver reliability varied from 0.9849 to 0.9998. This showed that CBCT measurements in the craniofacial area were highly reproducible. This was in agreement with the results of Kamburoglu *et al.*, who found the interobserver reliability to be 0.995 to 1 and intraobserver reliability to be 0.992 to 1. Oz *et al.* also found high interobserver reliability of the CBCT measurements in the craniofacial area.^[18]

Measurements were also performed in two different voxel sizes: (a) Voxel size 0.3 mm. (b) voxel size 0.15 mm High Resolution (HR). The effect of the voxel size did not seem to be an important factor in linear measurement accuracy, as no significant difference was found between the measurements made in images with a voxel size of 0.3 mm and

0.15 mm (P value $>$ 0.05). Stratemann *et al.* had the same results.^[14] Brown *et al.* found that reducing the number of image projections did not result in a higher accuracy of CBCT measurements.^[15] This was of clinical significance, as the patient radiation dose would be directly related to the voxel size and the number of projection images acquired. By reducing the number of image projections or increasing the voxel size, images with the same dimensional accuracy could be obtained. According to the findings of the present study, a CBCT scan with larger voxel size (0.3 mm in comparison to 0.15 mm) was recommended when the purpose of the CBCT scan was to measure linear distances, as in presurgical implant site evaluation and orthodontic analysis. This would result in a lower patient radiation dose and faster scan time. Faster scan time would decrease motion artifact due to patient movement.

Patcas *et al.* evaluated the accuracy of linear intraoral measurements using CBCT. The radiological measurements were accurate, with a mean difference from the anatomical measurements of 0.14 mm.^[19] Dalessandri *et al.*, in an *ex-vivo* study, evaluated measurement reliability using two different CBCT scanners for orthodontic purposes. They found both scanners reliable for linear measurements.^[20]

In the present study, we found no significant difference between the accuracy of CBCT measurements in the axial and coronal sections. This was expected because the voxels in CBCT were isotropic (equal in all three dimensions) and this would result in the same image quality in the three orthogonal image planes.

The accuracy of measurement distances on patients may be affected by a reduction in image quality due to soft tissue attenuation, restoration metallic artifacts, and patient movement. The skill of the operator in CBCT measurements and calibration of the hardware/software of the CBCT system are also effective in the accuracy of the CBCT measurements of the craniofacial area.

CONCLUSION

Cone beam computed tomography (Newtom VG) is highly accurate and reproducible in linear measurements in the axial and coronal image planes, and in different areas of the maxillofacial region. According to the findings of the present study, a CBCT scan with a larger voxel size (0.3 mm in comparison with 0.15 mm) is recommended when

the purpose of the scan is to measure linear distances. This will result in lower patient radiation dose and faster scan time. We recommend methods with a lower patient radiation dose and faster scan time.

REFERENCES

- Mozzo P, Procacci C, Tacconi A, Martini PT, Andreis IA. A new volumetric CT machine for dental imaging based on the cone-beam technique: Preliminary results. *Eur Radiol* 1998;8:1558-64.
- Sukovic P. Cone beam computed tomography in craniofacial imaging. *Orthod Craniofac Res* 2003;6:31-6.
- Tsikiakis K, Donta C, Gavala S, Karayianni K, Kamenopoulou V, Hourdakos CJ. Dose reduction in maxillofacial imaging using low dose Cone Beam CT. *Eur J Radiol* 2005;56:413-7.
- Ludlow JB, Davies-Ludlow LE, Brooks SL, Howerton WB. Dosimetry of 3 CBCT devices for oral and maxillofacial radiology: CB MercuRay, NewTom 3G and i-CAT. *Dentomaxillofac Radiol* 2006;35:219-26.
- Ziegler CM, Woertcher R, Brief J, Hassfeld S. Clinical indications for digital volume tomography in oral and maxillofacial surgery. *Dentomaxillofac Radiol* 2002;31:126-30.
- Guerrero ME, Jacobs R, Loubele M, Schutyser F, Suetens P, van Steenberghe D. State-of-the-art on cone beam CT imaging for preoperative planning of implant placement. *Clin Oral Invest* 2006;10:1-7.
- Kau CH, Richmond S, Palomo JM, Hans MG. Three-dimensional cone beam computerized tomography in orthodontics. *J Orthod* 2005;32:282-93.
- Yamamoto K, Ueno K, Seo K, Shinohara D. Development of dento-maxillofacial cone-beam x-ray computed tomography system. *Orthod Craniofac Res* 2003;6:160-2.
- Cavalcanti MG, Rocha SS, Vannier MW. Craniofacial measurements based on 3D-CT volume rendering: Implications for clinical applications. *Dentomaxillofac Radiol* 2004;33:170-6.
- Scarfe WC, Farman AG. What is cone-beam CT and how does it work? *Dent Clin North Am* 2008;52:707-30.
- Araki K, Maki K, Seki K, Sakamaki K, Harata Y, Sakaino R, *et al.* Characteristics of a newly developed dentomaxillofacial X-ray cone beam CT scanner (CB MercuRayTM): System configuration and physical properties. *Dentomaxillofac Radiol* 2004;33:51-9.
- Fatemitabar SA, Nikgoo A. Multichannel computed tomography versus cone-beam computed tomography: Linear accuracy of *in vitro* measurements of the maxilla for implant placement. *Int J Oral Maxillofac Implants* 2010;25:499-505.
- Pinsky HM, Dyda S, Pinsky RW, Misch KA, Sarment DP. Accuracy of three-dimensional measurements using cone-beamCT. *Dentomaxillofac Radiol* 2006;35:410-6.
- Stratemann SA, Huang JC, Maki K, Miller AJ, Hatcher DC. Comparison of cone beam computed tomography imaging with physical measures. *Dentomaxillofac Radiol* 2008;37:80-93.
- Brown AA, Scarfe WC, Scheetz JP, Silveira AM, Farman AG. Linear accuracy of cone-beam CT derived 3D images. *Angle Orthod* 2009;79:150-7.
- Lascala CA, Panella J, Marques MM. Analysis of the accuracy of linear measurements obtained by cone beam computed tomography (CBCT-NewTom). *Dentomaxillofac Radiol* 2004;33:291-4.
- Suomalainen A, Vehmas T, Kortensniemi M, Robinson S, Peltola J. Accuracy of linear measurements using dental cone beam and conventional multislice computed tomography. *Dentomaxillofac Radiol* 2008;37:10-7.
- Oz U, Orhan K, Abe N. Comparison of linear and angular measurements using two-dimensional conventional methods and three-dimensional cone beam CT images reconstructed from a volumetric rendering program *in vivo*. *Dentomaxillofac Radiol* 2011;40:492-500.
- Patcas R, Markic G, Muller L, Ullrich O, Peltomaki T, Kellenberger CJ. Accuracy of linear intraoral measurements using cone beam CT and multidetector CT: A tale of two CTs. *Dentomaxillofac Radiol* 2012
- Dalessandri D, Bracco P, Paganelli C, Hernandez Soler V, Martin C. *Ex vivo* measurement reliability using two different CBCT scanners for orthodontic purposes. *Int J Med Robot* 2012;8:230-42.

How to cite this article: Moshfeghi M, Tavakoli MA, Hosseini E, Hosseini AT, Hosseini IT. Analysis of linear measurement accuracy obtained by cone beam computed tomography (CBCT-NewTom VG). *Dent Res J* 2012;9:S57-62.

Source of Support: Nil. **Conflict of Interest:** None declared.